Clinical Neurophysiology Practice 7 (2022) 129–134

Contents lists available at ScienceDirect

Clinical Neurophysiology Practice

journal homepage: www.elsevier.com/locate/cnp

Case report

Localization of macroscopically undetectable intramedullary hematoma by intraoperative epidural motor evoked potential

Zoltán Horváth [a,b,*], Melinda Lukács [a,b], László Szívos [a], Pál Barzó [a]

[a] Department of Neurosurgery, University of Szeged, Hungary
[b] Department of Neurology, University of Szeged, Hungary

ARTICLE INFO

Article history:
Received 14 January 2022
Received in revised form 7 April 2022
Accepted 14 April 2022
Available online 22 April 2022

Keywords:
Intramedullary hematoma
Intraoperative neurophysiological monitoring
Epidural motor evoked potential
D wave

ABSTRACT

Introduction: Intramedullary hematoma is an uncommon, serious neurological disease, representing a diagnostic challenge. The preferred treatment is surgical. In most of the cases the lesion can be identified macroscopically. Otherwise, finding the optimal place to perform myelotomy is demanding. Intraoperative neurophysiological monitoring plays an important role in preventing surgical complications, but its versatility for localization has not been studied so far.

Case report: The present case report describes a 17-year-old patient with flaccid right inferior monoparesis (later paraparesis), ipsilateral loss of proprioception and vibration sense, contralateral analgesia below the T10 dermatome level and urinary retention (Brown-Séquard syndrome). The MRI revealed an intramedullary hematoma at the level of T8-T9 vertebral bodies. Digital subtraction angiography did not identify any vascular malformation. Urgent surgical intervention was performed. In order to prevent any complication somatosensory-evoked potential (SSEP), transcranial and epidural motor-evoked potential (tcMEP, eMEP) recordings were planned. SSEP in response to right tibial nerve stimulation and tcMEP were absent bilaterally. From electrophysiological point of view, the eMEP revealed a total conduction block of the corticospinal tract. In the absence of typical macroscopic signs (discoloration, swelling, abnormal vascularization etc.), the small intramedullary hematoma could not be identified. Therefore, it was decided to adopt eMEP technique for mapping and localizing the conduction block intraoperatively by changing the distance between the two electrodes used for recording. The hematoma was precisely localized and successfully evacuated. Postoperatively, a slow but continuous improvement was noted.

Conclusion: Intraoperative neurophysiological monitoring has been suggested to play crucial role in spinal cord surgery. To our knowledge, this is the first case report using eMEP recording for guiding and localizing of an intramedullary hematoma. Beside the clear limitations of our study, it could result in a novel application of the aforementioned monitoring technique.

© 2022 International Federation of Clinical Neurophysiology. Published by Elsevier B.V. This is an open access article under the CC BY-NC-ND license (http://creativecommons.org/licenses/by-nc-nd/4.0/).

1. Introduction

Spinal hematoma is a rare and severe neurological condition, with multifactorial, often unrecognized aetiology. Among the triggering factors the third most common has proven to be vascular malformations, accounting for almost 10% of all cases (Kreppel et al., 2003; Leep Hunderfund and Wijdicks, 2009). The most prevalent type is epidural, followed by subdural hematoma, whereas intramedullary hematoma represents only 1% of spinal hematomas (Kreppel et al., 2002). Intramedullary hematomas remain a diagnostic challenge, but they need to be considered as an uncommon cause of myelopathy (Leep Hunderfund and Wijdicks, 2009). The preferred imaging modality should be MRI (Sheerin et al., 2009). Early diagnosis is crucial and the treatment of choice should be surgical (Kreppel et al., 2003; Groen, 2004).

In the majority of the cases the lesion is distinguishable macroscopically during the operation. Otherwise, finding the optimal place to perform myelotomy represents extreme challenge for the neurosurgeon. Due to anatomical features of the spinal cord, an error of up to a few millimetres might lead to serious residual symptoms.

In order to prevent devastating consequences of surgery, intraoperative neurophysiological monitoring (IONM) is recommended. IONM plays crucial role in identifying a reversible spinal cord damage, or in case of an irreversible injury, it can predict the postoperative motor deficit (Costa et al., 2013). The recording and monitoring of epidural motor evoked potential (eMEP) (D-wave)

* Corresponding author.
E-mail address: horvath.zoltan.1@med.u-szeged.hu (Z. Horváth).

https://doi.org/10.1016/j.cnp.2022.04.001
2467-981X/© 2022 International Federation of Clinical Neurophysiology. Published by Elsevier B.V.
This is an open access article under the CC BY-NC-ND license (http://creativecommons.org/licenses/by-nc-nd/4.0/).

combined with transcranial electric motor evoked potential (tcMEP) recordings are proposed by many studies of intramedullary spinal cord lesion surgery. However, the usefulness of intraoperative mapping of motor systems using eMEP electrodes in these types of spinal surgery have not yet been published.

In this report our aim is to show the usefulness of the eMEP technique in case of a macroscopically undetectable hematoma of the spinal cord.

2. Case report

2.1. History and examinations

A 17-year-old professional kayaker with no previous medical history presented with acute onset right leg weakness, left leg analgesia, low back pain and difficulty in urination. Patient did not take any medication before and denied alcohol intake or illicit drug use. Neurological examination on admission revealed right leg flaccid paresis, loss of proprioception and vibration sense. Loss of pain and temperature sensation on the left leg, hyporeflexia with no pathological reflexes and urinary retention were also found. Cranial nerves and upper extremities were spared. Due to lower motoneuron signs and low back pain started two weeks prior the incident, lumbar spine MRI was performed. MRI showed L4-L5 disc protrusion with S1 root compression, without any need for surgical intervention.

The next day the patient's condition worsened: sensory loss ascended up to the line of the umbilicus, the patient was unable to move the right leg and muscle weakness appeared also on the contralateral lower limb. Patient's pain persisted despite taking painkillers. Clinical examination revealed flaccid paraparesis, with plegia on the right lower limb, 3/5 paresis on the left lower limb, urinary retention and sensory disturbance below the level of T10 dermatome (Brown-Séquard syndrome progressed to transverse cord lesion). No symptoms were detected on the face or upper limbs. All these signs pointed towards a lesion causing thoracic myelopathy. MRI revealed a hypointense lesion of the spinal cord both on T1 and T2-weighted sequences at the level of the T8-T9 vertebral bodies, showing no contrast enhancement (Fig. 1). In the axial T2-weighted images, the lesion was seen intramedullary, situated mostly on the right ventral side of the spinal cord and also a small T2-hyperintense edge was detected cranially. The findings and the clinical manifestations were consistent with an intramedullary hematoma in chronic stage with minimal subacute component. No abnormality was found on the cervical and cerebral MRI. Following osmotic therapy with mannitol and corticosteroid, no improvement was seen. On the following day, digital subtraction angiography was performed, which did not identify any vascular malformation. On the same day, urgent surgical treatment was indicated.

2.2. Anaesthesia

Total intravenous anaesthesia was induced and maintained uneventfully. Propofol (plasma concentration 3–4 mg/ml) and rocuronium (50 mg), a short acting non-depolarizing muscle relaxant were used for inducing anaesthesia, and target-controlled infusions of propofol (plasma concentration 4–5 mg/ml) and remifentanil (0.05 mcg/kg/min) were used to maintain it. In addition to intraoperative EEG monitoring, bispectral index (BIS) monitors were used for determining the depth of anaesthesia. BIS value was maintained at 30–40 during the operation. A bite blocker was used after intubation to avoid lip and tongue bites. There were no significant changes in any vital parameter during the anaesthesia.

2.3. Intervention

Following the introduction of general anaesthesia the patient was placed in the prone position. The spinal level of T6-T10 was identified using intraoperative X-ray. Midline incision was performed down to the spinous processes, followed by dissection of the paraspinal musculature away from the lamina on both sides. T6, T10 arcotomy and T7, T8, T9 laminectomy were performed with a craniotome, allowing exposure of the dura, not presenting any sign of dural tension. An operative microscope was implemented and somatosensory evoked potentials (SSEP), tcMEP and eMEP were monitored. After midline dural incision, dural retention sutures were applied, exposing the underlying cord, which was found intact without exhibiting any macroscopic changes. However, close to left T9 and right T7 nerve roots, an arteriovenous fis-

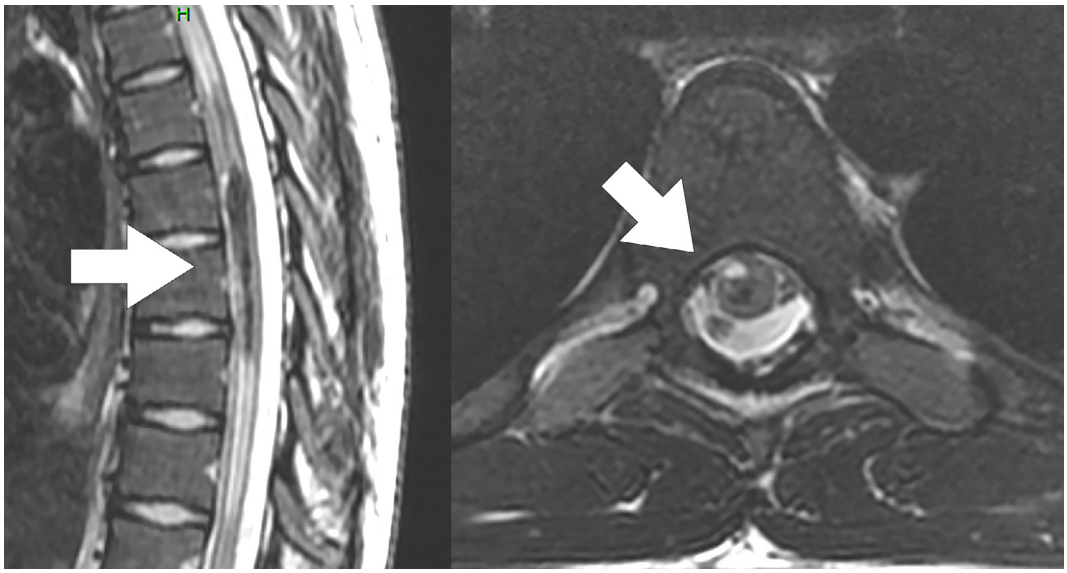

Fig. 1. MRI (T2 weighted image, sagittal and axial view). The arrow points towards the intramedullary hypointense lesion the level of the T8-T9 vertebral body. In the axial T2-weighted image the lesion was seen intramedullary, situated mostly on the right ventral side of the spinal cord and also a small T2-hyperintense edge was detected cranially.

tula was identified and coagulated at the epi- and intradural entry point. Next step was to evacuate the haematoma, but to ensure the adequate location of the haemorrhage, eMEP electrodes were used (see IONM section below). The spinal cord was twisted carefully with 30–40° and a 7–8 mm long incision was performed between the motor and sensory pathways. The hematoma was identified and was successfully evacuated using aspiration and continuous irrigation. Primarily dural closure was obtained, the plastron (T7–8–9 laminae) were replaced and fixated with mini plates and screws. The fascia above the Redon drain, the subcutaneous and cutaneous layers were closed in separate layers.

2.4. Intraoperative neurophysiological monitoring (IONM)

Medtronic NIM-Eclipse E4 system was used to perform IONM. Corkscrew scalp electrodes (Medtronic, DME1001) were placed at Fpz, Cpz, C3 and C4 for EEG and SSEP recordings, and at C'3 and C'4 for tcMEP stimulation, according to the International 10-10 system. To record SSEP responses, subcutaneous twisted pair needle electrodes (Medtronic, DSN2260, 13 mm, 27G) were placed over the left ulnar nerve at the wrist and both tibial nerves at the ankles. Nerves were stimulated at 24 and 80 mA (pulse duration: 300 μs, rate: 1.2 Hz). To record spontaneous EMG activities and tcMEP responses, intramuscular needle electrodes (Medtronic, DSN2260, 13 mm, 27G) were placed into the following muscles: first dorsal interosseous, vastus lateralis, tibialis anterior and abductor hallucis muscles with a belly-tendon montage. Train-of-four responses were measured by stimulating the ulnar and tibial nerves with recordings from the ipsilateral first dorsal interosseous and abductor hallucis muscles respectively. TcMEPs were elicited using a train of biphasic constant-voltage stimulation (up to 1000 V (maximal stimulus intensity), 7 pulses, pulse duration 75 μs, 500 Hz) using the C'3 and C'4 electrodes. eMEPs were elicited using single stimulus (intensity: 146 V, duration 500 μs, rate 1 Hz).

For eMEP recording, two flexible three-contact epidural electrodes (CEDL-3PIDINX, DID-MEDICAL/Ad-Tech Medical instruments corporation, Racine, WI, USA) were placed above and below the site of surgery.

The recording settings were configured based on American Clinical Neurophysiology Society guidelines for SSEP and tcMEP (Legatt et al., 2016). (For SSEP: bandpass 20–300 Hz, sweep time: 50 ms, number of averages 100–200; for tcMEP: bandpass 300–1500 Hz, timebase: 100 ms, number of averages: 1 (no average)).

The baseline of the IONM was recorded after the patient was set in the prone position. SSEP signal elicited from the right tibial nerve was absent, all other SSEP recording were found normal. The tcMEP responses were recordable over the upper extremity, but were lacking over the right lower extremity and only a small amplitude (50–60 μV) MEP response was detectable over the left tibialis anterior muscle, using maximal stimulus intensity. (Fig. 2). Consequently, we decided that only the SSEP from the left lower limb can be considered stable enough for IONM of the function of thoracic spinal cord during the operation.

The IONM recordings were constant during the initial steps of the operation (from incision to laminectomy) and were repeatedly verified every 5–8 min.

After laminectomy, two flexible three-contact epidural electrodes were placed by the surgeon above and below the site of incision to record eMEP. The position of the electrodes was defined using p1-p2-p3 contacts placed rostral (p-proximal), while d1-d2-d3 contacts set caudal (d-distal) to the lesion, were both p1 and d1 are on tip of the electrode. eMEP responses were detected only with the proximal electrode, distally they were absent, even changing the stimulation mode and electrode position. We concluded that, from electrophysiological point of view, a total conduction block of the corticospinal tract was revealed at the thoracic level.

With a stable SSEP over the left lower extremity and missing tcMEP and eMEP data, the accuracy of the IONM was thought to be questionable.

Due to the lack of typical macroscopic signs (discoloration, swelling, abnormal vascularization etc.), the small intramedullary hematoma could not be identified.

This led to the decision of using eMEP technique for intraoperative mapping. Our purpose was to localize the spinal conduction block using the distal flexible three-contact electrodes. Applying these electrodes in a standard position, the conduction block can be recognized between them, covering a 4–5 cm long spinal segment. Decreasing the distance between the two electrodes by moving the distal electrode closer to the proximal one, theoretically leads to the appearance of eMEP response at the distal electrode also. (Note: Due to technical difficulties, the surgeon decided to change the orientation of the electrode, leading to inverted eMEP response (Fig. 3)). As d1 is the most distal contact of the electrode, we searched for the level where the response arouse between d1 and d2 contacts, as this was suggested to represent the starting point of the conduction block. Surgical incision was made at this level and the hematoma was successfully evacuated. (Fig. 4). TcMEP and SSEP amplitudes did not change after hematoma evacuation. (Fig. 2).

2.5. Postoperative course

The early postoperative course was uneventful, without novel neurological deficit, infection or local complication. The patient's sensory symptoms showed mild improvement. Early rehabilitation and enhanced recovery was started in multidisciplinary approach. The patient was admitted to a rehabilitation centre and is still doing both active and passive physiotherapy. The patient's symptoms and clinical findings improved: almost all movements of the left lower limb returned, sensory disturbances are ceased. Right lower limb spastic monoplegia, bilateral Babinski sign and urinary retention persist.

3. Discussion

There is a relatively rare need for surgical treatment of diseases affecting the spinal cord. It is, however, indispensable in case of performing a biopsy to differentiate an inflammation from a low grade tumour or to decompress the spinal cord because of parenchymal bleeding caused by a cavernoma, angioma or other intramedullary lesion. Detecting the lesion when the spinal cord looks intact from outside is demanding for the surgeon. In order to avoid damage of normal tissues and pathways, a generally accepted medial myelotomy is usually performed, however this approach is not suitable for cases where the pathology is located laterally or ventrally in the spinal cord. Additional techniques are required to aid in the verification of anatomical localization. Stereotactic intraoperative navigation is an evolving technique that can assist the surgeon when operating on the spinal cord (Butt et al., 2020; Quillo-Olvera et al., 2018). Although the use of O-arm has proven to be clinically reliable, it is not widely available and it represents additional radiation exposure for the patient (Zhang et al., 2020). Moreover, we need to take into consideration that our aim is to find a microscopic pathology in soft tissue, where neither type of navigation might be appropriate to determine the exact location. In these special cases IONM enhances the accuracy of localization and contributes to patient safety.

Recent advanced technology and IONM became so refined that each long tract of the spinal cord can be monitored: the dorsal col-

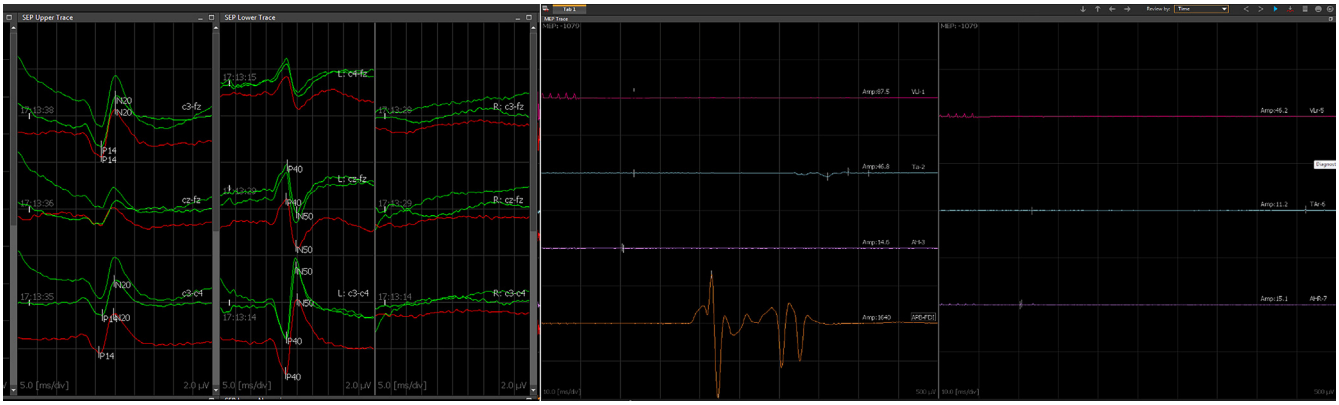

Fig. 2. IONM monitoring SSEP and tcMEP. SSEP signal elicited on the right tibial nerve were absent (see column no. 3). The other SSEP recording were found normal. The tcMEP responses (left leg + left arm – right leg) were recordable over the left upper extremity, but were lacking over the right lower extremity and only a small amplitude (50–60 μV) MEP response was detectable over the left tibialis anterior muscle, using maximal stimulus intensity. TcMEP and SSEP amplitudes did not changes after hematoma evacuation. (The red SSEP lines represent the preoperative baseline, while the green lines the postoperative responses.). (For interpretation of the references to colour in this figure legend, the reader is referred to the web version of this article.)

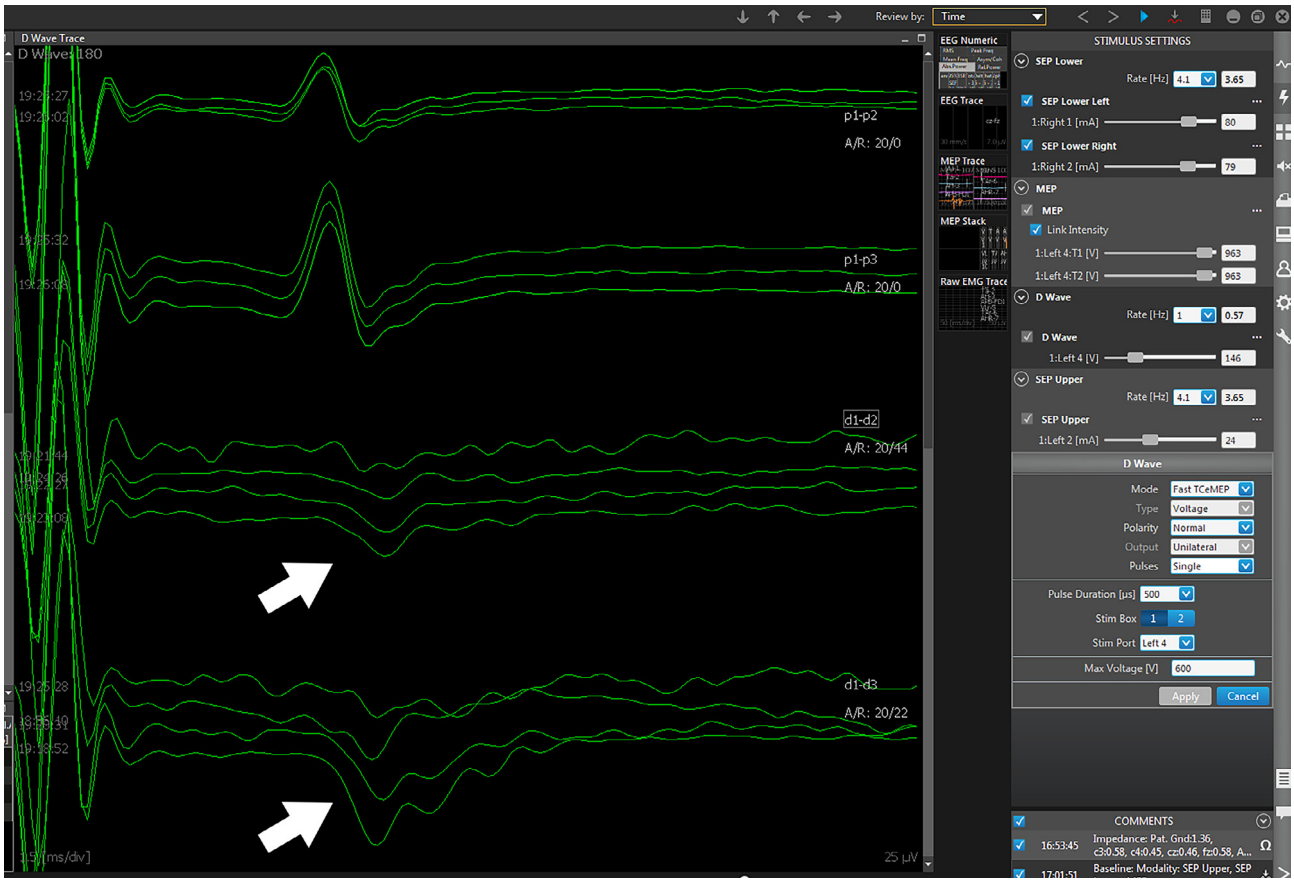

Fig. 3. IONM monitoring, eMEP. The upper two curves present three consecutive normal eMEP response recorded with the proximal flexible electrode (p1-p2 and p1-p3) in cascade arrangement. The lower two curves represent four consecutive eMEP responses recorded with the distal flexible electrode (d1-d2 and d1-d3) in cascade arrangement. Moving the electrode cranially, the eMEP is gradually built up (please see the arrows pointing towards the gradually developed electrical response).

umn being the major contributor in the generation of SSEP and the corticospinal tract monitored with tcMEP and eMEP recordings (Hilibrand et al., 2004). Among all the above mentioned techniques, eMEP provides direct information on the intact fast-conducting fibres of the pyramidal tract (Costa et al., 2013; Deletis and Sala, 2008) and eMEP recording became the gold-standard in monitoring the motor function in spinal cord surgery, being a strong predictor of motor recovery. Guidelines propose the loss of >50% of eMEP amplitude as a warning criterion (MacDonald et al., 2013). Indeed, postoperative outcome in intramedullary tumour surgery has proven to be favourable, even if tcMEP was lost during surgery, when the eMEP amplitude decreased by less than 50% (Deletis and Sala, 2008).

In the present case we opted for standard multimodal IONM techniques in order to prevent any serious consequence of the intervention. To our knowledge, this is the first report that eMEP

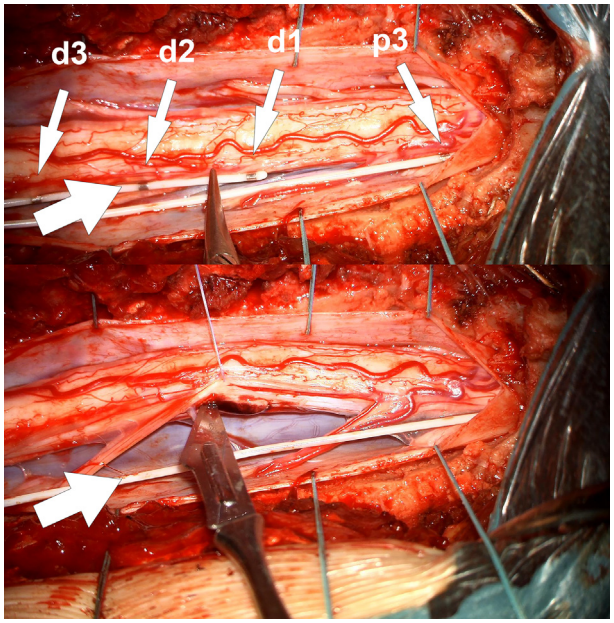

Fig. 4. Hematoma evacuation. On the upper picture the scissor points towards the lesion identified with eMEP. Please note the lack of macroscopic signs. (right caudal – left cranial). The lower picture demonstrates the adequate localization of the hematoma with eMEP. The wide arrows point towards the eMEP electrodes, narrow arrows show the contacts of them.

"mapping" was used for localization of a macroscopically undetectable lesion.

The absence of eMEP below the level of T10 should be considered prudently since the fibres of the corticospinal tract numerically decrease craniocaudally. In our case the hematoma was located at T8-T9, in the immediate neighbourhood of this boundary, which might serve as a technical difficulty when using eMEP for localization at this level (Husain, 2015).

Previously, few attempts were made to apply SSEP recording for intraoperative guiding, mainly in case of intramedullary tumour surgery due to distortion of anatomical structures (Quinones-Hinojosa et al., 2002; Yanni et al., 2010; Tsetsou et al., 2020). It has been concluded that the electrophysiological midline does not coincide with the apparent anatomical midline, emphasizing the aiding role of IONM (Quinones-Hinojosa et al., 2002). All the above mentioned studies used tcMEP and eMEP recordings for motor outcome prediction, instead of guiding myelotomy (Quinones-Hinojosa et al., 2002; Yanni et al., 2010; Tsetsou et al., 2020). In our case, the patient had severe motor symptoms and the MRI revealed that the lesion mainly had compromised the cortico-spinal tract. All of these facts lead to the decision to use eMEP recording from all the IONM modalities. We suggest that in cases where both tcMEP and eMEP are absent, changing the position of the distal D-wave electrodes permits the localization of the conduction block caused by an intramedullary lesion. Any change of tcMEP setup or protocol would not help in the aforementioned condition.

We need to emphasize the limitations of the present study. First of all, eMEP was used inadvertently for guiding. For further cases it would be crucial to plan preoperatively the most suitable technique that might change even the setup for monitoring. It is also worth to mention that combined IONM adds extra time to the duration of the surgery. Based on our experience, the benefit of using IONM exceeds the risk of longer procedural time. Nevertheless, our study suggests that eMEP recording not only provides a great potential in predicting the motor outcome, it might also be useful in detecting macroscopically challenging lesions. Larger controlled studies are needed before any far-reaching conclusion could be drawn.

4. Conclusion

The present case report supports the crucial role of IONM in spinal cord surgery. To our knowledge eMEP recording has never been previously used for guiding and localizing of an intramedullary hematoma. Despite the clear limitations of our study, it could result in new utilization of the aforementioned monitoring technique.

Declaration of competing interests

The authors declare that they have no known competing financial interests or personal relationships that could have appeared to influence the work reported in this paper.

Acknowledgements

We are very grateful to the operating team, especially to Dr. Kinga Bodó anaesthesiologist and Fatime Aradi operating room nurse for their outstanding work.

We thank to Tímea Szegi, MD, Neurologist and Jonathan Wasserberg, MD, Consultant Neurosurgeon Sheikh Shakhbout Medical City, Mayo Clinic, Abu Dhabi for proofreading the article.

References

Butt, B.B., Piche, J., Gagnet, P., Patel, R., Aleem, I., 2020. Stereotactic navigation in anterior cervical spine surgery: surgical setup and technique. J. Spine Surg. 6 (3), 598–605. https://doi.org/10.21037/jss-20-580.

Costa, P., Peretta, P., Faccani, G., 2013. Relevance of intraoperative D wave in spine and spinal cord surgeries. Eur. Spine J. 22 (4), 840–848. https://doi.org/10.1007/s00586-012-2576-5.

Deletis, V., Sala, F., 2008. Intraoperative neurophysiological monitoring of the spinal cord during spinal cord and spine surgery: a review focus on the corticospinal tracts. Clin. Neurophysiol. 119 (2), 248–264. https://doi.org/10.1016/j.clinph.2007.09.135.

Groen, R.J.M., 2004. Non-operative treatment of spontaneous spinal epidural hematomas: a review of the literature and a comparison with operative cases. Acta Neurochir (Wien). 146 (2), 103–110. https://doi.org/10.1007/s00701-003-0160-9.

Hilibrand, A.S., Schwartz, D.M., Sethuraman, V., Vaccaro, A.R., Albert, T.J., Bone, J., 2004. Comparison of transcranial electric motor and somatosensory evoked potential monitoring during cervical spine surgery. Joint Surg. Am. 86 (6), 1248–1253. https://doi.org/10.2106/00004623-200406000-00018.

Husain, A.M., 2015. A Practical Approach to Neurophysiologic Intraoperative Monitoring. Demosmedical, New York.

Leep Hunderfund, A.N., Wijdicks, E.F.M., 2009. Intramedullary spinal cord hematoma (hematomyelia). Rev. Neurol. Dis. 6, E54–E61. PMID: 19587631.

Legatt, A.D., Emerson, R.G., Epstein, C.M., MacDonald, D.B., Deletis, V., Bravo, R.J., López, J.R., 2016. ACNS Guideline: transcranial electrical stimulation motor evoked potential monitoring. J. Clin. Neurophysiol. 33 (1), 42–50. https://doi.org/10.1097/WNP.0000000000000253.

Kreppel, D., Antoniadis, G., Seeling, W., 2003. Spinal hematoma: a literature survey with meta-analysis of 613 patients. Neurosurg. Rev. 26 (1), 1–49. https://doi.org/10.1007/s10143-002-0224-y.

Macdonald, D.B., Skinner, S., Shils, J., Yingling, C., American Society of Neurophysiological Monitoring, 2013. Intraoperative motor evoked potential monitoring - a position statement by the American Society of Neurophysiological Monitoring. Clin. Neurophysiol. 124 (12), 2291–2316. https://doi.org/10.1016/j.clinph.2013.07.025.

Quillo-Olvera, J., Lin, G.X., Suen, T.K., Jo, H.J., Kim, J.S., 2018. Anterior transcorporeal tunnel approach for cervical myelopathy guided by CT-based intraoperative spinal navigation. J. Clin. Neurosci. 48, 218–223. https://doi.org/10.1016/j.jocn.2017.11.012.

Quinones-Hinojosa, A., Gulati, M., Lyon, R., Gupta, N., Yingling, C., 2002. Spinal cord mapping as an adjunct for resection of intramedullary tumors: surgical technique with case illustrations. Neurosurgery. 51 (5), 1199–1206. https://doi.org/10.1097/00006123-200211000-00015. discussion 1206–7.

Sheerin, F., Collison, K., Quaghebeur, G., 2009. Magnetic resonance imaging of acute intramedullary myelopathy: radiological differential diagnosis for the on-call radiologist. Clin. Radiol. 64 (1), 84–94. https://doi.org/10.1016/j.crad.2008.07.004.

Tsetsou, S., Butler, W., Borges, L., Eskandar, E.N., Fehnel, K.P., See, R.B., Simon, M.V., 2020. Dynamic mapping of the corticospinal tract in open cordotomy and myelomeningocele surgery. J. Clin. Neurosci. 74, 225–231. https://doi.org/10.1016/j.jocn.2020.01.054.

Yanni, D.S., Ulkatan, S., Deletis, V., Barrenechea, I.J., Sen, C., Perin, N.I., 2010. Utility of neurophysiological monitoring using dorsal column mapping in intramedullary spinal cord surgery. J Neurosurg. Spine 12 (6), 623–628. https://doi.org/10.3171/2010.1.SPINE09112.

Zhang, P., Liu, H., Sun, Z., Wang, J., Wang, G., 2020. The application of O-arm and navigation system in precise localization of spinal cord lesions: a case series study. Clin. Neurol. Neurosurg. 196,. https://doi.org/10.1016/j.clineuro.2020.105922 105922.