









GUIDELINES

Acute generalized exanthematous pustulosis: European expert consensus for diagnosis and management

F. Tetart^{1,2,3} | S. Walsh^{2,4}  | B. Milpied^{2,3,5}  | K. Gaspar^{2,6} | A. Vorobyev^{2,7,8} | G. S. Tiplica^{2,9} | B. Didona^{2,10} | A. Welfringer-Morin^{2,11}  | V. Kucinskiene^{2,12} | B. Bensaid^{2,3,13} | E. Marvanova¹⁴ | C. Salavastru^{2,15} | E. Brezinova^{2,14} | S. L. Chua^{2,16} | M. L. Lovgren^{2,17} | C. M. Hammers^{2,18} | A. Barbaud^{2,3,19}  | C. G. Mortz^{2,20} | B. Horvath^{2,21} | D. Meyersburg^{2,22}  | B. Lebrun-Vignes^{2,3,23} | C. Bodemer^{2,3,11} | M. C. Brüggem^{2,24,25,26}  | L. E. French^{2,27,28}  | S. Ingen-Housz-Oro^{2,3,29,30} 

Correspondence

F. Tetart, Department of Dermatology and Allergology, Charles Nicolle University Hospital, 37 Boulevard Gambetta, Rouen 76000, France.
Email: florence.tetart@chu-rouen.fr

Abstract

Acute generalized exanthematous pustulosis (AGEP) is a rare, usually drug-induced, acute pustular rash. Despite the lack of strong data supporting the effectiveness of topical or systemic corticosteroids in this drug reaction, they are widely used. More generally, there is no consensus on the diagnostic modalities and the management of patients with AGEP. We aimed to provide European expert recommendations for the diagnosis and management of patients with AGEP. Members of the ToxiTEN group of the European Reference Network (ERN)-skin, all dermatologists and/or allergologists with expertise in drug reactions, elaborated these recommendations based on their own experience and on a review of the literature. Recommendations were separated into the following categories: professionals involved, assessment of the diagnosis of AGEP, management of the patient and allergological work-up after the acute phase. Consensus was obtained among experts for the list of professionals involved for the diagnosis and management of AGEP, including the minimum diagnostic work-up, the setting of management, the treatments, the modalities and the timing of allergological work-up and follow-up. European experts in drug allergies propose herein consensus on the diagnosis and management of patients with AGEP. A multidisciplinary approach is warranted, including dermatologists, allergologists and pharmacovigilance services.

BACKGROUND AND CURRENT KNOWLEDGE

Acute generalized exanthematous pustulosis (AGEP) is a rare, usually drug-induced, acute pustular rash. Its estimated incidence lies between 1 and 5 cases per million per year.¹ The overall prognosis is very good, with a very low reported

mortality rate (<5%).² The disease affects mainly adults (median age 60 years old) with a female predominance.³

AGEP is characterized by the acute onset of erythema predominantly in the large skinfolds with multiple pinpoint non-follicular sterile pustules, usually associated with fever. Additional skin symptoms may involve oedema of the face and non-specific lesions like purpura, atypical targets,

For affiliations refer to page 2079.

This is an open access article under the terms of the [Creative Commons Attribution-NonCommercial-NoDerivs](https://creativecommons.org/licenses/by-nc-nd/4.0/) License, which permits use and distribution in any medium, provided the original work is properly cited, the use is non-commercial and no modifications or adaptations are made.

© 2024 The Author(s). *Journal of the European Academy of Dermatology and Venereology* published by John Wiley & Sons Ltd on behalf of European Academy of Dermatology and Venereology.

vesicles and more rarely blisters. Confluence of pustules may result in an extensive superficial detachment known as 'pseudo-Nikolsky sign'. Mucosal involvement arises in less than 20% of cases, usually limited to the mouth.^{4,5} Biological abnormalities include leucocytosis with neutrophilia, elevated C-reactive protein (CRP) and, in one-third to half of cases, mild eosinophilia.^{3,4} Systemic involvement may be observed in 17% of cases: mainly liver, and, rarely, kidney, bone-marrow or lung involvement.^{6,7} Moreover, haemodynamic instability including hypotension or even shock, occurs in 22% of AGEP patients.^{7,8} Systemic involvement raises the question of an overlap between AGEP and either drug reaction with eosinophilia and systemic symptoms (DRESS) or, more rarely, toxic epidermal necrolysis (TEN).⁹ The EuroSCAR score is a useful tool to assess the certainty of AGEP diagnosis (Table 1).¹

Cases of localized exanthematous pustulosis (ALEP) have also been described, especially with topical drugs but the pathogenesis is still unclear.^{10,11}

A recent study from the United States reported the frequent association of AGEP with comorbidities including diabetes mellitus, kidney failure, past history of psoriasis and hypersensitivity reactions.³ Furthermore, body mass index may be higher with AGEP patients than in those with DRESS.¹²

Skin biopsy including a pustule is useful for confirming the diagnosis of AGEP. Histological findings are spongiform subcorneal and/or intraepithelial pustules, oedematous papillary dermis and perivascular infiltrates with neutrophils and some eosinophils. In some cases, necrotic keratinocytes and leucocytoclastic vasculitis are observed.¹³ The presence of psoriasiform acanthosis, papillomatosis and tortuous or dilated vessels is suggestive of the main differential diagnosis of AGEP, generalized pustular psoriasis (GPP).¹⁴

Family or personal history of psoriasis is often present in AGEP (7%–10%).^{3,7} The main differential diagnosis of AGEP is GPP. Pustules can be larger, their onset slower and their duration longer in GPP than in AGEP. Other pustular dermatoses are very rare: subcorneal pustulosis or Sneddon–Wilkinson, IgA pemphigus, pustular vasculitis, pustular Sweet syndrome and staphylococcal scalded skin syndrome (SSSS). In GPP and other pustular dermatoses, history of an adverse cutaneous drug reaction and recent drug administration are unusual. AGEP can sometimes also be confused with other adverse cutaneous drug reactions. Indeed, pustules may be present in DRESS, especially on the face and more rarely in large body folds. Pustules may also be observed in other cutaneous adverse reactions characterized by their involvement of the large body folds such as symmetrical drug-related intertriginous and flexural exanthema (SDRIFE) and in Baboon syndrome.^{15,16}

AGEP is drug-induced in 90% of cases. The main causative drugs are antibiotics, that is, pristinamycin, aminopenicillins, quinolones, sulfonamides, but also (hydroxy) chloroquine, terbinafine and diltiazem.⁴ A French series reported 19 AGEP cases due to iodinated contrast media.¹⁷ The time from initiation of drug intake and AGEP onset is

TABLE 1 AGEP validation score of the EuroSCAR study group.¹

Morphology	Pustules	Typical ^a	+2
		Compatible ^b	+1
		Insufficient ^c	0
	Erythema	Typical	+2
		Compatible	+1
		Insufficient	0
	Distribution/pattern	Typical	+2
		Compatible	+1
		Insufficient	0
Post-pustular desquamation	Yes	+1	
	No/insufficient	0	
Course	Mucosal involvement	Yes	-2
		No	0
	Acute onset (≤10 days)	Yes	0
		No	-2
	Resolution (≤15 days)	Yes	0
		No	-4
	Fever ≥38°C	Yes	+1
		No	0
	Neutrophils ≥7000/mm ³	Yes	+1
No		0	
Histology	Other disease	-10	
	Not representative/no histology	0	
	Exocytosis of neutrophils	+1	
	Subcorneal and/or intraepidermal non spongiform or NOS pustule(s) with papillary oedema or subcorneal and/or intraepidermal spongiform or NOS pustule(s) without papillary oedema	+2	
	Spongiform subcorneal and/or intraepidermal pustule(s) with papillary oedema	+3	

Interpretation: ≤0: no AGEP; 1–4: possible; 5–7: probable; 8–12: definite.

Abbreviation: NOS, not otherwise specified.

^aTypical: typical morphology as described in the 'clinical features' section.

^bCompatible: not typical, but not strongly suggestive of other disease.

^cInsufficient: lesions cannot be judged (mostly because of late stage of the disease or poor quality of pictures).

usually very short, ranging from 1 to 3 days, especially for antibiotics and iodinated contrast media, and longer, around 7–10 days for other trigger drugs.^{4,7,17} Recently, the European Academy of Allergy and Clinical Immunology (EAACI) made a position statement to specify that AGEP should be considered when the time to onset lies between 1 and 12 days of suspect drug intake.¹⁸ However, longer latency periods were described in hydroxychloroquine-induced AGEP (from 12 to 40 days). These AGEP seem to be very particular, with a long regression time and a frequent need for a systemic treatment. In some cases, mutations in the CARD14 gene have been described.^{19,20} Other rare reported aetiologies of AGEP

are spider bites, vaccines, toxic causes such as mercury poisoning and infections, especially in childhood for these latter causes.^{21–24}

Recent findings improved the understanding of AGEP pathophysiology. The disease results from an aberrant immune response mainly visible in the skin that involves both innate and adaptive immune response. Most of the drug-specific T cells produce IL-8, a powerful chemoattractant for neutrophils. Beside elevated circulating Th17 cells are observed in AGEP patients. Their main cytokines, IL-17 and IL-22, stimulate keratinocytes to produce IL-8.²⁵ Culprit drugs can also induce the production of IL-36 by monocytes in AGEP patients, even later after the acute phase.²⁶ Furthermore, *IL36RN* mutations, frequent in GPP, have also been rarely described in patients with AGEP.²⁷

Allergological explorations are more and more commonly used in delayed cutaneous drug hypersensitivity reactions. Positivity of tests depend upon the type of drug reaction and the offending drug. Patch tests have a good sensitivity in AGEP, with a positivity of 58% in a French multicentre study, especially for drugs like pristinamycin or amoxicillin.²⁸ Prick tests seem of limited use, but intradermal reactions with delayed readings could be useful in AGEP, especially to identify safe alternative drugs.^{17,29} There exist very little data concerning drug rechallenging in AGEP. One study recently suggested the potential of a modified lymphocyte transformation test assay in AGEP.³⁰

There is no published therapeutic trial on specific treatment of AGEP. In particular, there are no strong data supporting the effectiveness of topical or systemic corticosteroids in this drug reaction. Nevertheless, topical corticosteroids, thanks to their anti-inflammatory effect, could be of interest in AGEP by reducing vasodilatation and the activation of neutrophils. A French retrospective monocentre study published in 2015 compared the management of patients with AGEP in three time periods from 1994 to 2011. The use of topical corticosteroids (either potent, grade III or super potent, grade IV, 10–30 g/day for 1–2 weeks) increased with time (from 25% to 89% of patients) during the period studied paralleling a progressive shortening of the length of hospitalization (from 7 to 5 days, $p = 0.045$).³¹ This study indirectly supports the potential use of topical corticosteroids in AGEP. A retrospective monocentre Singaporean study published in 2021 investigated the management of 43 patients with AGEP. Nine of them (21%) received systemic corticosteroids, with a mean dose of methylprednisolone of 32 mg/day for a mean duration of 4 days, and the others received topical corticosteroids of various potencies. Patients' characteristics were comparable except for kidney failure, which was observed more frequently in the group of patients treated with systemic corticosteroids. The median duration of hospitalization was shorter in patients receiving systemic corticosteroids compared to those who did not (6 vs. 10 days, $p = 0.035$). Systemic corticosteroids were not associated to a higher rate of adverse

effects, especially infections and death, in this series.³² There exist no strong data supporting the effectiveness of therapies other than corticosteroids in AGEP. Eight patients with relative contraindication to systemic corticosteroids received cyclosporine (3 mg/kg/day tapered over 2 weeks) in a study published in 2020. Compared to 23 patients treated with systemic corticosteroids (methylprednisolone 1 mg/kg/day tapered with variable regimens), these patients had a similar time to resolution of the erythema and a similar length of hospitalization.³³

The aim of this position paper is to provide European expert recommendations for the diagnosis and management of patients with AGEP.

METHODS

Members of the ToxiTEN group of the European Reference Network (ERN)-skin, dedicated to severe cutaneous adverse reactions, all dermatologists and/or allergologists with expertise in drug reactions from 12 European countries, met to write these recommendations, based on their own experience in the management of AGEP and on a review of the literature. The latter was conducted by two of the experts (FT and SIHO) using PubMed without time limitation, with preferred terms “Acute generalized exanthematous pustulosis, AGEP” and “diagnosis, clinical manifestations, visceral involvement, drugs, histology, treatment.” Only articles in English language and considered to be of interest for the purpose of these recommendations were retained.

As previously mentioned above, due to the lack of randomized therapeutic trials in AGEP, the level of recommendations in the literature was low (grade C). We therefore favoured expert opinions for these recommendations.

The following categories were discussed for these recommendations: professionals involved, assessment of the diagnosis of AGEP (including additional work-up), management of the patient (including setting, offending drug management and treatment) and allergological work-up after the acute phase.

EUROPEAN EXPERT CONSENSUS FOR THE DIAGNOSIS AND MANAGEMENT OF PATIENTS WITH AGEP

Professionals involved

The professionals to be involved in the management of patients with AGEP depend on the need:

Diagnosis upon first presentation

Should involve the general practitioner (GP), emergency specialist, dermatologist and paediatrician (if child affected).

Patient management during the acute phase

Should involve:

- dermatologist and/or allergologist (all patients regardless of the age),
- paediatrician (if child affected),
- organ specialists if visceral involvement is present (especially hepato-gastro-enterologist and nephrologist),
- dermato-pathologist or pathologist (histological analysis of the skin biopsy),
- psychologist (if need of psychological support),
- intensive care medicine specialist (for severe cases, especially those with hemodynamic instability),
- pharmacovigilance specialist (for drug management) and
- nurses with experience in skin care.

Allergological workup

Performed after the acute phase, it should involve a dermatologist or an allergologist with expertise in severe drug reactions, and a clinical pharmacologist or a pharmacist.

Assessment of the diagnosis and additional work-up

The diagnosis of AGEP should be considered in patients with fever, altered general condition and maculopapular exanthema with more or less coalescent non-follicular pustules predominating in large skinfolds. A pseudo-Nikolsky sign may be observed, not to be misdiagnosed with the true Nikolsky sign of epidermal necrolysis. Mucous membranes are spared. The patient's drug history should report the onset of a suspect drug (usually first exposure) within the past 12 days.¹⁸ As specified above, the diagnosis may be more difficult because of atypical presentations, including ALEP. Patient's past history, including the search of a prior drug reaction history, a personal or familial context of psoriasis, ongoing pregnancy, staphylococcal or streptococcal infection, may help to eliminate a differential diagnosis.

General examination includes body temperature, pulse rate and blood pressure record and evaluation of the context of the patient (age, comorbidities, kidney or liver insufficiency) that may affect the tolerance of a febrile disseminated skin eruption and the suspect drug elimination.

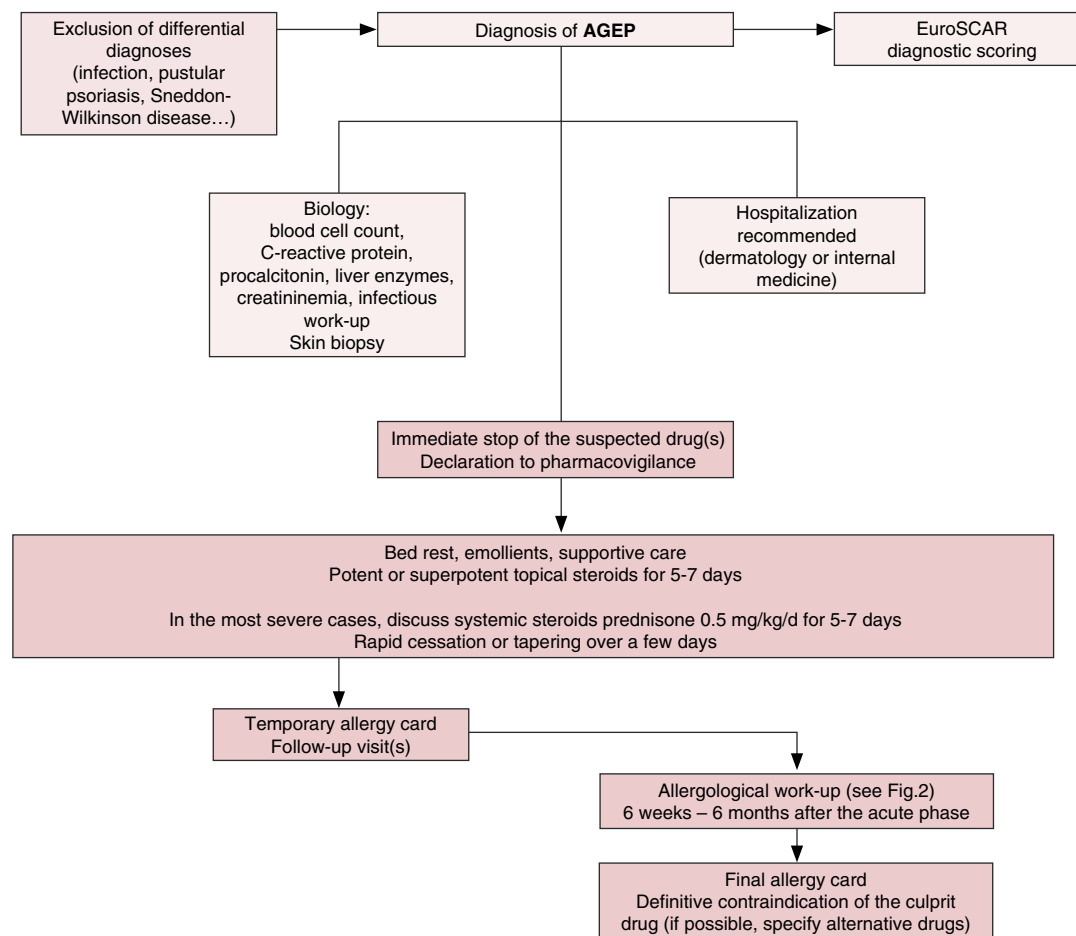


FIGURE 1 Management algorithm of AGEP.

Once the diagnosis is established, the next two steps to be performed simultaneously and without delay are the withdrawal of the suspected drug(s) and the prescription of additional work-up (Figure 1, Table 2):

Biological samples

The expert group recommends to perform without delay in all suspected or confirmed cases or AGEP the following biological examination: differential blood cell count including neutrophils and eosinophils, platelets, blood chemistry, urea, creatinine, liver enzymes and C-reactive protein.

In patients with fever (38.5°C or higher), blood cultures, and bacterial and mycological pustule samplings should be performed. In cases overlapping with DRESS, *Herpes virus* blood PCR (EBV, HHV6 and CMV) should be ordered.

If pustular psoriasis of pregnancy is suspected, a pregnancy test should be performed in childbearing women.

Protein electrophoresis to search for a monoclonal gammopathy is needed in case where a diagnosis of Sneddon-Wilkinson disease is suspected.

Skin biopsy

A skin biopsy, including a pustule, should be performed in all cases of AGEP, to assess the diagnosis of AGEP and

TABLE 2 Additional work-up recommended by the expert group for the diagnosis and management of AGEP at the acute phase.

Exams to assess the diagnosis of AGEP	Exams to exclude differential diagnoses according individual situations
<i>Biology:</i> Differential blood cell count (including neutrophils and eosinophils) Blood chemistry (ionogram, urea, creatinemia, liver enzymes and C-reactive protein)	<i>Biology:</i> Pregnancy test Protein electrophoresis
<i>Skin biopsy:</i> Histology ± direct immunofluorescence	Procalcitonin <i>Herpes virus</i> PCR (HHV6, EBV and CMV)
	<i>Microbiological samples:</i> Blood cultures <i>Mycoplasma pneumoniae</i> serology and nasopharyngeal PCR Bacteriological and mycological pustules samples
	<i>Skin biopsy:</i> Histology ± direct immunofluorescence

exclude differential diagnoses, even if excluding pustular psoriasis may be challenging.³⁴ Direct immunofluorescence should be performed if autoimmune blistering disease such IgA pemphigus needs to be ruled out. Furthermore, histological results are necessary to calculate the EuroScar diagnosis score (Table 1) in doubtful cases.⁴

Management of the patient

Setting

Although AGEP has a favourable outcome in the majority of cases, some patients may have a more severe presentation, because of

- extent and severity of skin lesions (erythroderma, extensive and confluent pustules with pseudo-Nikolsky sign),
- refractory fever,
- systemic involvement (elevated liver enzymes and kidney insufficiency),
- hemodynamic instability and
- fragile populations (children, elderly, underlying severe comorbidities, immunosuppression...).

Consequently, the expert group recommends inpatient hospitalization (of choice, where possible, in a dermatology or internal medicine department), for optimized bed rest, supportive skin care, clinical and biological monitoring. The intensive care unit (ICU) should be informed in case of significant signs of severity or severely deranged vital signs (especially hemodynamic instability).

If hospitalization is not possible for any practical reason, close clinical (± biological according initial abnormalities) monitoring daily or every other day is necessary.

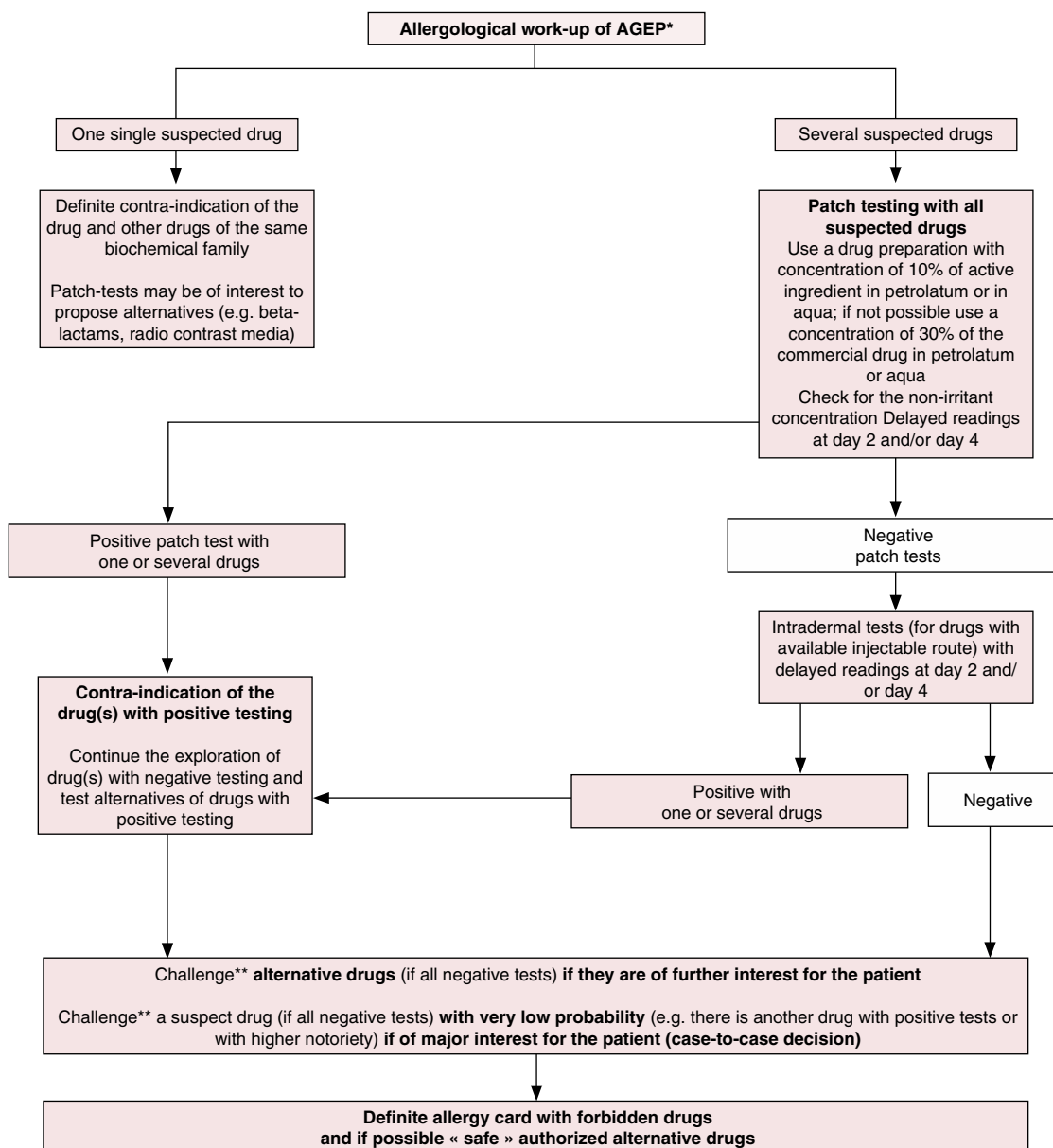
Drug management

The suspected causal drug(s) must be stopped immediately and the pharmacovigilance department should be advised as soon as possible.

Treatment

All patients should be placed on bed rest until significant improvement and receive supportive care including mild soap substitutes baths or showers, moisturizing cream and oral or intravenous hydration according to the clinical status and biological changes. For the most severe patients (extensive skin lesions and pseudo-Nikolsky sign), supportive care could be based on the existing recommendations for epidermal necrolysis.³⁵

Even if the pustules tend to resolve spontaneously within a few days, with a characteristic pattern of punctate



*allergological work-up must be performed only by trained teams in expert centers

**with full or progressive doses

FIGURE 2 Allergological work-up of AGEP.

desquamation, most experts recommend the possible use of topical corticosteroids as specific treatment of AGEP:

In adults

Grade IV topical corticosteroids (e.g. clobetasol) 20–40 g/day according to the patient's body surface, applied once a day on the whole body except the face which is usually not involved in AGEP. A daily treatment for 5–7 days is recommended, that is, until complete or almost complete clearing, and/or post-inflammatory desquamation. The value of slow tapering has not been demonstrated in this disease, and considering the low risk of rebound, a rapid discontinuation of topical corticosteroids may be considered.

In children

Grade III topical corticosteroids (e.g. betamethasone valerate and mometasone) can be used. As it is not a chronic disease, the most important is to use the quantity required for a complete healing of lesions. The fingertip unit (FTU) method can be proposed: 1 FTU, meaning 0.5 g, covering a body surface area equivalent to two adult handprints.

In the most severe cases, that is, with systemic involvement (e.g. liver or kidney abnormalities and haemodynamic instability) or very severe skin lesions (erythroderma and disseminated pustules), a short systemic corticosteroid therapy with prednisone 0.5 mg/kg/day for a duration of 5–7 days may be considered. As for topical steroids, a rapid stopping

of prednisone may be performed, but a rapid taper over a few days may also be considered.

Experts consider that data for cyclosporine are not strong enough to recommend the use of this drug in routine practice for AGEP.

In the rare cases of AGEP that overlap with probable or certain DRESS (RegiScar score ≥ 4), the patient must be treated as a DRESS, with a longer duration of full-dose topical or systemic corticosteroids followed by progressive corticosteroid tapering over at least 3 months.⁵

A follow-up visit is suggested 1 month after discharge, to check complete healing and to organize the allergological work-up. In contrast with DRESS, there are no sequelae in AGEP. No biological follow-up tests are needed except in cases with significant abnormalities in the acute phase.

Allergological work-up after the acute phase

A provisional allergy card clearly mentioning the suspected drug(s) must be given to the patient, their family and GP at discharge from hospital. Experts consider that skin tests only are of interest in AGEP. Indeed, *in vitro* tests are of limited use given the lack of data in AGEP.

Skin tests must be performed by allergologists or dermatologists with expertise in adverse cutaneous drug reactions. The optimal time to perform skin tests is 6 weeks to 6 months after the acute phase. The aims of the tests are (1) to confirm the culprit drug, especially in case of multiple suspects; and (2) to search of safe alternatives within the same drug family (beta-lactams, radio contrast media, etc.).

Patch tests are sensitive and safe in AGEP and are recommended in first-line investigation. Thanks to their good sensitivity in AGEP, patch tests are sufficient in the majority of cases.³⁶ However, intradermal tests may be performed in case of negative patch tests, especially for some drugs such as radio contrast media in which their interest was raised.¹⁷ Rechallenge with the suspect drug should never be performed. Oral provocation tests may be considered as a case-to-case decision by experts of drug allergies, but only for alternative drugs with negative skin tests results, and only if useful for the patient. After a case-to-case discussion in expert centres, the rechallenge of a suspected drug with low probability, with negative tests results, and when there is another suspect drug with positive tests and/or higher notoriety, may be discussed, if very useful for the patient. Modalities of rechallenge are not consensual among experts (progressive dose as in DRESS³⁷ or full dose) (Figure 2).

After the allergological work-up, a definitive allergy card must be given to the patient, their relatives and GP to avoid any risk of erroneous resumption of the suspect drug that would expose the patient to a risk of relapse, potentially with a more severe presentation with systemic involvement.⁶

In conclusion, European experts of the ToxiTEN ERN-skin group propose expert consensus recommendations for the diagnosis and management of patients with AGEP (Figure 1). These recommendations cannot cover all

situations and must be adapted to each patient's particularities. Cases must be discussed with doctors with expertise in severe adverse cutaneous drug reactions and a multidisciplinary approach, including dermatologists, allergologists and pharmacovigilance services, is warranted.

AFFILIATIONS

¹Department of Dermatology and Allergology, Charles Nicolle University Hospital, Rouen, France

²ToxiTEN Group, European Reference Network for Rare Skin Diseases (ERN Skin), Paris, France

³Toxic Bullous Dermatoses and Severe Drug Reactions TOXIBUL Reference Center, AP-HP, Henri Mondor Hospital, Créteil, France

⁴Department of Dermatology, King's College Hospital, London, UK

⁵Department of Dermatology, University Hospital of Bordeaux, Bordeaux, France

⁶Department of Dermatology, Faculty of Medicine, University of Debrecen, Debrecen, Hungary

⁷Lübeck Institute of Experimental Dermatology, University of Lübeck, Lübeck, Germany

⁸Department of Dermatology, University Medical Center Schleswig-Holstein, Lübeck, Germany

⁹Department of Dermatology II, Colentina Clinical Hospital, Carol Davila University of Medicine and Pharmacy, Bucharest, Romania

¹⁰Center of Rare Diseases IDI-IRCCS-Rome, Rome, Italy

¹¹Department of Dermatology, Necker-Enfants Malades University Hospital, Paris, France

¹²Department of Skin and Venereal Diseases, Lithuanian University of Health Sciences (LUHS), Hospital of LUHS Kauno Klinikos, Kaunas, Lithuania

¹³Department of Dermatology, Edouard Herriot University Hospital, Lyon, France

¹⁴Department of Dermatovenereology, Faculty of Medicine, St. Ann's University Hospital, Masaryk University, Brno, Czech Republic

¹⁵Department of Paediatric Dermatology, Colentina University Hospital, Carol Davila University of Medicine and Pharmacy, Bucharest, Romania

¹⁶Department of Dermatology, University Hospitals Birmingham, Birmingham, UK

¹⁷Birmingham Children's Hospital, Birmingham Women's and Children's NHS Foundation Trust, Birmingham, UK

¹⁸Department of Dermatology, Christian-Albrechts-University Kiel, Kiel, Germany

¹⁹Department of Dermatology and Allergology, Tenon Hospital, Sorbonne Université, INSERM, Institut Pierre Louis d'Epidemiologie et de Sante Publique, AP-HP Sorbonne Université, Paris, France

²⁰Department of Dermatology and Allergy Center, Odense University Hospital, University of Southern Denmark, Odense, Denmark

²¹Department of Dermatology, Center for Blistering Diseases, University Medical Center Groningen, University of Groningen, Groningen, The Netherlands

²²Department of Dermatology and Allergology, University Hospital Salzburg of the Paracelsus Medical University Salzburg, Salzburg, Austria

²³Regional Pharmacovigilance Centre, Pitié-Salpêtrière Hospital, APHP, Sorbonne Université, Paris, France

²⁴Department of Dermatology, University Hospital of Zurich, Zurich, Switzerland

²⁵Faculty of Medicine, University of Zurich, Zurich, Switzerland

²⁶Christine Kühne-Center for Allergy Research and Education Davos (CK-CARE), Davos, Switzerland

²⁷Department of Dermatology and Allergy, University Hospital, Ludwig Maximilian University (LMU) Munich, Munich, Germany

²⁸Dr. Philip Frost Department of Dermatology and Cutaneous Surgery, University of Miami Miller School of Medicine, Miami, Florida, USA

²⁹Department of Dermatology, AP-HP, Henri Mondor University Hospital, Créteil, France

³⁰Univ Paris Est Créteil EpiDermE, Créteil, France

FUNDING INFORMATION

No funding source.

CONFLICT OF INTEREST STATEMENT

C. Salavastru (Springer Nature—Royalties, authorship agreement), G. S. Tiplica (Abbott, Organon, Genesis Biopharma Romania SRL, Leo Pharma Romania, Antibiotice SA and BMS—honoraria for lectures; IUSTI-Europe—chair of the council; Romanian Association of dermatology and venereology—president; EAFWH—secretary general); SL Chua

(Boehringer-Ingelheim Ltd, Novartis Pharmaceuticals, UCB and Almiral Ltd—consulting fees; Almiral Ltd, Novartis Pharmaceuticals, UCB—support for attending meetings; British association of dermatologists—chair and guideline sub-committee); B. Horvath (Janssen-Cilag, AbbVie, Novartis, UCB Pharma, Roche, Regeneron, Sanofi, Argenx and Boehringer-Ingelheim—grants to the institution and contracts, consulting and honoraria for lectures paid to the institution); Other authors (No COI).


DATA AVAILABILITY STATEMENT

The data that support the findings of this study are available from the corresponding author upon reasonable request.

ORCID

S. Walsh  <https://orcid.org/0000-0002-8279-0506>

B. Milpied  <https://orcid.org/0000-0003-3679-6613>


A. Welfringer-Morin  <https://orcid.org/0000-0001-7479-3689>

A. Barbaud  <https://orcid.org/0000-0001-8889-1589>

D. Meyersburg  <https://orcid.org/0000-0001-8339-6917>

M. C. Brüggemann  <https://orcid.org/0000-0002-8607-6254>

L. E. French  <https://orcid.org/0000-0002-4629-1486>

S. Ingen-Housz-Oro  <https://orcid.org/0000-0002-5383-7096>

REFERENCES

- Sidoroff A, Halevy S, Bavinck JN, Vaillant L, Roujeau JC. Acute generalized exanthematous pustulosis (AGEP) – a clinical reaction pattern. *J Cutan Pathol*. 2001;28(3):113–9.
- Roujeau JC. Clinical heterogeneity of drug hypersensitivity. *Toxicology*. 2005;209(2):123–9.
- Creadore A, Desai S, Alloo A, Dewan AK, Bakhtiar M, Cruz-Diaz C, et al. Clinical characteristics, disease course, and outcomes of patients with acute generalized Exanthematous Pustulosis in the US. *JAMA Dermatol*. 2022;158(2):176–83.
- Sidoroff A, Dunant A, Viboud C, Halevy S, Bavinck JNB, Naldi L, et al. Risk factors for acute generalized exanthematous pustulosis (AGEP)—results of a multinational case-control study (EuroSCAR). *Br J Dermatol*. 2007;157(5):989–96.
- Duong TA, Valeyrie-Allanore L, Wolkenstein P, Chosidow O. Severe cutaneous adverse reactions to drugs. *Lancet*. 2017;390(10106):1996–2011.
- Hotz C, Valeyrie-Allanore L, Haddad C, Bouvresse S, Ortonne N, Duong TA, et al. Systemic involvement of acute generalized exanthematous pustulosis: a retrospective study on 58 patients. *Br J Dermatol*. 2013;169(6):1223–32.
- Weiss M, Assier H, Hotz C, Hua C, Thomas L, Wolkenstein P, et al. Acute generalized exanthematous pustulosis: clinico-biological profile and inducing drugs in 83 patients. *J Eur Acad Dermatol Venereol*. 2023;37(6):e776–e778.
- O'Brian M, Carr CL, Thomas C, Dominguez AR, Mauskar M. Clinical characteristics and management of acute generalized exanthematous pustulosis with haemodynamic instability. *Skin Health Dis*. 2021;1(4):e74.
- Bouvresse S, Valeyrie-Allanore L, Ortonne N, Konstantinou MP, Kardaun SH, Bagot M, et al. Toxic epidermal necrolysis, DRESS, AGEP: do overlap cases exist? *Orphanet J Rare Dis*. 2012;7:72.
- Safa I, Ines L, Noureddine L, Meriem J, Manel N, Belhajali H, et al. Acute localized exanthematous pustulosis: clinical features, pathophysiology, and therapy. *Dermatol Ther*. 2021;34(5):e15087.
- Makris M, Kanelleas A, Papapostolou N, Pisimisi M, Katoulis AC. Acute localized Exanthematous Pustulosis (ALEP) caused by topical application of Minoxidil. *J Clin Med*. 2023;12(3):831.
- Gallardo MA, Mallela T, Gilkey T, Himed S, Walker TD, Nusbaum KB, et al. Demographic and laboratory differences seen between acute generalized exanthematous pustulosis and drug reaction with eosinophilia and systemic symptoms: a cross-sectional analysis. *J Am Acad Dermatol*. 2023;88(5):1142–5.
- Feldmeyer L, Heidemeyer K, Yawalkar N. Acute generalized Exanthematous Pustulosis: pathogenesis, genetic background, clinical variants and therapy. *Int J Mol Sci*. 2016;17(8):1214.
- Sussman M, Napodano A, Huang S, Are A, Hsu S, Motaparthy K. Pustular psoriasis and acute generalized Exanthematous Pustulosis. *Medicina (Kaunas)*. 2021;57(10):1004.
- Häusermann P, Harr T, Bircher AJ. Baboon syndrome resulting from systemic drugs: is there strife between SDRIFE and allergic contact dermatitis syndrome? *Contact Dermatitis*. 2004;51(5–6):297–310.
- de Risi-Pugliese T, Barailler H, Hamelin A, Amsler E, Gaouar H, Kurihara F, et al. Symmetrical drug-related intertriginous and flexural exanthema: a little-known drug allergy. *J Allergy Clin Immunol Pract*. 2020;8(9):3185–3189.e4.
- Soria A, Amsler E, Bernier C, Milpied B, Tétart F, Morice C, et al. DRESS and AGEP reactions to iodinated contrast media: a French case series. *J Allergy Clin Immunol Pract*. 2021;9(8):3041–50.
- Brockow K, Ardern-Jones MR, Mockenhaupt M, Aberer W, Barbaud A, Caubet JC, et al. EAACI position paper on how to classify cutaneous manifestations of drug hypersensitivity. *Allergy*. 2019;74(1):14–27.
- Chaabouni R, Bahloul E, Ennouri M, Atheymen R, Sellami K, Marrakchi S, et al. Hydroxychloroquine-induced acute generalized exanthematous pustulosis: a series of seven patients and review of the literature. *Int J Dermatol*. 2021;60(6):742–8.
- Luo F, Yuan XM, Xiong H, Yang YZ, Chen CM, Ma WK, et al. Clinical features of acute generalized exanthematous pustulosis caused by hydroxychloroquine in rheumatology patients and exploration of CARD14 gene mutations. *Front Med (Lausanne)*. 2023;10:1161837.
- Bhat YJ, Akhtar S, Ahmad M, Hassan I, Wani R. Etiopathological and clinical study of acute generalized Exanthematous Pustulosis: experience from a tertiary care hospital in North India. *Indian Dermatol Online J*. 2020;11(3):391–7.
- Mebazaa A, Kort R, Zaiem A, Elleuch D, Moula H, Cheikhrouhou R, et al. Acute generalized exanthematous pustulosis. Study of 22 cases. *Tunis Med*. 2010;88(12):910–5.
- Lee EY, Koh MJA. Acute generalized exanthematous pustulosis in children and adolescents in Singapore: a ten-year retrospective review. *Pediatr Dermatol*. 2021;38(2):424–30.
- Parisi R, Shah H, Navarini AA, Muehleisen B, Ziv M, Shear NH, et al. Acute generalized Exanthematous Pustulosis: clinical features, differential diagnosis, and management. *Am J Clin Dermatol*. 2023;24(4):557–75.
- Stadler PC, Oschmann A, Kerl-French K, Maul JT, Opiel EM, Meier-Schiesser B, et al. Acute generalized Exanthematous Pustulosis: clinical characteristics, pathogenesis, and management. *Dermatology*. 2023;239(3):328–33.
- Meier-Schiesser B, Feldmeyer L, Jankovic D, Mellett M, Satoh TK, Yerly D, et al. Culpit drugs induce specific IL-36 overexpression in acute generalized Exanthematous Pustulosis. *J Invest Dermatol*. 2019;139(4):848–58.
- Navarini AA, Valeyrie-Allanore L, Setta-Kaffetzis N, Barker JN, Capon F, Creamer D, et al. Rare variations in IL36RN in severe adverse drug reactions manifesting as acute generalized exanthematous pustulosis. *J Invest Dermatol*. 2013;133(7):1904–7.
- Barbaud A, Collet E, Milpied B, Assier H, Staumont D, Avenel-Audran M, et al. A multicentre study to determine the value and safety of drug patch tests for the three main classes of severe cutaneous adverse drug reactions. *Br J Dermatol*. 2013;168(3):555–62.
- Barbaud A, Castagna J, Soria A. Skin tests in the work-up of cutaneous adverse drug reactions: a review and update. *Contact Dermatitis*. 2022;86(5):344–56.

30. Weir C, Li J, Fulton R, Fernando SL. Development and initial validation of a modified lymphocyte transformation test (LTT) assay in patients with DRESS and AGEP. *Allergy Asthma Clin Immunol*. 2022;18(1):90.
31. Ingen-Housz-Oro S, Hotz C, Valeyrie-Allanore L, Sbidian E, Hemery F, Chosidow O, et al. Acute generalized exanthematous pustulosis: a retrospective audit of practice between 1994 and 2011 at a single centre. *Br J Dermatol*. 2015;172(5):1455–7.
32. Oh DAQ, Yeo YW, Choo KJL, Pang SM, Oh CC, Lee HY. Acute generalized exanthematous pustulosis: epidemiology, clinical course, and treatment outcomes of patients treated in an Asian Academic Medical Center. *JAAD Int*. 2021;3:1–6.
33. Yanes D, Nguyen E, Imadojemu S, Kroshinsky D. Cyclosporine for treatment of acute generalized exanthematous pustulosis: a retrospective analysis. *J Am Acad Dermatol*. 2020;83(1):263–5.
34. Ortonne N. Histopathology of cutaneous drug reactions. *Ann Pathol*. 2018;38(1):7–19.
35. Brüggem MC, Le ST, Walsh S, Toussi A, de Prost N, Ranki A, et al. Supportive care in the acute phase of Stevens-Johnson syndrome and toxic epidermal necrolysis: an international, multidisciplinary Delphi-based consensus. *Br J Dermatol*. 2021;185(3):616–26.
36. Brajon D, Menetre S, Waton J, Poreaux C, Barbaud A. Non-irritant concentrations and amounts of active ingredient in drug patch tests. *Contact Dermatitis*. 2014;71(3):170–5.
37. Desroche T, Poreaux C, Waton J, Schmutz JL, Menetre S, Barbaud A. Can we allow a further intake of drugs poorly suspected as responsible in drug reaction with eosinophilia and systemic symptoms (DRESS)? A study of practice. *Clin Exp Allergy*. 2019;49(6):924–8.

How to cite this article: Tetart F, Walsh S, Milpied B, Gaspar K, Vorobyev A, Tiplica GS, et al. Acute generalized exanthematous pustulosis: European expert consensus for diagnosis and management. *J Eur Acad Dermatol Venereol*. 2024;38:2073–2081. <https://doi.org/10.1111/jdv.20232>