Scientific African 12 (2021) e00815

Contents lists available at ScienceDirect

Scientific African

journal homepage: www.elsevier.com/locate/sciaf

Coenzyme Q10 Ameliorates potassium cyanide-induced toxicosis in a mouse model

Francis Gitonga[a], Kipchumba Biwott[a], Grace Wairimu Gitau[a], Okanya Patrick Wafula[a], Peris Amwayi[a], Alfred Orina Isaac[b], James Nyabuga Nyariki[a,*]

[a] Department of Biochemistry and Biotechnology, Technical University of Kenya, P. O. Box 52428, 00200, Nairobi, Kenya
[b] Department of Pharmaceutical Technology, School of Health Sciences and Technology, Technical University of Kenya, P. O. Box 52428, 00200, Nairobi, Kenya

ARTICLE INFO

Article history:
Received 10 December 2020
Revised 29 May 2021
Accepted 4 June 2021

Editor: Dr. B. Gyampoh

Keywords:
Potassium cyanide
Coenzyme Q10
Toxicosis
Oxidative stress
Inflammation

ABSTRACT

Potassium cyanide (KCN) is one of the most lethal and feared poison; which devastates cellular respiration resulting in death due to hypoxia. Several antidotes exist, but most face major limitations of safety and efficacy. Moreover, there is a need for new strategies to minimize post-exposure pathological sequel, which includes harmful oxidant and inflammatory changes. Coenzyme Q10 (CoQ10) is a powerful antioxidant, which has shown efficacy against chemical-induced toxicity. In the present study, the potential protective effect of CoQ10 against KCN-induced toxicosis was evaluated. Female Swiss white mice (3–4 weeks old) were divided into three treatment groups. The first group was used as the control, the second group was supplemented with 200 mg/kg of CoQ10 for one month before administration with 8 mg/kg of KCN. For this group, co-administration of CoQ10 and KCN was continued to the end of the experiment. The third group was administered 8 mg/kg of KCN. The experiment was terminated after 42 days post-treatment to enable investigations into the effect of KCN and CoQ10 on various physiological, biochemical, and cellular processes. The results of this study showed that KCN severely impaired the health of mice, more so, the neurological integrity. KCN-driven depletion of cellular glutathione (GSH) was noted in the liver and brain. This constitutes a characteristic impairment of the antioxidant capacity due to the induction of severe oxidative stress. CoQ10 significantly reinforced the neurological integrity and restored cellular glutathione (reduced form) in both the liver and brain, a clear indication of reduced oxidative stress. Remarkably, KCN-induced anemia, leukocytosis, and suppression of platelets were reversed by CoQ10 supplementation. Moreover, histopathological analysis revealed that CoQ10 supplementation blocked KCN-driven liver, kidney, and brain inflammation, and characteristic hypoxia-induced lesions. These findings open possibilities for further scrutiny and development of adjunct therapy utilizing CoQ10 to treat KCN poisoning.

© 2021 The Author(s). Published by Elsevier B.V. on behalf of African Institute of Mathematical Sciences / Next Einstein Initiative.
This is an open access article under the CC BY-NC-ND license (http://creativecommons.org/licenses/by-nc-nd/4.0/)

* Corresponding author.
E-mail address: nyabukaj@tukenya.ac.ke (J.N. Nyariki).

https://doi.org/10.1016/j.sciaf.2021.e00815
2468-2276/© 2021 The Author(s). Published by Elsevier B.V. on behalf of African Institute of Mathematical Sciences / Next Einstein Initiative. This is an open access article under the CC BY-NC-ND license (http://creativecommons.org/licenses/by-nc-nd/4.0/)

Introduction

Potassium cyanide (KCN) is a toxic chemical substance and a potent inhibitor of cellular respiration acting on the mitochondrial cytochrome C oxidase, essentially blocking oxidative phosphorylation. This prevents the body from oxidizing nutrients to produce useful energy. Subsequently, lactic acidosis occurs as a consequence of anaerobic metabolism. In the stomach, KCN reacts with hydrochloric acid (HCl) to form hydrogen cyanide, the most poisonous form of cyanide [1]. Early symptoms of acute cyanide poisoning include headache, dizziness, fast heart rate, shortness of breath, vomiting, and a red or ruddy complexion in the victim due to lack of oxygen in tissues followed by seizures, slow heart rate, loss of consciousness, and eventually brain death within a few minutes of ingestion/inhalation. Note that KCN is a potent poison, which historically has been associated with crime and murder.

Current antidotes used against cyanide poisoning have drawbacks with little possibility of achieving maximal attenuation effect. The usefulness of hydroxocobalamin in exerting its effects when given intravenously is well recognized [2]. Sodium thiosulfate is a slow-acting antidote that is usually administered intravenously [3]. Other antidotes used against cyanide poisoning such as nitrites and dicobalt edetate which are administered intravenously have serious safety issues [3]. Recent studies have demonstrated that isosorbide dinitrate is the only effective antidote against lethal cyanide poisoning in rabbits [4]. Although various antidotes are being developed against cyanide poisoning, their effectiveness is still limited since most are not able or poorly penetrate the blood-brain barrier [5].

Cyanide toxicosis is associated with oxidative stress which is responsible for the exacerbation of the pathophysiology in the central nervous system [6]. Oxidative stress occurs during the generation of excess free radicals with subsequent peroxidation of membranes which overwhelm the antioxidant system in the body. Based on these facts, it is imperative to say that the central nervous system (CNS) is always at a greater vulnerability during KCN induced-hypoxia or toxicity, thus rendering neurons more susceptible to reactive oxygen species (ROS) than any other brain cells. Previous studies have implicated ROS as one of those factors that contribute to neuronal cell injury due to hypoxia [7]. Specifically, ROS depletes a very important cellular antioxidant defence molecule known as glutathione (GSH) which plays a vital role in defending the host against damaging effects of ROS and oxidative stress that could contribute to severe hypoxia and inflammation observed during cyanide poisoning [8,9]. Due to the failure of endogenous antioxidants to reduce cyanide induced oxidative stress, supplementation with potent antioxidant and anti-inflammatory properties have been evaluated. Recent studies have established that administration of aqueous garlic extract, sodium nitrite, and sodium thiosulfate was able to reduce the degree of inflammation associated with cyanide poisoning [4,10]. Additionally, α-ketoglutarate and N-acetylcysteine protects rats against cyanide induced oxidative stress [11,12].

Coenzyme Q10 (CoQ10) or Ubiquinone is another potent endogenous highly lipophilic antioxidant in the mitochondrial electron transport chain that regulates cytoplasmic redox potential for oxidative phosphorylation. As an obligatory coenzyme in the respiratory transport chain, it is essential for the generation of adenosine triphosphate (ATP); and hence is particularly important in cells with high metabolic demand such as the brain. CoQ10 has high bioavailability and the ability to traverse the blood-brain barrier [13]. It also scavenges ROS both in the blood circulation and CNS. The reduced form of CoQ10, ubiquinol, prevents the initiation and propagation of lipid peroxidation in plasma lipoproteins and membrane proteins; and is oxidized to ubiquinone in the process [14]. A study by Stocker et al. [15] showed that CoQ10 protects LDL-cholesterol more efficiently against lipid peroxidation than Vitamin E. It has been shown that CoQ10, can also inhibit lipid peroxidation in mitochondria [16], protein, and DNA oxidation [17,18]. After its anti-oxidative action, ubiquinone can be recycled to its active, reduced ubiquinol form via the mitochondrial Q cycle. Furthermore, respiratory failure and consequently severe deletion of ATP is central to KCN-driven toxicity and death. Moreover, CoQ10 is a potent antioxidant capable of recycling and regenerating other antioxidants such as α-tocopherol and ascorbate [19]. It is therefore highly probable that a molecule that boosts respiration and ATP production such as CoQ10 may ameliorate and potentially aid recovery from KCN-induced toxicosis.

The present study sought to evaluate the protective effects of CoQ10 against cyanide induced toxicosis. The choice of CoQ10 heavily relied upon cumulative interest in the potential usefulness of this compound in the treatment of heavy metal toxicities, neurodegenerative diseases such as Parkinson's disease, Alzheimer's disease, Huntington's disease, and amyotrophic lateral sclerosis [20].

Methods

Ethical statement and mice

This study utilized 3–4 weeks-old female Swiss white mice that were purchased from the Kenya Medical Research Institute (KEMRI). Approval of all experimental procedures and protocols involving mice was obtained from the Institute of Primate Research (IPR) Nairobi Kenya, a local regulatory agency (ISERC/08/2017). The mice were maintained on mice pellets and water *ad libitum* at room temperature. Wood-chippings were provided as bedding material.

Experimental design

The mice were randomly divided into three treatment groups each consisting of ten mice. Experimental group one was the wild type control group (WT), experimental group two: (WT + Coenzyme Q_{10} + KCN), and experimental group three:

(Wild type + KCN). Oral administration of 200 mg/kg of Coenzyme Q_{10} for experimental group two was done daily for one month before oral administration of 8 mg/kg of KCN. Administration of Coenzyme Q_{10} was done using a gavage needle. 200 mg/kg of CoQ_{10} powder was prepared by directly dissolving it in olive oil while KCN was administered in a dosage of 8 mg/kg based on the previous study by Hawk et al. [21]. The choice of the 200 mg/kg dosage was informed by the previous findings that this dosage is sufficient to cross the blood-brain barrier and offer neuroprotection, oxidative stress, and inflammation [13]. The solutions were prepared immediately before use and were protected from light before administration to the animals. The experiment was terminated at day 42 post-treatment and the mice were anesthetized with ketamine to obtain kidney, liver, and brain samples. These samples were used to assay for the reduced form GSH. Besides the samples were also used for biochemical and histopathology tests. Snap-frozen whole brains and liver were homogenized on ice water (4 ℃) in 0.5 ml of 0.25 M sucrose, 5 mM Hepes-Tris, pH 7.4, with protease inhibitor cocktail to a final concentration of 10%. The homogenates were aliquoted into 0.5 ml cryovial tubes and stored in liquid nitrogen for further analyses.

Determination of weight

The body weight of each mouse was done after 2 days while kidney, liver, and brain sample organs were determined at the end of the experiment. All the measurements were done using an analytical electronic balance (Mettler PM34, DoltaRange®).

Determination of developmental and neurological integrity

A Rapid Murine Coma and Behavioural Scale (RMCBS) that comprised 10 parameters to assess the level of neuropathological injury was utilized to determine the extent of neural impairment, especially in motor and cognition systems [22]. The 10 parameters used to score a single mouse were: gait and balance for coordination; motor performance, body position and limb strength for reflexes exploratory behavior; and touch escape, pinna reflex, toe pinch, aggression, and grooming for self - preservation. Each mouse was assessed within 3 min or less to follow the onset of clinical syndrome leading to accurate labelling of the mice as symptomatic, with a high degree of confidence of underlying pathology, consequently providing a narrow window during which rescue and neuroprotection due to CoQ10 supplementation could be assessed. Each mouse was scored from 0 as the lowest to 2 as the highest with a maximum possible score of 20.

Assessment of oxidative stress

Glutathione (GSH) assay was used to evaluate the potential of CoQ10 in protecting mice against KCN induced oxidative stress. This assay was performed as described by Rahman, et al. (2007) with slight modifications. Volumes of 50 µl of brain and liver homogenates were mixed with 50 µl solution containing sulphosalicylic acid (5% w/v) and 0.25 mM ethylenediaminetetraacetic acid (EDTA) and the mixture centrifuged at 8000 x g for 10 min at 4 °C. A volume of 200 µmol/l of GSH standard solution was prepared in 0.5% sulphosalicylic acid (SSA) serial dilutions made using the same solution (0.5% SSA) to final concentrations of 100, 50, 25, 12.5, 6.25, 3.13 and 1.56 µmol/l. 5.5′ dithiobis (2-nitrobenzoic acid (DTNB). Ellman's reagent, was prepared by dissolving in 0.1 M potassium phosphate buffer with 5 mM EDTA disodium salt, pH 7.5) (KPE buffer) to a final concentration of 0.6 mg/ml. A volume of 25 µl of each standard was loaded on a 96-well microtitre plate to wells (first two rows) followed by 25 µl of the sample to the remaining wells in triplicate. To each well, 100 µl of freshly prepared DTNB was added and the absorbence measured at 405 nm at intervals of 30 s using a multi-detection microtitre plate reader (R&D Systems, Minneapolis, MN).

Hematology analysis

Blood was either collected directly from the heart (during euthanization) for full haemogram analysis or from the tail for packed cell volume (PCV) determination. Briefly, blood was collected in heparinized capillary tubes which were then sealed with plasticin at one end. The sealed capillaries were centrifuged in a haematocrit centrifuge (Hawksley H England) at 10,000 RPM for five minutes. PCV was read using the micro-haematocrit reader (Thomas Scientific, USA) and expressed as a percentage of the total blood volume. A full haemogram was analysed using an automated Bechman Coulter counter (Bechman, Indianapolis, USA).

Histopathology

Mice were sacrificed at 42 days post-treatment and the kidney, liver, and brain samples were harvested and fixed in 4% formalin. Tissue sectioning was performed by a microtome knife following dehydration with methanol, and then embedded in paraffin after which they were stained with hematoxylin and eosin (H&E). Photographic imaging of specimens was done and gross pathology and histopathology of mice were analyzed.

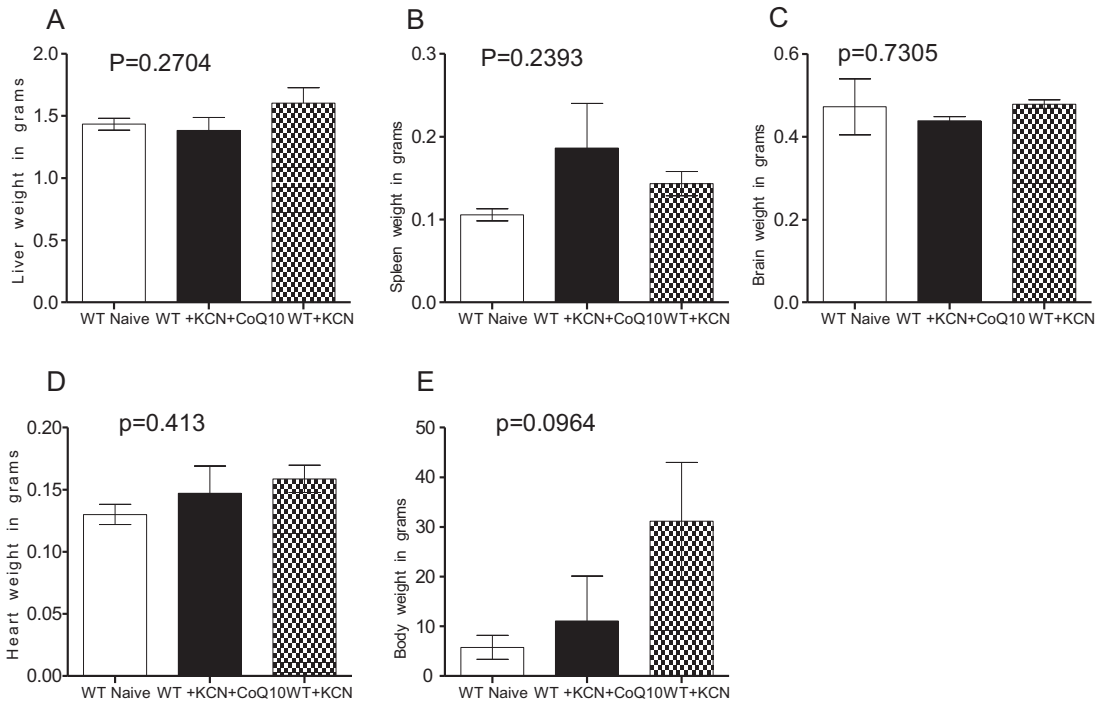

Fig. 1. Change in organ weight from WT naive, WT-CoQ10+KCN, and WT-KCN mice. Representative bar graphs of the liver (A), Brain (B), spleen (C), Heart (D) weight, and the general change in body weight (E). Results are representatives of one independent experiment. Bars represent mean ± SEM. Organ weights were compared by ANOVA, followed by a Bonferroni post-test. $n = 10$ mice per group.

Statistical analysis

One way ANOVA to compare treatment groups with controls Bonferroni's post hoc test was done for internal comparison. Results were given as mean ± with significance set as $p<0.05$. The statistical analyses was done using Graph pad prism software package (version 5.0)

Results

Body and organ weight is not affected by KCN induced toxicosis

Previous studies have shown that exposure to chronic cyanide poisoning leads to the reduction of organ and body weight gain in pigs and rats [23]. The reduction in weight observed in this animal model has been attributed to the depletion of sulphur containing amino acid [24]. In the present study, no significant weight difference was found in spleen, heart, liver, and brain organ in mice treated with KCN and control groups (Fig. 1A-D). Intriguingly, CoQ10 administered mice had pronouncement in the spleen weight probably due to splenomegaly even though not significantly different relative to other treatment groups. Additionally, no significant change in the general body weight was observed (Fig. 1E).

Coenzyme Q10 restored neurological integrity

The most prominent decline in neurological integrity was observed in motor balance, touch escape, aggression, and gait in mice administered with KCN. However, mice administered with CoQ10 showed a significant improvement (Fig. 2A-D). This implies that Coenzyme Q10 administration reinforces the neurological integrity as demonstrated by high RMCBS compared to KCN administered mice (Fig. 2E). This data suggest that oral supplementation of Coenzyme Q10 can reinforce neurological integrity and protect the brain from the lethal deleterious events triggered by KCN.

Restoration of KCN-depleted GSH levels by oral administration of Coenzyme Q10

Glutathione (GSH) is an important cellular antioxidant defence molecule that is involved in defending the host against oxidative stress during cyanide poisoning [9]. Previous studies have implicated ROS as one of the factors that contribute to neuronal impairment and depletion of GSH. With this hypothesis in mind, the levels of reduced GSH was quantified in the brains and liver of the experimental mice. The levels of reduced GSH in the liver and brain were significantly elevated

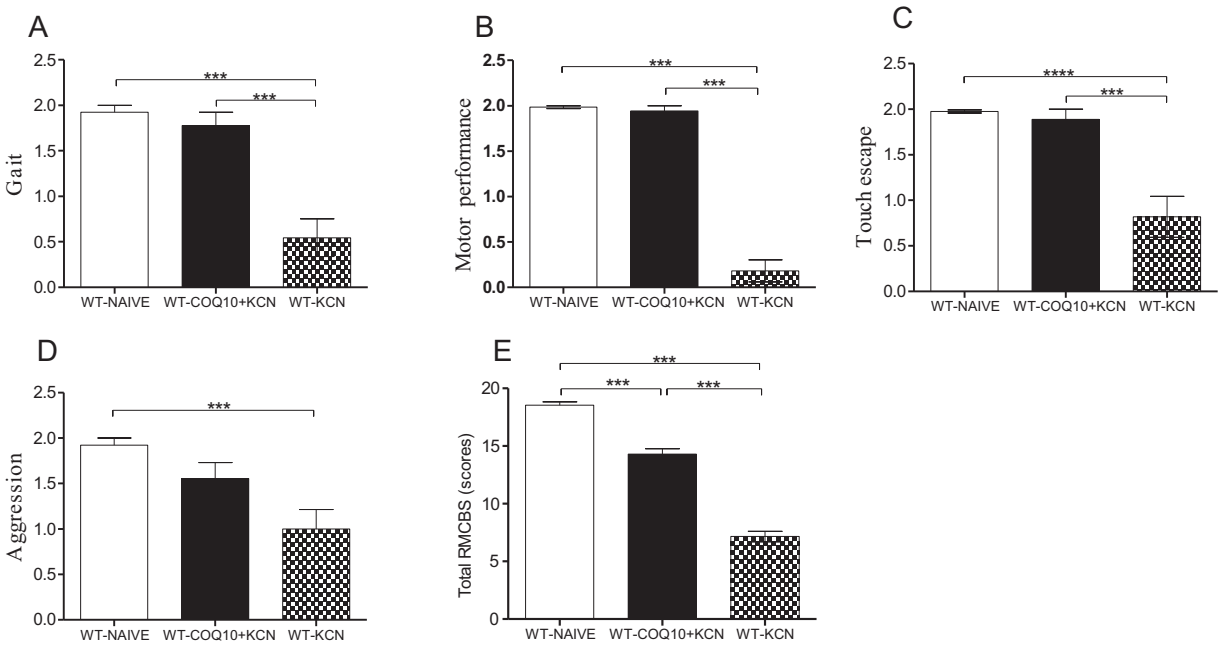

Fig. 2. Oral administration of Coenzyme Q10 reinforces neuronal integrity. The figures shows rapid murine comma and behavior scale parameters; The Gait (A), Motor performance (B), Touch escape (c) Aggression (D) RMCBS score (E) were evaluated. Data sets are presented as the mean of each group ± SEM and are representative of one independent experiment. The parameters and RMCBS score were analyzed by one-way ANOVA, followed by Bonferroni post-test. The asterisk indicates significant differences between the groups indicated by brackets (*** $p \leq 0.001$). $n = 10$ mice per group.

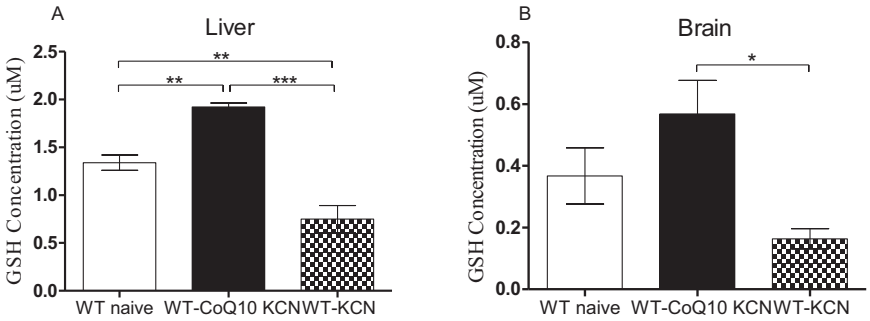

Fig. 3. Glutathione levels in the brain and liver of CoQ10 supplemented and KCN administered mice. The figures shows cellular concentration of glutathione in the liver (A) and Brain (B) from WT naive, WT-CoQ10-KCN, and WT KCN administered groups. One Away ANOVA with Bonferroni multiple comparisons test, (indicated level of significance: $^{*}p \leq 0.05$; $^{**}p \leq 0.01$;$^{***}p \leq 0.001$). $n = 5$ mice per group.

in the group of mice supplemented with coenzyme Q10-KCN in comparison to the group of mice administered with KCN alone (Fig. 3A-B). Therefore, CoQ10 is associated with the enhancement of GSH levels during KCN-induced toxicosis. The restoration and boosting of GSH levels may be an important factor contributing to improved neuroprotection observed in mice administered with CoQ10.

Coenzyme Q10 administration results in the improvement of KCN-induced alteration of haematological profile

Exposure to chronic cyanide toxicity has been demonstrated to have a negative effect on haematological profile resulting in low levels of red blood cells, haemoglobin, and PCV [24,25]. Based on this study, there was a significant difference in the levels of white blood cells (WBC), neutrophils, lymphocytes, monocytes, eosinophils, basophils, red blood cells (RBC), haemoglobin (Hb), packed cell volume (PCV) and platelets in mice administered with Coenzyme Q10 in comparison to KCN administered mice (Fig. 4A-J). Bonferroni's multiple comparison test indicated significantly increased WBC and neutrophils in mice administered with KCN in comparison to Coenzyme Q10 administered mice (Fig. 4A-B). An analysis of lymphocytes depicted no significant change across the groups (Fig. 4C), while significant elevation levels of monocytes and eosinophils amongst KCN administered mice were restored upon Coenzyme Q10 administration (Fig. 4D-E). In addition, the levels of basophils were comparable across all the treatment groups (Fig. 4F). Quite remarkably, Coenzyme Q10 supplementation

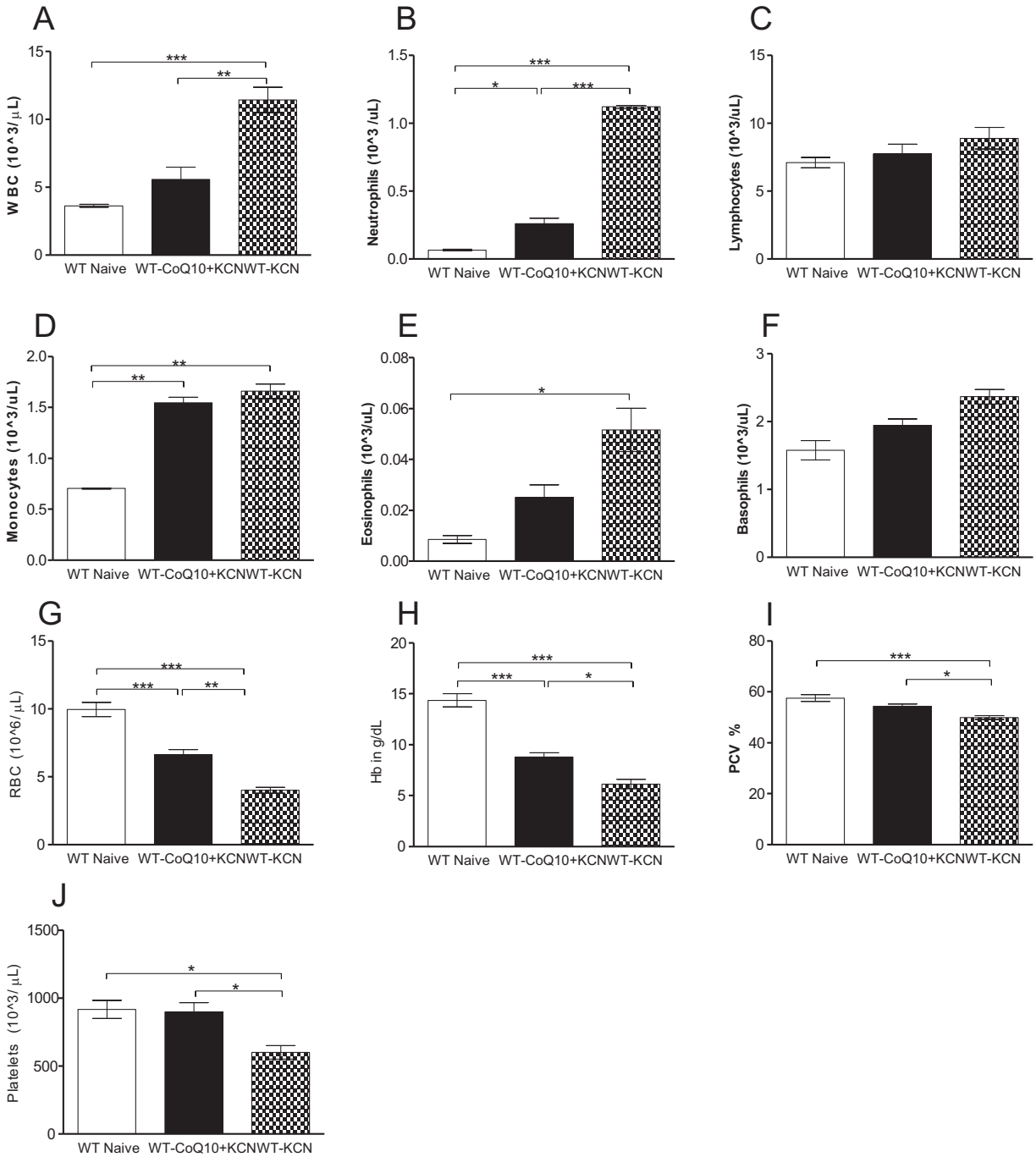

Fig. 4. Alteration of hematological profile in mice following KCN-induced toxicosis.

significantly restored the KCN induced depletion of RBC, Hb, PCV and Platelets levels (Fig. 4G-J), indicating that Coenzyme Q10 is an important antioxidant that appears to protect blood cells during KCN induced toxicosis

The figure shows the effect of Coenzyme Q10 and KCN supplementation on WBC (A), neutrophils (B), lymphocytes (C), monocytes (D), eosinophils (E), basophils (F) RBC (G), Hb (H), PCV (I) and platelets (J). Data sets are presented as the mean of each group ± SEM and are representative of one independent experiment. The hematological parameters were analyzed by one-way ANOVA, followed by Bonferroni post-test. Asterisks indicate significant differences between the groups indicated by brackets (*$p \leq 0.05$; **$p \leq 0.01$;*** $p \leq 0.001$). $n = 10$ mice per group

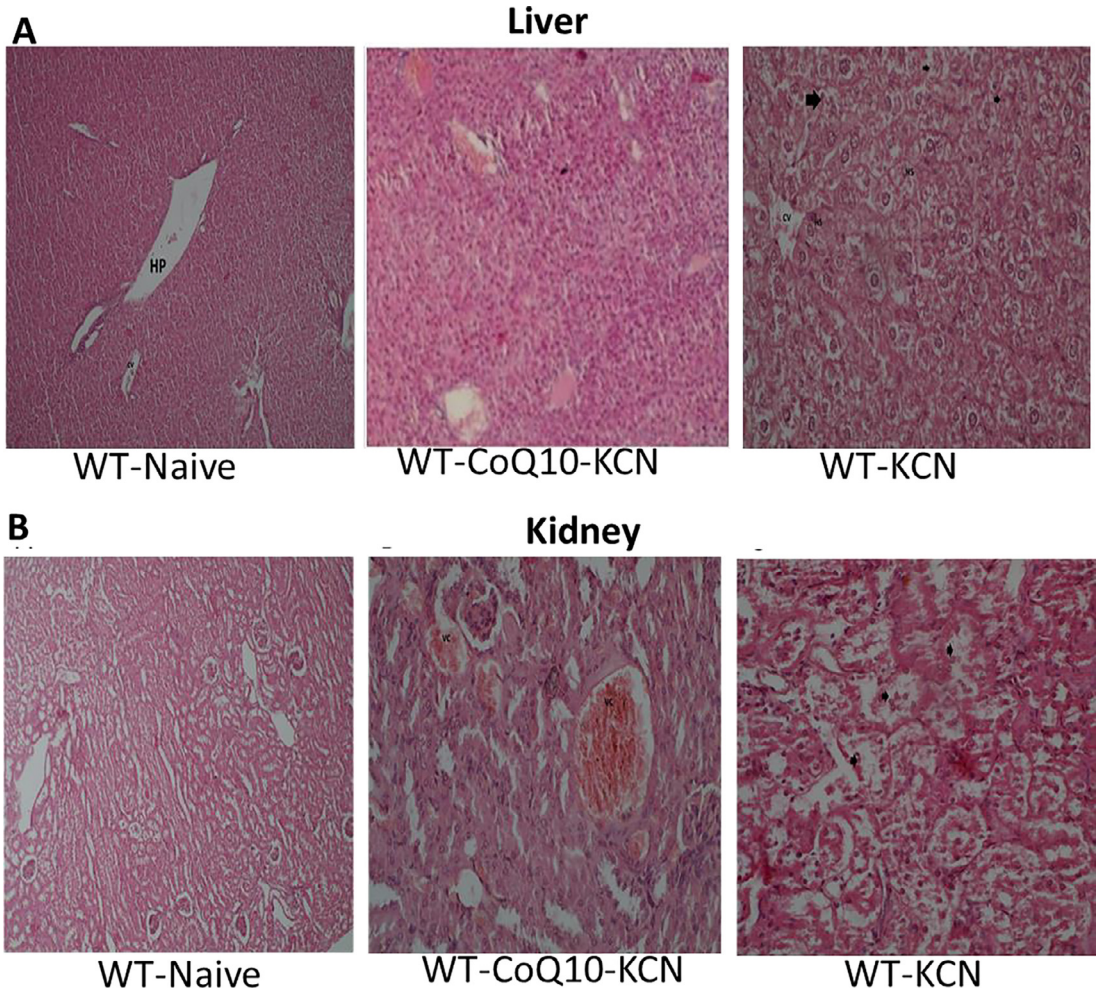

Fig. 5. Mice orally administered with Coenzyme Q10 show mild liver and kidney pathology. (A) Light photomicrograph of liver sections, Magnification: ×100. (B) Light photomicrograph of kidney sections from WT- naïve (Normal control) group; WT-CoQ10-KCN administered, and WT-KCN group of mice administered with 200 mg/kg of CoQ10 and 8.0 mg/kg body weight of KCN respectively. Magnification: ×400, HE.

Coenzyme Q10 supplementation decelerates KCN-induced liver and kidney pathology

The liver is the principal organ in the detoxification process. Therefore, it is more likely to be affected by the toxic effects of most chemical compounds. Histological examination of liver tissue sections from the control group (WT-naïve) revealed normal hepatocytes. Intriguingly, mice orally administered with CoQ10 showed a reduction in KCN-induced liver hepatocyte necrosis (piknosis) and hepatocyte swelling (Fig. 5A).

Cumulative evidence has indicated that potassium cyanide induces inflammation in the kidney which is usually characterized by hemorrhage and congestion. Changes in kidney inflammation for the various treatment groups are presented in Fig. 5B. Notably, Coenzyme Q10 treated mice (WT-COQ10-KCN) showed a more marked reduction in the kidney inflammatory response of tubular epithelium degeneration. Pronounced degeneration of tubular epithelium was observed in KCN-administered mice (Fig. 5B). This finding demonstrates that Coenzyme Q10 supplementation can ameliorate inflammatory lesions in the kidney due to KCN-induced toxicosis

Coenzyme Q10 provided neuroprotection against KCN driven brain inflammation

The central nervous system is known to be the main target for toxicity associated with cyanide poisoning. Results from this study showed that brain sections of the control group of mice had normal brain cellular structure while (Fig. 6A). On the other hand, the neuropathological evidence clearly shows an aggravated inflammation in KCN administered mice, which was characterized by cellular infiltration, reactive gliosis, and perivascular cuffing (Fig. 6C). The observed lesions were mild in Coenzyme Q10 administered mice (Fig. 6B), an indication of neuro-protection of mice against KCN driven brain inflammation.

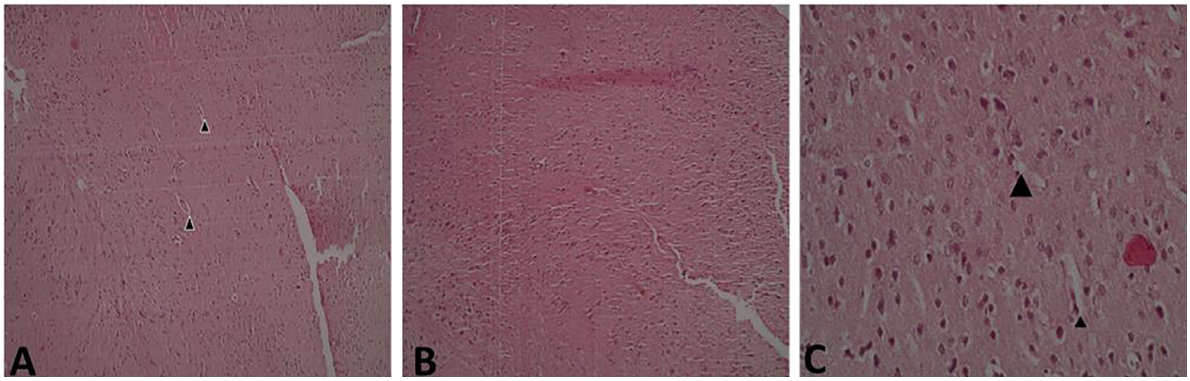

Fig. 6. Coenzyme Q10 administration attenuates KCN-induced neuro-pathology. Light photomicrograph of brain sections: (A) animal from control group; (B) WT-Coenzyme Q10-KCN administered and (C), WT-KCN administered) animals treated with 200 mg/kg of CoQ10 and 8.0 mg/kg body weight of KCN. Magnification: ×100, HE.

Discussion

The findings from the current study, clearly demonstrate the role played by hematological deficits and oxidative stress in KCN toxicosis. More profoundly, the ability of CoQ10 to protect from KCN-driven toxicity. The results on neuropathological injury assessment and the extent of neural impairment, especially in motor and cognition systems, demonstrate resultant rescue of neurological integrity by oral administration of CoQ10 as revealed by RMBCS parameters. This observed phenomenon can be attributed to the ability of Coenzyme Q10 to boost respiration and enhance anti-oxidant neuroprotective effects [22]. Previous studies demonstrated the involvement of cyanide poisoning in the reduction of body and organ weight in pigs, dogs, goats, and rats [24,26]. This reduction is attributed to the lowering of sulphur-containing amino acids, and growth hormone receptors as well as deficient growth hormone secretion and impaired energy metabolism due to inhibition of mitochondrial oxidative phosphorylation [26]. However, note that our findings did not demonstrate any significant reduction in body and organ weight gain across all the treatment groups. Such findings have been reported by other studies [27].

In the present study, GSH levels in the liver and brain tissues of mice administered with KCN were significantly lower than those that received KCN and were supplemented with CoQ10. Restoration and enhancement of GSH levels in mice administered with CoQ10 may be an important factor contributing to improved protection. Cyanide poisoning has been implicated in the acceleration of production of reactive oxygen species, resulting in oxidative stress; which is responsible for the exacerbation of the central nervous system pathophysiology [6]. These intracellular ROS together with many other free radicals have been associated with the acceleration of cellular depletion of GSH, oxidation of thiols to disulphides, and impairment of energy generation leading to cell death [28]. Toxic arsenic compounds interact with GSH forming a stable adduct which results in reversible competitive inhibition of glutathione reductase, an enzyme responsible for maintaining intracellular reduced GSH. As a result, this leads to the conversion of reduced GSH to oxidized glutathione disulphide [29]. GSH reduction has been previously reported in patients and animals of various neurodegenerative disorders such as Parkinson's and Alzheimer's disease [30] and Human African trypanosomiasis [31,32]. This reduction can be attributed to inhibition of glutathione reductase and reduction of protective mechanisms against ROS; hence neuronal cells become susceptible to oxidative stress and ultimate cell death [33]. Other findings indicate the effectiveness of CoQ10 in mitigating β-amyloid toxicity, glutamate excitotoxicity, 3-Nitropropionic acid, and Melarsoprol toxicity [13,32,34,35]. More recent studies have also demonstrated that administration of α-ketoglutarate and N-acetyl cysteine protects against cyanide and other arsenic compounds induced oxidative stress and histological changes [11,12,13].

The underlying mechanism that leads to alteration of the haematological profile due to cyanide toxicity remains unclear. In the present study, there was an elevation of white blood cells (WBC). However, the levels of red blood cells (RBC), haemoglobin, and platelets were dramatically reduced in KCN administration. This is consistent with previous studies in which KCN administration negatively affected the haematological profile [26]. However, there were enhanced RBC concentration levels in CoQ10 administered mice which could be linked to the potent antioxidant activity of CoQ10 against lipid peroxidation on the surface of RBC membranes which are highly polyunsaturated. The antioxidant capability of CoQ10 may have reduced the susceptibility of erythrocytes to membrane oxidative damage, consequently resulting in maintenance of the normal hemoglobin levels. A significant change in red blood cells and hemoglobin concentration is a clear indication of anemia. According to Soto-Blanco et al. [25], the development of anemia in goats receiving KCN was due to hypothyroidism or impairment of the erythropoiesis process by cyanide. In the present study, the absence of anemia in CoQ10 administered mice can, therefore, be associated with the maintenance of thyroidal metabolism. This is in agreement with works by [36] which also demonstrated that the development of anemia during trypanosome infection was blocked by oral administration of 200 mg/kg of Coenzyme Q10. Elevated WBC concentration observed in KCN administered mice in this study was

expected since leukocytosis is well documented in various animal models including goats exposed to KCN [28]. Notably, we observed stabilized WBC levels in mice supplemented with CoQ10. This observation suggests that Coenzyme Q10 has the capacity to immunosuppress KCN-immunostimulatory lymphoproliferative responses since high augmentation of WBC can contribute to organ-specific inflammation.

Mice that were treated with KCN and supplemented with coenzyme Q10 had normal PCV levels relative to KCN-treated mice. Since lipid oxidation is correlated with membrane disintegration and ultimate cell death, then it is possible that KCN-induced toxicosis was potent enough to result in decreased PCV levels [37]. It is plausible that Coenzyme Q10 lowered levels of free radicals in the blood, consequently, shielding the red blood cells membrane against oxidative damage. Moreover, Coenzyme Q10 has been shown to exhibit antiapoptotic effects by activating and increasing the expression of mitochondrial uncoupling proteins [20]. In the current study, CoQ10 may have protected RBCs from KCN-driven induction of programmed cell death. It is reasonable to conclude that the antioxidant capacity of coenzyme Q10 reduced the vulnerability of erythrocytes to membrane oxidative damage due to KCN exposure. This finding may have vital implications in future new strategies dedicated to the treatment and management of KCN toxicities.

Previous studies have demonstrated that chronic cyanide toxicity is associated with the pathophysiology of the liver, kidney, and brain [38]. Several authors have indeed been able to establish that the body's innate antioxidant capacity is highly compromised by cyanide toxicity which ultimately leads to exacerbated kidney and liver inflammation that is characterized by hemorrhage and congestion [38]. Moreover, the central nervous system is known to be the main target for toxicity associated with cyanide. The histopathological evidence from the liver showed an exacerbation of inflammation in the mice administered with KCN. The prominent lesions observed included liver congestion with hepatocyte necrosis (piknosis) and loss of distinct cellular structure; which were attenuated in mice administered with Coenzyme Q10. Moreover, pronounced degeneration of tubular epithelium, accompanied by hemorrhage in the kidney was evident in KCN-administered mice. The observed lesions in the kidney have also been reported previously [38]. In the brain, histological evidence clearly shows an aggravated inflammation in KCN-administered mice, characterized by cellular infiltration, reactive gliosis, and perivascular cuffing. In previous studies, chronic exposure to potassium cyanide induced toxicosis with severe neurological deficits [39]. Neurological seizures linked to disturbances of accommodation and psychosis are hallmarks of KCN toxicity responsible for brain pathology [39]. In animal studies, the lethal concentrations of KCN doses is usually associated with hyperactivity and asphyxial convulsions that lead to sudden death [40]. However, the lesions were mild in mice administered with Coenzyme Q10; with the brain, and kidney showing normal distinct layers. From this study, it can be concluded that Coenzyme Q10 ameliorates KCN-driven inflammation in the liver, kidney and brain.

Conclusion

From this study, it is evident that CoQ10 ameliorates KCN-induced toxicosis. The likelihood of using Coenzyme Q10 in combination with other antidotes for a possible maximum protective effect against KCN poisoning may be an interesting area for further research since the current antidotes against cyanide poisoning have limitations.

Declaration of Competing Interest

The authors declare that they have no conflict of interests that could have influenced the work reported in this paper.

Acknowledgments

The authors are grateful to The World Academy of Sciences for the utilization of reagents supported by this organization. We gratefully acknowledge Paul Okumu (Department of Veterinary Pathology, Microbiology and Parasitology University of Nairobi) for his expertise on histopathological analysis, David Bosire and Kennedy Wekesa (The Technical University of Kenya) for their support with the laboratory work.

Funding

The authors declare that no funding was given for this work.

References

[1] L. Nelson, Acute Cyanide Toxicity: mechanisms and Manifestations, J. Emerg. Nurs. 32 (4) (2006) S8–S11.
[2] J.P. Thompson, T.C. Marrs, Hydroxocobalamin in cyanide poisoning, Clin. Toxicol. 50 (10) (2012) 875–885.
[3] W.S. Borron, J.F. Baud, Antidotes for acute cyanide poisoning, Curr. Pharm. Biotechnol. 13 (10) (2012) 1940–1948.
[4] O. Lavon, Early administration of isosorbide dinitrate improves survival of cyanide-poisoned rabbits, Clin. Toxicol. 53 (1) (2014) 22–27.
[5] R. Bhattacharya, R. Vijayaraghavan, Promising role of a-ketoglutarate in protecting against the lethal effects of cyanide, Hum. Exp. Toxicol. 21 (6) (2002) 297–303.
[6] P.G. Gunasekar, P.W. Sun, A.G. Kanthasamy, J.L. Borowitz, G.E. Isom, Cyanide-induced neurotoxicity involves nitric oxide and reactive oxygen species generation after N-Methyl-D-Aspartate Receptor Activation, J. Pharmacol. Exp. Ther. 277 (1) (1996) 150–155.
[7] N. Okolie, A. Osagie, Differential effects of chronic cyanide intoxication on heart, lung and pancreatic tissues, Food Chem. Toxicol. 38 (6) (2000) 543–548.

[8] S. Heales, Impairment of brain mitochondrial function by reactive nitrogen species: the role of glutathione in dictating susceptibility, Neurochem. Int. 40 (6) (2002) 469–474.
[9] V.V. Dukhande, G.H. Malthankar-Phatak, J.J. Hugus, C.K. Daniels, J.C.K. Lai, Manganese-induced neurotoxicity is differentially enhanced by glutathione depletion in astrocytoma and neuroblastoma cells, Neurochem. Res. 31 (11) (2006) 1349–1357.
[10] A. Muhammad, S.K. Muhammad, A.K. Muhammad, A. Kamran, H. Zahoorul, A.K. Jawaria, A. Nisar, Assessing the efficacy of aqueous garlic extract, sodium nitrite and sodium thiosulfate against prolonged oral cyanide exposure in Rabbits, Pak. J. Pharm. Sci. 31 (2) (2018) 411–419.
[11] R. Bhattacharya, R.M. Satpute, J. Hariharakrishnan, H. Tripathi, P.B. Saxena, Acute toxicity of some synthetic cyanogens in rats and their response to oral treatment with alpha-ketoglutarate, Food Chem. Toxicol. 47 (9) (2009) 2314–2320.
[12] R. Bhattacharya, P. Rao, P. Singh, S.K. Yadav, P. Upadhyay, S. Malla, N.L. Gujar, V. Lomash, S.C. Pant, Biochemical, oxidative and histological changes caused by sub-acute oral exposure of some synthetic cyanogens in rats: ameliorative effect of α-ketoglutarate, Food Chem. Toxicol. 67 (2014) 201–211.
[13] R.T. Matthews, L. Yang, S. Browne, M. Baik, M.F. Beal, Coenzyme Q10 administration increases brain mitochondrial concentrations and exerts neuroprotective effects, Proc. Natl. Acad. Sci. 95 (15) (1998) 8892–8897.
[14] S. Pepe, S.F. Marasco, S.J. Haas, F.L. Sheeran, H. Krum, F.L. Rosenfeldt, Coenzyme Q10 in cardiovascular disease, MitochondrionMitochondrion 7 (2007) S154–S167.
[15] R. Stocker, V.W. Bowry, B. Frei, Ubiquinol-10 protects human low density lipoprotein more efficiently against lipid peroxidation than does alpha-tocopherol, Proc. Natl. Acad. Sci. 88 (5) (1991) 1646–1650.
[16] M. Glinn, C. Lee, L. Ernster, Pro- and anti-oxidant activities of the mitochondrial respiratory chain: factors influencing NAD(P)H-induced lipid peroxidation, Biochimica et Biophysica Acta (BBA) - Bioenergetics 1318 (1–2) (1997) 246–254.
[17] A. Ernst, A. Stolzing, G. Sandig, T. Grune, Antioxidants effectively prevent oxidation-induced protein damage in OLN 93 cells, Arch. Biochem. Biophys. 421 (1) (2004) 54–60.
[18] M. Tomasetti, G. Littarru, R. Stocker, R. Alleva, Coenzyme Q10 enrichment decreases oxidative DNA damage in human lymphocytes, Free Radic. Biol. Med. 27 (9–10) (1999) 1027–1032.
[19] R.S. Sohal, Coenzyme Q and Vitamin E Interactions, Meth. Enzymol. (2004) 146–151.
[20] C. Henchcliffe, Coenzyme Q10 effects in neurodegenerative disease, Neuropsychiatr. Dis. Treat. 597 (2009).
[21] M.A. Hawk, G.D. Ritchie, K.A. Henderson, K.A.B. Knostman, B.M. Roche, Z.J. Ma, J.W. Edward, P.J. Sabourin, Neurobehavioral and cardiovascular effects of potassium cyanide administered orally to Mice, Int. J. Toxicol. 35 (5) (2016) 604–615.
[22] R.W. Carroll, M.S. Wainwright, K.Y. Kim, T. Kidambi, N.D. Gómez, T. Taylor, K. Haldar, A rapid murine coma and behavior scale for quantitative assessment of murine cerebral Malaria, PLoS ONE 5 (10) (2010) e13124.
[23] C.F.I. Onwuka, A.O. Akinsoyinu, O.O. Tewe, Role of sulphur in cyanide detoxification in ruminants, Small Rumin. Res. 8 (4) (1992) 277–284.
[24] B. Soto-Blanco, S.L. Górniak, E.T. Kimura, Vet. Res. Commun. 25 (5) (2001) 379–389.
[25] m. Avais, M.S. Khan, M.A. Khan, M. Ashraf, J.A. Khan, S. Hameed, Prolonged oral cyanide effects on feed intake, growth rate and blood parameters in Rabbits, Pak. J. Pharm. Sci. 27 (4) (2014) 773–777.
[26] A.B. Sousa, B. Soto-Blanco, J.L. Guerra, E.T. Kimura, S.L. Górniak, Does prolonged oral exposure to cyanide promote hepatotoxicity and nephrotoxicity? ToxicologyToxicology 174 (2) (2002) 87–95.
[27] B. Soto-Blanco, B.L. Stegelmeier, J.A. Pfister, D.R. Gardner, K.E. Panter, Comparative effects of prolonged administration of cyanide, thiocyanate and chokecherry (Prunus virginiana) to goats, J. Appl. Toxicol. 28 (3) (2008) 356–363.
[28] D.V. Parke, The Cytochromes P450 and mechanisms of chemical carcinogenesis, Environ. Health Perspect. 102 (10) (1994) 852–853.
[29] M.L. Cunningham, M.J.J.M. Zvelebil, A.H. Fairlamb, Mechanism of inhibition of trypanothione reductase and glutathione reductase by trivalent organic arsenicals, Eur. J. Biochem. 221 (1) (1994) 285–295.
[30] R.M. Solano, M.J. Casarejos, J. Menendez-Cuervo, J.A. Rodriguez-Navarro, J. Garcia de Yebenes, M.A. Mena, Glial Dysfunction in Parkin Null Mice: effects of Aging, J. Neurosci. 28 (3) (2008) 598–611.
[31] K. Rashid, F.N. Wachira, J.N. Nyabuga, B. Wanyonyi, G. Murilla, A.O. Isaac, Kenyan purple tea anthocyanins ability to cross the blood brain barrier and reinforce brain antioxidant capacity in mice, Nutr. Neurosci. 17 (4) (2013) 178–185.
[32] J.N. Nyariki, J.K. Thuita, A.M. Wambugu, N.O. Nyamweya, K. Rashid, G.K. Nyambati, A.O. Isaac, Coenzyme Q10 and endogenous antioxidants neuro-protect mice brain against deleterious effects of Melarsoprol and Trypanasoma Brucei Rhodesiense, J. Nat. Sci. Res. 8 (4) (2018) 61–73.
[33] W. Dauer, S. Przedborski, Parkinson's Dis. Neuron 39 (6) (2003) 889–909.
[34] A. Favit, F. Nicoletti, U. Scapagnini, P.L. Canonico, Ubiquinone protects cultured neurons against spontaneous and Excitotoxin-induced degeneration, J. Cereb. Blood Flow Metab. 12 (4) (1992) 638–645.
[35] S. McCarthy, M. Somayajulu, M. Sikorska, H. Borowy-Borowski, S. Pandey, Paraquat induces oxidative stress and neuronal cell death; neuroprotection by water-soluble Coenzyme Q10, Toxicol. Appl. Pharmacol. 201 (1) (2004) 21–31.
[36] J.N. Nyariki, L.A. Ochola, N.E. Jillani, N.O. Nyamweya, P.E. Amwayi, D.S. Yole, L. Azonvide, A.O. Isaac, Oral administration of Coenzyme Q10 protects mice against oxidative stress and neuro-inflammation during experimental cerebral malaria, Parasitol. Int. 71 (2019) 106–120.
[37] S.V. Avery, Molecular targets of oxidative stress, Biochem. J. 434 (2) (2011) 201–210.
[38] P.J. Sabourin, C.L. Kobs, S.T. Gibbs, P. Hong, C.M. Matthews, K.M. Patton, C.L. Sabourin, E.J. Wakayama, Characterization of a mouse model of oral potassium cyanide intoxication, Int. J. Toxicol. 35 (5) (2016) 584–603.
[39] L. Zhu, Y.J. Xu, F. Du, Z.M. Qian, Ginkgolides protect primary cortical neurons from potassium cyanide-induced hypoxic injury, Exp. Brain Res. 179 (4) (2007) 665–671.
[40] S. Chmieliauskas, E. Mundinas, D. Fomin, G. Andriuskeviciute, S. Laima, E. Jurolaic, J. Stasiuniene, A. Jasulaitis, Sudden deaths from positional asphyxia, Medicine (Baltimore).Medicine (Baltimore) 97 (24) (2018) e11041.