Journal of Oral Biology and Craniofacial Research 14 (2024) 326–334

Contents lists available at ScienceDirect

Journal of Oral Biology and Craniofacial Research

journal homepage: www.elsevier.com/locate/jobcr

Effects of polymethyl methacrylate-based bone cement graft for treating excessive gingival display and its dimensional facial changes: 12-Month clinical study

Valéria Martins de Araújo Carneiro [a], Mayra Pereira Roquete [a], Andressa Meireles Seabra Gomes [a], Mônica Umpierre Marinho [a], Gabriel Simino de Melo [b], Feras Kasabji [c], Tien-Li An [a], Dircilei Nascimento de Sousa [a], João Marcelo Meireles Rodrigues [a], Cristine Miron Stefani [a], Maria do Carmo Machado Guimarães [a], Ana Clara Rodrigues Ribeiro [d], Carlos Alexandre Soares Andrade [c,*]

[a] Faculdade de Ciências da Saúde, Departamento de Odontologia, Universidade de Brasília - Campus Universitário Darcy Ribeiro, Asa Norte, Brasília, DF, 70910-900, Brazil

[b] Faculdade de Medicina e Odontologia, Departamento de Periodontia, Faculdade São Leopoldo Mandic, Rua Dr. José Rocha Junqueira 13, Campinas, SP, 13045-755, Brazil

[c] Faculty of Medicine, Department of Public Health and Epidemiology, University of Debrecen, Kassai Út 26, Debrecen, Hajdú-Bihar, H-4028, Hungary

[d] Departamento de Odontologia, Universidade Católica de Brasília – Campus Taguatinga Sul, Taguatinga, Brasília, DF, 71966-700, Brazil

ARTICLE INFO

Keywords:
Polymethyl methacrylate
Lip
Crown lengthening
Gingiva
Smiling
Mouth mucosa

ABSTRACT

Objective: to present a 12-month follow-up with photographic and tomographic analyses of the effect of polymethyl methacrylate-based bone cement graft (PMMA) in gingival exposure (GE) in patients with excessive gingival display (EGD).

Methods: Twelve patients with EGD were included. The PMMA was surgically placed. A frontal and lateral photograph protocol was performed at baseline (T_0), 3 (T_3), 6 (T_6), and 12 months (T_{12}) post-operatively. Soft tissue cone-beam computed tomography (ST-CBCT) was performed at T_0 and T_{12}. Measures included GE, length of the lip vermilion (LLV), lip shape (LS), nose width (NW), filter width (FW), nasolabial angle (NAS) while smiling, and nasolabial angle at rest (NAR). The height, thickness, and volume of the cement graft were also measured in the ST-CBCT. The comparisons were performed by Kruskal-Wallis test at 5 % of significance ($p < 0.05$).

Results: The height, thickness, and volume of the PMMA were respectively 12.84 ± 1.59 mm, 3.83 ± 0.53, and 1532.02 ± 532.52 mm^3. PMMA significantly decreased GE from 8.33 ± 1.25 mm (T_0) to 6.60 ± 0.93 mm (T_{12}) ($p < 0.01$). NAR was 98.34 ± 9.28° at T_0 and increased to 105.13 ± 7.33° at T_{12}; however, the angle value was not statistically different ($p = 0.08$). LLV, LS, NW, FW, and NAS did not exhibit statistical differences between the baseline and follow-up periods.

Conclusions: PMMA significantly decreased GE in a 12-month follow-up without influencing adjacent soft tissue anatomical structures.

1. Introduction

Excessive gingival display (EGD), more commonly known as "gummy smile," is a non-pathological condition where the gingiva is exposed more than 3 mm during the smile.[1,2] EGD prevalence is about 7 % among male and 14 % female population, and it affects mostly people from 20 to 30 years old.[3] It is a multifactorial condition with etiological factors of four possible origins: dentoalveolar, skeletal, muscular, and gingival.[4–7] Some of these are more prevalent than others, such as EGD caused by altered passive eruption (APE) associated with a hypermobile upper lip in patients with maxillary subnasal depression.[8] Those clinical conditions originate from gingival, muscular, and skeletal etiologies,

* Corresponding author.
E-mail address: soares.andrade@med.unideb.hu (C.A. Soares Andrade).

https://doi.org/10.1016/j.jobcr.2024.04.007
Received 13 December 2023; Received in revised form 3 April 2024; Accepted 13 April 2024
Available online 20 April 2024
2212-4268/© 2024 The Authors. Published by Elsevier B.V. on behalf of Craniofacial Research Foundation. This is an open access article under the CC BY-NC-ND license (http://creativecommons.org/licenses/by-nc-nd/4.0/).

respectively.[8–10] APE is a condition in which the apical migration of the gingival margin during dental eruption fails or is delayed. On the other hand, a hypermobile upper lip is presented when more than 8 mm of the lip retracts during the smile, and it might be occasioned as a result of the presence of maxillary subnasal depression.[11,12] Aesthetic crown lengthening (ACL) surgery alone is not resolutive for cases involving the three etiologies simultaneously.[13]

The polymethyl methacrylate-based bone cement graft (PMMA) is a reconstructive material, highly biocompatible, that has been used in health-related surgeries for more than seven decades, mostly in orthopedics medicine.[14,15] The use of PMMA combined with surgical ACL for EGD treatment was first reported in 2010,[9] with encouraging clinical results in some cases reports.[9,12,16–20] The authors described the surgical procedure as being simple and with satisfactory outcomes since the gingival display was resolved due to diminished upper lip mobility. The function of the PMMA is to fill the depression where the upper lip lodges, which results in less lip contraction during natural smiling.[12,17] However, since the PMMA graft is placed in the anterior process of the maxilla, adjacent anatomical structures may be affected causing facial changes, such as increasing the nasolabial angle and the labial component of the nasolabial angle. Those facial structures may still undergo additional changes or remain stable after the complete healing and stabilization of soft tissues.[11,17] Despite the first report of the technique being published one decade ago, there are no guidelines regarding the proper clinical indications of this technique or information on the PMMA graft size. The decrease of the gingival display has not been quantified, nor how much anatomical aspects of the PMMA graft dimensions influence this factor. Furthermore, the evidence on the gingival display reduction is limited to case reports or longitudinal studies with short follow-ups. Additionally, there is no sufficient evidence reporting the changes in adjacent anatomical structures.

Therefore, the main objective of the present study was to perform a photographic and tomographic assessment of the effect of PMMA grafting associated with surgical ACL in a 12-month follow-up period regarding the amount of gingiva displayed, facial changes, and describe PMMA volume, thickness and height, in patients with EGD caused by APE, hypermobile upper lip, and maxillary subnasal depression.

2. Material and methods

This prospective clinical study was approved by the Research Ethics Committee (CEP) of the Faculty of Health Sciences of the University of Brasília - UnB (CAAE: 88468618.9.0000.0030). The study sample consisted of patients with a complaint of excessive gingival exposure when smiling who sought the graduate specialty course in Periodontics at the University of Brasília - UnB clinics between January 2017 and December 2018. Participants were referred from the undergraduate dentistry clinic of the University of Brasília, the center of specialties of the School Hospital of Brasília, or private practices. To participate in the research, patients signed an Informed Consent Form and received detailed verbal and written information before starting any analysis. Authorization was requested to use images illustrating the research methods. Only patients who signed this term had their photos shared. All interested patients underwent detailed screening to assess their eligibility for the surgery. A clinical examination was conducted to determine periodontal health. The complementary examinations included a photographic protocol, in which standardized pictures were taken from the patients for subsequential analysis: (1) frontal facial while smiling, (2) frontal facial at rest, (3) lateral facial while smiling, (4) lateral facial at rest, (5) intra-oral while smiling, and (6) intra-oral at rest. Also, all eligible participants undertook soft tissue cone-beam computed tomography (ST-CBCT) to investigate gingival, dental, and skeletal etiologies.

The following inclusion criteria were considered: 1) being over 18 years old; 2) visible gingival plaque index less than or equal to 10 %; 3) gingival bleeding rate less than or equal to 10 %[21]; 4) not being under orthodontic treatment; 5) no history of periodontitis or attachment loss; 6) no history of tooth loss; 7) absence of diastema; 8) short clinical crown on anterior maxillary teeth due to APE; 9) clinically diagnosed and tomographically confirmed maxillary subnasal depression; 10) upper lip mobility greater than 8 mm while smiling.[8] Individuals were excluded if they met any of the following conditions: 1) active smokers; 2) those with systemic contraindications for oral surgery; 3) patients currently using medications linked to gingival hyperplasia; 4) individuals with prosthetic rehabilitation in any anterior maxillary teeth; 5) those who had undergone a prior surgical procedure in the same region; 6) participants with insufficient keratinized gingiva; and 7) pregnant or lactating women.

Twenty-one days before surgery, all participants underwent prophylaxis, dental scaling, and root planing in both arches. In the same session, they received oral hygiene instructions. Two days before surgery, participants were clinically examined to confirm adequate plaque control and the absence of gingivitis. All the surgeries were performed by graduate students from the specialty course in Periodontics of UnB under experienced specialists' supervision. Surgery started with local anesthesia, in which the anterior and middle superior alveolar and nasopalatine nerves were blocked; also, supraperiosteal infiltration was done. The desired teeth height was marked with the Castroviejo caliper at the zenith of each tooth from the left first molar to the right first molar. An internal beveled incision was done with a 15C scalpel blade, and an intrasulcular incision was made before removing the demarcated gingival collar. A vestibular total flap was lifted until it reached the anterior nasal spine. Osteoplasty was performed using high-rotation spherical drills 3018 and 1016 under saline irrigation. At osteotomy, the distance from the cement-enamel junction to the bone crest was left at an average of 2 mm. After the traditional steps of surgical ACL were completed,[22] the PMMA (Aminofix 3, Groupe Lepine, France) was prepared accordingly with the producer's instructions. After mixing the liquid and the powder in the correct proportions, during the plastic phase, the cement graft was placed in the maxillary subnasal depression so it could copy the area. To mitigate the potential risk of thermal damage to the underlying bone due to the exothermic reaction of the PMMA, an irrigation process was implemented by consistently cooling the PMMA with cold saline solution until complete polymerization. Sterile 50 ml syringes were filled with cold saline solution, and continuous irrigation was employed to ensure constant contact between the saline solution and the entire surface of the PMMA. After the cure of PMMA was completed, the graft was refined and placed in the anatomical depression. The volume, thickness, and height of the PMMA graft were established according to the specific anatomical requirements of each case, with the maxillary subnasal depression serving as a guide for determining the volume and shape of the PMMA graft. Two titanium-based bone graft fixation screws were placed between lateral incisors and canines on each side. Subsequently, the flap was sutured into position with a vertical mattress suture using a nylon monofilament polyamide suture 5-0 reverse cutting needle 15 mm 3/8, considering the planned tooth height and the distance between the cement-enamel junction and bone crest (Fig. 1). At the end of the surgery, postoperative instructions were given, and dexamethasone, amoxicillin, and ibuprofen were prescribed to the patient. Patients returned after 14 days for suture removal, plaque control, and oral hygiene instruction, if needed.

2.1. Photographic analysis

One trained and calibrated examiner (CASA) performed the photographic protocol using a professional digital camera, a 100 mm macro lens, and a circular flash. The same protocol was implemented before surgery (T_0), and 3 (T_3), 6 (T_6), and 12 months (T_{12}) post-operatively. The images were analyzed in the ImageJ software (National Institutes of Health, EUA, ImageJ version v1.51j8) by one trained examiner (MPR). Measurements were done twice by the same examiner, with an interval of at least 15 days to assess the intra-examiner agreement. To

Fig. 1. Aesthetic crown lengthening and PMMA-graft placement surgical procedure (1a. Initial clinical case with patient presenting gingival smile, due to altered passive eruption and maxillary subnasal depression. 1b. Gingival collar removed. 1c. Vestibular total flap lifted. 1d. and 1e. Bone view after osteoplasty and osteotomy. 1f. PMMA graft placed and fixed with two titanium-based bone graft fixation screws. 1g. Immediate post-operative after suturing. 1h. Post-operative view after 3 months).

calibrate the software regarding each image, the examiner drew a line from the most distal point of the right central incisor to the most distal point of the left central incisor. This line was converted in millimeters, considering the same clinical measurement done two weeks before the surgery (Fig. 2).

The following measurements of the anatomical structures were then performed (Fig. 3).

a) Length of the lip vermilion while smiling (LLV): measured through 5 lines, the first being in the center of the labial tubercle (C), two lines (right and left side) at the level of the cupid's bow, and, lastly, a line was drawn in the middle of the distance left to the labial commissure (L).
b) Gingival exposure while smiling (GE): a line was drawn from the proximal point of teeth to the lower limit of the upper lip in the region between the left and right canine. Since the gingival margin has changed after ACL, the proximal point was chosen as a fixed point.
c) Lip shape smiling (LS): a fixed horizontal line was drawn starting from one labial commissure, meeting the opposite side commissure. This line was divided into four measurements through 3 vertical lines. The first vertical line in the center of the labial tubercle and the other two lines halfway through the remaining distance on each side of the mouth.
d) Nose width (NW): measured at the widest level of the nose wing.
e) Filter width (FW): a horizontal line was drawn as the filter width measure.
f) Nasolabial angle while smiling (NAS) and at rest (NAR): measured on the lateral photographs where a line was drawn on the inferior border of the nose and another one at the upper lip. The angle formed by the intersection of two lines was recorded at smiling and at rest.

2.2. Tomographic analysis

ST-CBCT scans were performed with an i-CAT tomograph (Imaging Sciences International, Inc., Hatfield, PA, USA) two weeks before and 12 months after the surgery. Patients were seated, with their chin and head stabilized. Lip retractors, also known as "spandex," were used by every participant so it would be possible to visualize gingival structures.[23] A jaw shot was made (dimensions 6 × 17cm) for 40s with a voxel size of 0.2 mm, gray scale of 14 bits, focal point of 0.5 mm, image detector - amorphous silicon flat panel, image acquisition - a 360° rotation. Images were generated in XORAN files, saved in DICOM format, and acquired with Vision software. The same calibrated examiner (GSM) performed

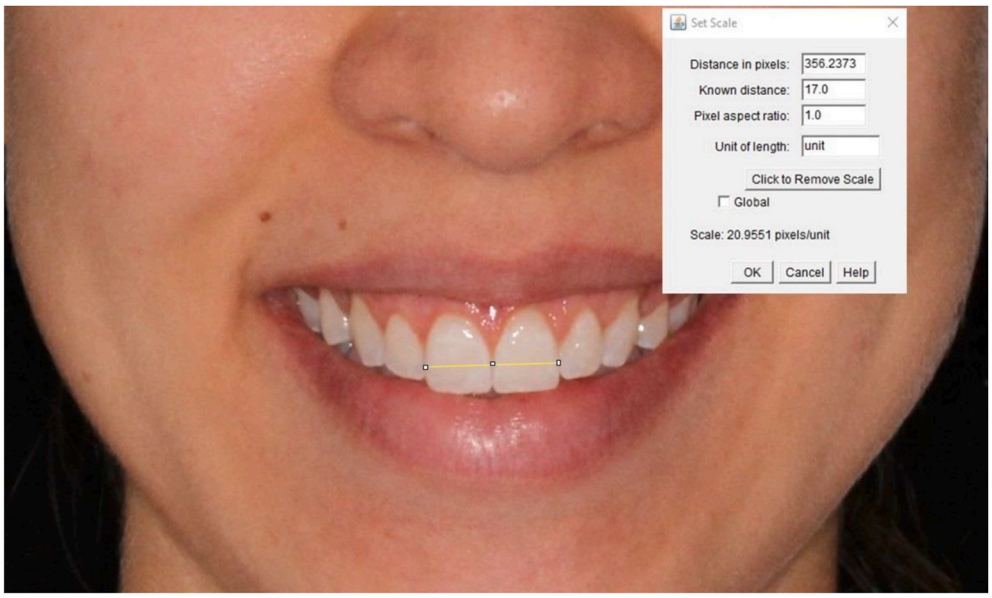

Fig. 2. Photograph calibration on ImageJ using the most distal point of each central incisor (known clinical distance – 17 mm; distance in pixels - 356.23).

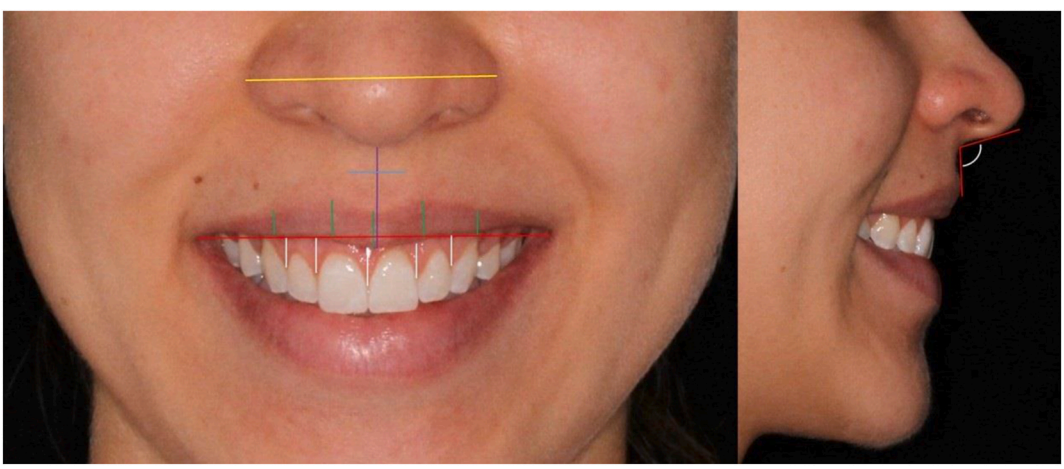

Fig. 3. Measures of length of the vermilion smiling (green), gingival exposure (white), lip shape (red), nose width (yellow), lip height (purple), filter width (blue), and nasolabial angle (right picture).

the measurements of the PMMA with an interval of at least 15 days. The DICOM image was positioned in each axis tooth from the right canine to the left canine. The following measures were then taken (Fig. 4).

a) Height: a vertical line was drawn from the lowest point of the PMMA until its highest point.
b) Thickness: a horizontal line was drawn at the center of the PMMA, transversely from the vertical line. Another two lines were drawn at an equivalent distance between the end of the PMMA and the central line.

In order to measure the PMMA graft volume in ST-CBCT, the evaluator (GSM) used the software InVesalius (Ministério da Ciência, Tecnologia e Inovações, Brazil, InVesalius version v3.1.1) to isolate the PMMA graft from the maxillary bone. The process started by importing the ST-CBCT images (DICOM) and using the threshold tool by clicking "Generate a new mask". The threshold tool had a 15 mm diameter and variable threshold range - given that the shades of gray were different in some points, and it was important to select only the shades of gray from the PMMA. The threshold selection was performed manually from the coronal, transverse, and sagittal slice of the PMMA graft images. Once this step was completed, the software generated a 3D file of the selected area, which was imported in a Standard Triangle Language (STL) file format to the software Rhino 7 (Rhinoceros, EUA, Rhino 7 version 7.0). The last step was to select the STL and use the measurement tool from the software Rhino 7 to analyze the volume of PMMA (Supplementary File 1).

2.3. Statistical analysis

Data was organized and analyzed using Python 3.11 and the libraries: numpy, pandas, sklearn, scipy, and scikit. As one patient was lost in follow up period, a robust averaging imputation method was applied to minimize random errors, biases, uncertainty and variation. In sequence, linear regression, mean, and median imputation methods were performed. The imputed data were averaged to create a final imputed Dataset. According to the Shapiro-Wilk normality test, our data was not normally distributed. The values between different follow-up times were analyzed using the Kruksal-Wallis test at 5 % of significance, followed by the post hoc Dunn test for paired comparisons. All

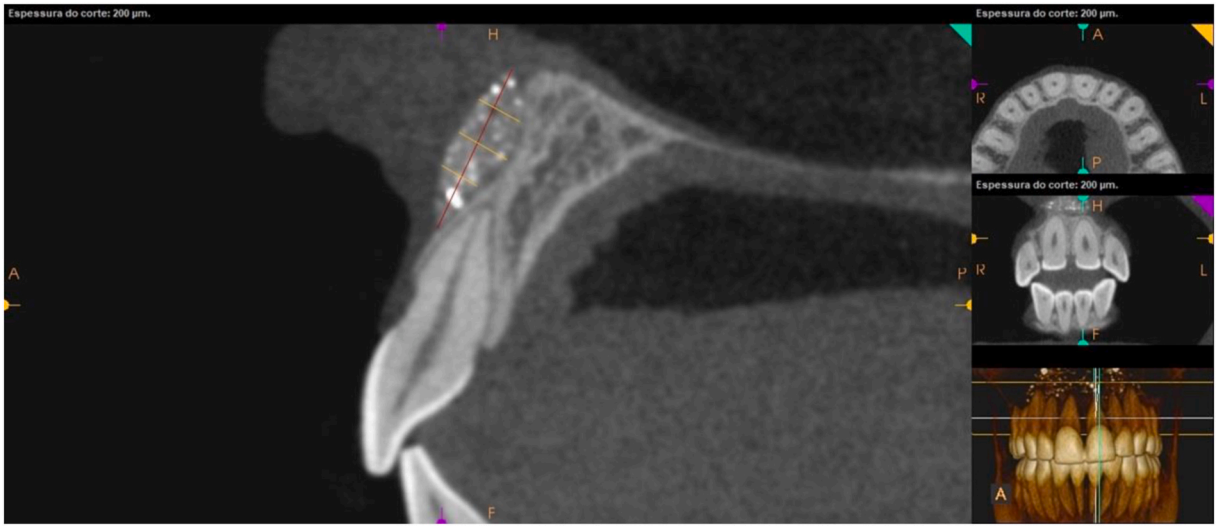

Fig. 4. Measurements of height and thickness for the polymethyl methacrylate-based bone cement graft made on the tomography images (height – red line; thickness – yellow lines).

measurements were performed twice in a time span of two weeks at least. Random and systematic errors were evaluated by comparing the first and second measured values, respectively, by Dahlberg formula and paired *t*-test.

3. Results

Twelve patients met the eligibility criteria and were recruited for the study. All the participants were female, with a mean age of 23.91 ± 3.33, ranging from 20 to 32 years. Patients were systemically healthy and did not present any contraindication to go through oral surgery or to use post-operative medication. Surgeries were successful, and the patients did not present any post-operative complications. The ACL procedure proved effective in maintaining crown length stability without presenting recession or rebound.

The descriptive statistics for the photographic parameters such as GE, LLV, LS, NW, FW, NAS, and NAR measured at T_0, T_3, T_6, and T_{12} are shown in Table 1. Also, the height, thickness, and volume values of the PMMA at T_{12} are presented. GE was 8.33 ± 1.25 mm in baseline, and it decreased to 5.90 ± 1.50 mm, 6.33 ± 1.73 mm, and 6.60 ± 0.93 mm in the follow-up periods of T_3, T_6, and $T_{12,}$ respectively ($p < 0.01$). A statistically significant difference was found for GE between T_0 and all the other follow-up periods (Fig. 5).

LLV, LS, NW, FW, NAS, and NAR showed no statistical differences between the baseline and follow-up periods. NAR was 98.34 ± 9.28° at T_0 and increased to 105.51 ± 6.30° after 3 months of follow-up. The angle was 104.68 ± 6.66° and 105.13 ± 7.33° for T_6, and $T_{12,}$ respectively ($p = 0.05$). Between T_0 and T_{12}, some non-statistically significant changes were found: 0.51 mm for LLV, 0.47 mm for LLV (C), 0.75 mm for LLV (L), 1.06 mm for LS, 0.85 mm for NW, 0.28 mm for FW, and 6.77° for NAS. The height of the PMMA was 12.90 ± 2.16 mm, the thickness was 3.82 ± 1.10 mm, and the volume was 1532.02 ± 532.52 mm^3. The Dahlberg error varied between 0.03 and 0.13 mm for all variables, and there were no statistically significant differences noted between the initial and subsequent measurements for any of them.

4. Discussion

The present clinical study demonstrates that polymethyl methacrylate-based bone cement graft, associated with aesthetic crown lengthening surgery, proves effective in treating excessive gingival display attributed to multifactorial causes, such as altered passive eruption, hypermobile upper lip, and maxillary subnasal depression. To evaluate soft tissue anatomical differences and the height, thickness, and volume of the PMMA in 12 months follow-up, photographs, and tomographic scans were made at baseline and follow-up period. Considering the small number of publications regarding the applications of the PMMA, none of the reports could provide accurate dimensions of the graft.[9,12,16] A case report stated a maximum thickness of 7 mm based on medical literature, but there was no mention of height or thickness for the PMMA placed in the patient treated in their study.[12] The present study's mean height, thickness, and volume were 12.90 ± 2.16 mm, 3.82 ± 1.10 mm, and 1532.02 ± 532.52 mm^3, respectively. Those measures were meticulously taken from six different transversal sections in relation to each anterior maxillary tooth. Additionally, intending to provide more accuracy, the thickness measure was an average value from three equidistant horizontal measures. Only one study could perform a similar evaluation; however, in its methods, the graft was measured in cephalometric radiographs, with only one measurement line in the middle of the PMMA.[17] The authors reported a range from 4 to 7 mm in a sample of 11 patients. Direct comparisons between these values and the present study are not possible, considering that the cephalometric radiograph is not the preferred method to measure the cement graft since its image is overlapped and distorted. However, our study's central portion of the cement ranged from 1.6 to 7.4 mm. Another similar study assessed the use of an inverted m-shaped expanded polytetrafluoroethylene (ePTFE) implant at the base of the piriform aperture to correct midface depression and improve gingival exposure.[11] Although the filling material placed in the depression is entirely different between the studies, it is feasible to compare the height (12.4 ± 3.1 mm) and the thickness (4.2 ± 1.1 mm) in this case, as the ePTFE implants were produced before surgery. It is important to elucidate that the PMMA is usually not pre-shaped, demanding a precise *trans*-operative anatomic modeling, and the amount of heat released from the chemical reaction is positively correlated with the thickness and volume of the cement.[12,24,25]

The present prospective study found a statistically significant decrease in gingival exposure within 3–12 months after PMMA placement. At baseline, participants had a GE of 8.33 ± 1.25 mm, which decreased to 6.60 ± 0.93 mm after 12 months, demonstrating that the PMMA alone significantly improved 1.74 mm ($p < 0.01$). Torres et al. did not report a correlation between any facial changes and the width of the PMMA.[17] Other authors described a significant decrease of 3.73 mm in the gingival display in T_6^{11}, compared to 2.01 mm in the present study for the same period. However, it is important to consider that the materials, techniques, dimensions of graft (or implant), and sample were

Table 1
Descriptive analysis of the included variable during the follow-up periods (n = 12).

Variables	Follow-up	Mean	SD	p-value
GE[a]	T_0	8.33[(a)]	1.25	0.00[a]
	T_3	5.90[(b)]	1.50	
	T_6	6.33[(b)]	1.73	
	T_{12}	6.60[(b)]	0.93	
LLV	T_0	4.84	1.52	0.29
	T_3	5.70	1.46	
	T_6	5.84	1.79	
	T_{12}	5.35	1.89	
LLV (C)	T_0	5.32	2.08	0.57
	T_3	6.46	2.08	
	T_6	6.24	2.29	
	T_{12}	5.79	2.42	
LLV (L)	T_0	5.72	1.93	0.22
	T_3	6.91	1.79	
	T_6	6.59	2.16	
	T_{12}	6.47	2.23	
LS	T_0	−1.78	0.99	0.07
	T_3	−1.15	1.31	
	T_6	−1.02	0.59	
	T_{12}	−0.72	1.27	
NW	T_0	40.00	2.75	0.53
	T_3	41.39	2.82	
	T_6	41.17	3.18	
	T_{12}	40.85	2.88	
FW	T_0	10.10	2.43	0.74
	T_3	10.77	2.37	
	T_6	10.08	2.16	
	T_{12}	9.81	2.34	
NAS	T_0	93.79	10.28	0.08
	T_3	102.88	3.81	
	T_6	100.42	8.28	
	T_{12}	100.55	8.61	
NAR	T_0	98.34	9.28	0.05
	T_3	105.51	6.30	
	T_6	104.68	6.66	
	T_{12}	105.13	7.33	
PMMA Height		12.84	1.59	–
PMMA Thickness		3.83	0.53	
PMMA Volume		1532.02	532.52	

GE, gingival exposure smiling; LLV, length of the vermilion smiling; LLV (L), lateral lengths of the vermilion smiling; LLV (C), central lengths of the vermilion smiling; LS, lip shape smiling; NW, nose width; FW, filter width; NAS, nasolabial angle smiling; NAR, nasolabial angle at rest; PMMA, polymethyl methacrylate-based bone cement graft; T_0, baseline; T_3, 3 months; T_6, 6 months; T_{12}, 12 months. SD, standard deviation.

[a] Significantly difference between any of the follow-up periods ($p < 0.05$) analyzed via Kruksal-Wallis test. Post hoc Dunn test for paired comparisons represented as (a) and (b) to indicate which follow-up periods display statistically significant differences.

not comparable; since it was an ePTFE pre-shaped implant with an inverted "m" shape, in a sample of patients with midface depression, with the incision being made 5 mm above gingival sulcus.[11] Case reports in the literature have generically stated that the PMMA improved the gingival display in qualitative analysis, although the authors did not quantify this improvement.[12,16,18] These case reports can be highly biased, considering that ACL was also performed, and the authors did not provide data to differentiate the improvements from PMMA and the ACL.[12,16,18]

Many other procedures have been considered as treatments for EGD caused by hypermobile upper lip, such as lip repositioning surgery,[26,27] micro-autologous fat transplantation (MAFT),[28] botulinum toxin injection (BTX),[29,30] and temporary skeletal mini-screw anchorage devices.[5] A meta-analysis including eight studies has reported the EGD reduction in a follow-up of 3, 6, and 12 months after lip repositioning surgery: 2.87 mm (95 % CI: 1.91–3.82), 2.71 mm (95 % CI: 1.95–3.47), and 2.10 mm (95 % CI: 1.48–2.72), respectively. Those outcomes demonstrate that the lip repositioning technique's effectiveness tends to decrease and cause some relapse after 12 months. Our study showed a similar tendency regarding the decrease of EGD reduction from T_3 (2.44 mm) to T_6 (2.01 mm) and finally at T_{12} (1.74 mm). Despite their transient effect, BTX injections are well-evidenced as a successful treatment for decreasing gingival display. A meta-analysis assessing the reduction in gingival display during follow-ups from 2 to 12 weeks revealed decreases of 4.44 mm and 2.69 mm, respectively. Despite the authors indicating clinical satisfaction, meta-analysis indicated no statistically significant treatment effect at the 12-week mark.[29] A prospective study compared lip repositioning surgery with BTX, showing that patients submitted to lip repositioning surgery presented a decrease in gingival exposure of 2.90 mm and 1.02 mm at 2 weeks and 6 months follow-up, respectively.[30] The BTX group showed a higher relapse between the same periods: 3.83 mm and 0.35 mm, respectively. In comparison to PMMA in our study, both treatments demonstrated substantial relapse of EGD, which confirms that PMMA can be the most stable treatment option. A study with 7 patients with excessive gingival exposure submitted to MAFT (16.1 mL of fat inserted in average), after follow-up periods ranging from 6 to 24 months, showed a decrease in the gingival display of 4.42mm[28]. Caution should be taken regarding this result since it was a preliminary study with unclear methodology, dubious stability, heterogeneous follow-up, and the surgical technique was not thoroughly described.[28]

Another meaningful result concerns the increase of 6.79° of the NAR; despite the high values, these showed no statistical significance ($p > 0.05$). These results suggest that the PMMA potentially provides more upper lip and nose volume. Since the analysis was performed based on photographs, it was not possible to draw a fixed line to address whether the angle changed due to the labial or the nasal component. Nonetheless, a study demonstrated that the factor responsible for increasing the NAR was the labial component of the nasolabial angle in a 6-month follow-up; the nasolabial angle was 111° at baseline and 116° after six months.[17] However, the authors measured the changes in a cephalometric radiograph. NAS increased similarly, ranging from 93.79 ± 10.28° (T_0) to 100.42 ± 8.28° (T_6) and 100.55 ± 8.61° (T_{12}) without a statistical difference ($p = 0.08$).

Moreover, nose and filter width showed no statistical or clinical differences comparing baseline to the follow-up periods, showing that the nose component is probably unaffected by the PMMA placement. Similarly, the study in which ePTFE implants were used in patients with midface depression showed a statistically significant increase of the NAR, going from 85.3° at baseline to 95.2° at T_6[11]. A previous publication found a slightly higher nasolabial angle in patients with a gingival smile compared to participants without the condition.[31] The difference in values of NAR (96.68°) compared to NAS (86.03°) was 10.65° in females,[31] which is the reason why different analyses should be performed. During smile functioning, the dynamic position that the upper lip reaches causes musculature stretching, and consequent volumetric changes in lip and nose components of the nasolabial angle.[32,33]

In the population with EGD, the lip vermilion display is greater than in people without the condition, comprising 35 % of the upper lip length, mainly in female individuals.[2,34] Initial reports regarding the cement graft technique hypothesized that the lip vermilion could have increased values since it had a new anatomical support: the PMMA.[18] However, this quantitative analysis has not been performed in any previous study, either clinically or in photographs.[9,12] In the present study, values of smiling LLV showed a slight change between the baseline and the post-operative follow-up periods, ranging from 4.84 ± 1.52 mm at baseline to 5.35 ± 1.89 mm at T_{12}, although this difference was not statistically significant ($p = 0.29$). However, when the central measure of LLV was removed from the statistical analysis, the difference between baseline and T_{12} was higher: 0.75 mm. However, the values at T_{12} were not statistically different from the values at baseline. The PMMA induced soft tissue structure changes in a short period, but those differences were not stable in a prolonged follow-up. This difference was not present even in cephalometric radiographs analyzed in other

Fig. 5. Smile at baseline (a) and 3 (b), 6 (c), and 12 months (d) after polymethyl methacrylate-based bone cement graft placement.

studies.[17]

The upper lip shape and curvature highly influence the attractiveness of individuals with EGD. Straight and upward upper lip shapes have been reported as more attractive by dentists and laypeople, even in individuals with a gingival smile.[35] In a qualitative analysis in relation to changes in the upper lip after PMMA placement, the present study and previous publications agreed that individuals showed more straight and upward upper lips after surgery, probably due to the decrease in gingival display and the enlargement of laterals parts of vermilion at 6 months.[18] Although not statistically significant, we found changes in upper lip shape from -1.78 ± 0.99 mm at baseline to -0.72 ± 1.27 mm at T_{12}, meaning that the upper lip went from a downward shape to a straight shape, which makes it more attractive.[35] More individuals should be analyzed prospectively to conduct a more robust statistical test.

The measurement of anatomical structures within tomographic imaging, such as teeth, bone, and the maxillary sinus, constitutes a well-established practice in the field of dentistry.[36–40] Nonetheless, it is worth noting the lack of published literature pertaining to the three-dimensional volumetric measurement of PMMA grafts after their implantation. Three-dimensional technology has been used for the fabrication and subsequent printing of PMMA grafts for the management of gingival smile. In both documented case reports detailing the utilization of three-dimensionally printed PMMA grafts, the 3D planning software known as Mimics, developed by Materialise NV in Belgium, was employed. These studies encompassed a follow-up period between six months[19] and two years,[20] during which no post-operative complications were recorded, and patients consistently expressed a high degree of satisfaction with the treatment outcomes.[19,20] Caution is needed due to the limited availability of evidence concerning the implementation of 3D planning and printing techniques for PMMA grafts. Existing research primarily comprises single-patient case reports, thereby offering a restricted scope of evidence. Consequently, there is an evident lack of established metrics pertaining to alterations in the patient's smile or the long-term stability of such procedures. Furthermore, the precision of 3D printed PMMA grafts in relation to the underlying anatomical bone structures and the potential necessity for intraoperative adjustments remain poorly documented in the existing literature.

A few limitations should be pointed out regarding the type of study, methodology, sample, type of analysis, and follow-up. The sample was comprised entirely of female individuals, similarly to previous studies of gingival smile treatment.[17,26] EGD is twice as prevalent in females compared to males, and females tend to be more critical about the esthetics of their smile.[3,41] Still, these results could hardly be generalized to male individuals. The study design did not allow the presence of a control group since the surgical PMMA placement was not compared to any other technique, considering that it is a definitive graft. Also, the study comprised 12 patients for the longitudinal analysis. In the future, studies with a larger sample should be performed to achieve more significant outcomes. Different operators performed the surgeries, which could mean different operational methods were applied, even under experienced specialists' supervision. The present study demonstrates some notable strengths. Firstly, the enhanced evaluation of PMMA in our research represents an improvement over previous studies. Unlike the conventional bidimensional cephalometric radiographs used in other studies, six different images from a ST-CBCT scan were analyzed, providing a more comprehensive and accurate assessment. Another significant strength is the pioneering approach of conducting a tridimensional tomographic evaluation of the cement graft volume (mm^3), introducing a novel and precise measurement method. Furthermore, this study innovates by not only being one of the few non-case-report studies to examine enhancements in gingival exposure and facial changes post-PMMA graft installation but also being the first to analyze changes in nose, lip, and smile shape attributed to PMMA grafts. These elements collectively contribute to the robustness and uniqueness of this research, enhancing its contribution to the field.

5. Conclusions

Individuals with maxillary subnasal depression and hypermobile upper lip, who present excessive gingival display, can be successfully treated with the placement of a polymethyl methacrylate-based bone cement graft. The PMMA placement technique can decrease gingival exposure to an average value of 1.74 mm, and this improvement is stable for at least 12 months. Other soft-tissue structural changes, such as the

increasing in the nasolabial angle, may occur transiently between 3 and 6 months after surgery. Different from other treatments for the same condition, PMMA should be considered a satisfactory stable and permanent treatment to decrease gingival exposure, with better results associated with aesthetic crown lengthening.

Funding

No funding.

Ethical approval

This study protocol was approved by the Research Ethics Committee (CEP) of the Faculty of Health Sciences of the University of Brasília-UnB (CAAE: 88468618.9.0000.0030).

Informed consent was obtained from all individual participants included in the study.

Declaration of competing interest

Authors declare no conflict of interest.

Acknowledgements

The authors thank the fundamental cooperation of students who performed the surgeries and professors who supervised the procedures.

Appendix A. Supplementary data

Supplementary data to this article can be found online at https://doi.org/10.1016/j.jobcr.2024.04.007.

References

1. Faus-Matoses V, Faus-Matoses I, Jorques-Zafrilla A, Faus-Llácer VJ. Lip repositioning technique. A simple surgical procedure to improve the smile harmony. *J Clin Exp Dent*. 2018;10(4):e408–e412. https://doi.org/10.4317/jced.54721.
2. Miron H, Calderon S, Allon D. Upper lip changes and gingival exposure on smiling: vertical dimension analysis. *Am J Orthod Dentofac Orthop Off Publ Am Assoc Orthod its Const Soc Am Board Orthod*. 2012;141(1):87–93. https://doi.org/10.1016/j.ajodo.2011.07.017.
3. Tjan AH, Miller GD, The JG. Some esthetic factors in a smile. *J Prosthet Dent*. 1984;51(1):24–28. https://doi.org/10.1016/s0022-3913(84)80097-9.
4. Chu SJ, Karabin S, Mistry S. Short tooth syndrome: diagnosis, etiology, and treatment management. *J Calif Dent Assoc*. 2004;32(2):143–152.
5. Alshammery D, Alqhtani N, Alajmi A, et al. Non-surgical correction of gummy smile using temporary skeletal mini-screw anchorage devices: a systematic review. *J Clin Exp Dent*. 2021;13(7):e717–e723. https://doi.org/10.4317/jced.58242.
6. Aroni MAT, Pigossi SC, Pichotano EC, de Oliveira GJPL, Marcantonio RAC. Esthetic crown lengthening in the treatment of gummy smile. *Int J Esthet Dent*. 2019;14(4):370–382.
7. Simon Z, Rosenblatt A, Dorfman W. Eliminating a gummy smile with surgical lip repositioning. *J Cosmet Dent*. 2007;23(1).
8. Andijani RI, Tatakis DN. Hypermobile upper lip is highly prevalent among patients seeking treatment for gummy smile. *J Periodontol*. 2019;90(3):256–262. https://doi.org/10.1002/JPER.18-0468.
9. Naldi LF, Adolfi D, Adolfi MC, Mendonça JAG, Leite AC, Oliveira RCG. Use of polymethilmethacrylate for esthetic crown lengthening, associated with lip repositioning: an original method. *TeamWork*. 2010;3(3):26–35.
10. Dolt AH 3rd, Robbins JW. Altered passive eruption: an etiology of short clinical crowns. *Quintessence Int*. 1997;28(6):363–372.
11. Wei J, Herrler T, Xu H, et al. Correction of midface depression using an inverted m-shaped expanded polytetrafluoroethylene implant improves gingival exposure. *Ann Plast Surg*. 2016;77(6):597–602. https://doi.org/10.1097/SAP.0000000000000735.
12. Arcuri T, da Costa MFP, Ribeiro IM, Júnior BDB, Lyra eSilva JP. Labial repositioning using polymethylmethracylate (PMMA)-based cement for esthetic smile rehabilitation—a case report. *Int J Surg Case Rep*. 2018;49:194–204.
13. Bhimani RA, Sofia ND. Lip repositioning, aesthetic crown lengthening, and gingival depigmentation: a combined approach for a gummy smile makeover. *J Cutan Aesthetic Surg*. 2019;12(4):240–243. https://doi.org/10.4103/JCAS.JCAS_25_19.
14. Lee S-C, Wu C-T, Lee S-T, Chen P-J. Cranioplasty using polymethyl methacrylate prostheses. *J Clin Neurosci Off J Neurosurg Soc Australas*. 2009;16(1):56–63. https://doi.org/10.1016/j.jocn.2008.04.001.
15. Frazer RQ, Byron RT, Osborne PB, West KP. PMMA: an essential material in medicine and dentistry. *J Long Term Eff Med Implants*. 2005;15(6):629–639. https://doi.org/10.1615/jlongtermeffmedimplants.v15.i6.60.
16. Naldi LF, Ferreira GC, Borges GJ, Mendonça JAG, Carvalho AL, Oliveira RCG de. Reposicionamento labial com cimento ortopédico associado a aumento estético de coroa clínica. *Clín int j braz dent*. 2011:284–290. Published online.
17. Torres ÉM de, Valladares-Neto J, Bernades K de O, et al. Facial profile changes due to bone cement graft to manage the hyperactive muscles of the gingival smile. *Dental Press J Orthod*. 2020;25(2):44–51. https://doi.org/10.1590/2177-6709.25.2.044-051.oar.
18. Borges GJ, Ruiz LFN, Souza JB, Santos LFE, de Sousa Andrade R, Batista DG. Aumento de coroa estético associado ao reposicionamento labial com cimento ortopédico. *Rev Odontológica do Bras Cent*. 2012;21(57).
19. Freitas de Andrade P, Meza-Mauricio J, Kern R, Faveri M. Labial repositioning using print manufactured polymethylmethacrylate- (PMMA-) based cement for gummy smile. *Case Rep Dent*. 2021;2021, 7607522. https://doi.org/10.1155/2021/7607522.
20. de Castro LF, de Andrade PF, Leite GG, de Andrade AJS, Valentim GL, Souza Et de. 3D-printed PMMA implant for gingival smile treatment through the VISTA technique: a report of a new approach. *Clin Adv periodontics*. 2023;13(1):27–32. https://doi.org/10.1002/cap.10200.
21. Dietrich T, Ower P, Tank M, et al. Periodontal diagnosis in the context of the 2017 classification system of periodontal diseases and conditions - implementation in clinical practice. *Br Dent J*. 2019;226(1):16–22. https://doi.org/10.1038/sj.bdj.2019.3.
22. Carneiro VM de A, Gomes AMS, Marinho MU, et al. Dental and periodontal dimensions stability after esthetic clinical crown lengthening surgery: a 12-month clinical study. *Clin Oral Invest*. 2024;28(1):76. https://doi.org/10.1007/s00784-023-05458-5.
23. Januário AL, Barriviera M, Duarte WR. Soft tissue cone-beam computed tomography: a novel method for the measurement of gingival tissue and the dimensions of the dentogingival unit. *J Esthet Restor Dent Off Publ Am Acad Esthet Dent . [et al]*. 2008;20(6):366–373. https://doi.org/10.1111/j.1708-8240.2008.00210.x. ; discussion 374.
24. Khader BA, Towler MR. Materials and techniques used in cranioplasty fixation: a review. *Mater Sci Eng C*. 2016;66:315–322. https://doi.org/10.1016/j.msec.2016.04.101.
25. Li C, Schmid S, Mason J. Effects of pre-cooling and pre-heating procedures on cement polymerization and thermal osteonecrosis in cemented hip replacements. *Med Eng Phys*. 2003;25(7):559–564. https://doi.org/10.1016/s1350-4533(03)00054-7.
26. Andijani RI, Paramitha V, Guo X, Deguchi T, Tatakis DN. Lip repositioning surgery for gummy smile: 6-month clinical and radiographic lip dimensional changes. *Clin Oral Invest*. 2021;25(10):5907–5915. https://doi.org/10.1007/s00784-021-03896-7.
27. Dos Santos-Pereira SA, Cicareli ÁJ, Idalgo FA, et al. Effectiveness of lip repositioning surgeries in the treatment of excessive gingival display: a systematic review and meta-analysis. *J Esthet Restor Dent Off Publ Am Acad Esthet Dent . [et al]*. 2021;33(3):446–457. https://doi.org/10.1111/jerd.12695.
28. Huang S-H, Huang Y-H, Lin Y-N, et al. Micro-autologous fat transplantation for treating a gummy smile. *Aesthetic Surg J*. 2018;38(9):925–937. https://doi.org/10.1093/asj/sjy069.
29. Chagas TF, Almeida NV de, Lisboa CO, Ferreira DMTP, Mattos CT, Mucha JN. Duration of effectiveness of Botulinum toxin type A in excessive gingival display: a systematic review and meta-analysis. *Braz Oral Res*. 2018;32, e30. https://doi.org/10.1590/1807-3107bor-2018.vol32.0030.
30. Makkeiah MO, Harfoush M, Makkiah A, Saneeva L, Tuturov N, Katbeh I. [Comparative efficacy of Botox and surgical lip repositioning in the correction of gummy smile]. *Stomatologiia (Mosk)*. 2021;100(3):47–54. https://doi.org/10.17116/stomat202110003147.
31. Kolte AP, Kolte RA, Samarth GK. Association of the nasolabial angle and lip length with the gingival and interdental smile line-A gender based evaluation. *J Esthet Restor Dent Off Publ Am Acad Esthet Dent . [et al]*. 2021;33(3):503–509. https://doi.org/10.1111/jerd.12657.
32. Ahmad I. Anterior dental aesthetics: dentofacial perspective. *Br Dent J*. 2005;199(2):81–88. https://doi.org/10.1038/sj.bdj.4812521. quiz 114.
33. Saki M, Danaei SM, Sardarian A, Shavakhi M. Changes of nasolabial angle from rest to smile in relation to cephalometric parameters. *Int J Esthet Dent*. 2019;14(4):434–442.
34. Grover N, Kapoor DN, Verma S, Bharadwaj P. Smile analysis in different facial patterns and its correlation with underlying hard tissues. *Prog Orthod*. 2015;16:28. https://doi.org/10.1186/s40510-015-0099-4.
35. Valverde-Montalva SH, Flores-Mir C, Rinchuse D, Arriola-Guillén LE. Influence of upper lip curvature on smile attractiveness in patients with different degrees of gingival smiles: a cross-sectional study with opinions from oral health providers and laypersons. *Am J Orthod Dentofac Orthop Off Publ Am Assoc Orthod its Const Soc Am Board Orthod*. 2021;159(4):e321–e329. https://doi.org/10.1016/j.ajodo.2020.10.022.
36. Esposito SA, Huybrechts B, Slagmolen P, et al. A novel method to estimate the volume of bone defects using cone-beam computed tomography: an in vitro study. *J Endod*. 2013;39(9):1111–1115. https://doi.org/10.1016/j.joen.2013.04.017.
37. Forst D, Nijjar S, Flores-Mir C, Carey J, Secanell M, Lagravere M. Comparison of in vivo 3D cone-beam computed tomography tooth volume measurement protocols. *Prog Orthod*. 2014;15(1):69. https://doi.org/10.1186/s40510-014-0069-2.
38. Hettiarachchi PVKS, Gunathilake PMPC, Jayasinghe RM, et al. Linear and volumetric analysis of maxillary sinus pneumatization in a Sri Lankan population using cone beam computer tomography. *BioMed Res Int*. 2021;2021, 6659085. https://doi.org/10.1155/2021/6659085.

39. Sarilita E, Lita YA, Nugraha HG, Murniati N, Yusuf HY. Volumetric growth analysis of maxillary sinus using computed tomography scan segmentation: a pilot study of Indonesian population. *Anat Cell Biol.* 2021;54(4):431–435. https://doi.org/10.5115/acb.21.051.
40. Hamdy RM, Abdel-Wahed N. Three-dimensional linear and volumetric analysis of maxillary sinus pneumatization. *J Adv Res.* 2014;5(3):387–395. https://doi.org/10.1016/j.jare.2013.06.006.
41. Kerns LL, Silveira AM, Kerns DG, Regennitter FJ. Esthetic preference of the frontal and profile views of the same smile. *J Esthetic Dent.* 1997;9(2):76–85. https://doi.org/10.1111/j.1708-8240.1997.tb00921.x.