

THESIS FOR THE DEGREE OF DOCTOR OF PHILOSOPHY (PhD)

**CLINICAL PATHOLOGY OF THE ILEOCAECAL JUNCTION IN CHILDHOOD AND
JUSTIFICATION OF ITS RECONSTRUCTION AS PART OF THE AUTOLOGOUS
INTESTINAL RECONSTRUCTIVE SURGERY**

By: Dr. Semiu Eniola Folaramni

Supervisor: Dr. Tamas Cserni PhD and Dr. George Rakoczy PhD



UNIVERSITY OF DEBRECEN

DOCTORAL SCHOOL OF CLINICAL MEDICINE

DEBRECEN, 2014

1. INTRODUCTION	6
2. REVIEW OF THE LITERATURE	10
2.1. Anatomy of the ileocaecal junction	10
2.1.1. Macroscopic anatomy	10
2.1.2. Microscopic anatomy	11
2.1.3. Embryology	13
2.2. Physiology of the ileocaecal junction	14
2.2.1. Hydrostatic characteristic	14
2.2.2. Microbiological function	14
2.2.3. Reflexes	15
2.3. Clinical pathology of the ileocaecal junction	15
2.3.1. Agenesia of the ileocaecal valve	15
2.3.2. Conditions leading to loss of ileocaecal junction	16
2.3.2.1. Intussusception	16
2.3.2.2. Volvulus	17
2.3.2.2.1. Malrotation small bowel volvulus	17
2.3.2.2.2. Proximal large bowel volvulus	20
2.3.2.2.3. Necrotising enterocolitis	24
2.3.2.2.4. Crohn's disease	26
2.3.2.2.5. Complicated appendicitis (appendix mass)	28
2.4. Summary of the clinical importance of the ileocaecal junction	30
2.4.1. Ileocaecal junction in healthy patients	30
2.4.2. Ileocaecal junction in Short Bowel Syndrome	30
2.4.3. Ileocaecal junction in Crohn's disease	31

2.5. Autologous Intestinal Reconstructive Surgery	32
2.5.1. Reverse segments and colonic interpositions	32
2.5.2 Lengthening and tailoring procedures	32
2.5.2.1. Longitudinal intestinal lengthening (LILT).....	33
2.5.2.2. Serial Transverse Enteroplasty (STEP).....	34
2.5.2.3. Spiral Intestinal Lengthening and Tailoring (SILT).....	36
2.5.2.4. Ileocaecal valve reconstruction	38
3. AIMS	40
3.1. Analysis the occurrence of surgical diseases leading to loss of the ileocaecal junction	40
3.2. Analysis the importance of the ileocaecal junction in healthy patients.....	40
3.3. Analysis the importance of the ileocaecal junction in Short Bowel Syndrome	40
3.4. Analysis the importance of the ileocaecal junction in Crohn’s disease	40
4. MATERAIL AND METHODS	41
4.1. Occurrence of surgical diseases leading to loss of the ileocaecal junction	
4.1.1. Database	41
4.1.2. Data collection.....	41
4.1.3. Data analysis.....	41
4.1.4. Statistics.....	41
4.2. The ileocaecal junction in healthy patients	41
4.2.1. Database	41
4.2.2. Data collection.....	42
4.2.3. Data analysis & Statistics	43

4.3. The ileocaecal junction in Short Bowel Syndrome.....	43
4.3.1. Database	43
4.3.2. Data collection.....	43
4.3.3. Data analysis.....	43
4.3.4. Statistics.....	43
4.4. The ileocaecal junction in Crohn’s disease	44
4.4.1. Database	44
4.4.2. Data collection.....	44
4.4.3. Data analysis.....	44
5. RESULTS	45
5.1. Occurrence of surgical diseases leading to loss of the ileocaecal junction	45
5.2. The ileocaecal junction in healthy patients	47
5.3. The ileocaecal junction in Short Bowel Syndrome	48
5.4. The ileocaecal junction in Crohn’s disease	55
6. DISCUSSION.....	56
6.1. Occurrence of surgical diseases leading to loss of the ileocaecal junction	56
6.2. The ileocaecal junction in healthy patients	60
6.3. The ileocaecal junction in Short Bowel Syndrome	61
6.4. The ileocaecal junction in Crohn’s disease	62
6.5. Summary of the new results and conclusions.....	63

7. LIST OF REFERENCE	65
7.1 The list of referenced literature	65
7.2. The list of publications on which the thesis was based on	71
7.3. Other publications by the author	72
8. ACKNOWLEDGEMENT	74
9. APPENDIX	
Approval of the clinical director of RMCH	75
Copy of publications used for this thesis	76

1. INTRODUCTION

Concepts relating to the ileocaecal valve (ICV) have changed during the last decades. Initially it was described as a passive valve preventing reflux from the colon into the ileum. Later, probably influenced by studies describing a thickened muscle layer and the detection of a high pressure zone at the valve, the idea of a sphincter emerged, with a role in the regulation of intestinal transit and digestion [46].

The ileum is also known as the “stomach of the intestine” because, like the stomach, it empties periodically into the colon through the IC valve which, like the pyloric sphincter, is otherwise kept closed. This mechanism is regulated by specific ileo-colic and colo-ileal reflexes. Therefore, recently the ileum-ileocaecal valve-caecum together with their regulating reflexes have been considered as a unique integrated motility unit [46]. This complex unit (the ileocaecal junction) keeps the chyme in the ileum for a sufficient length of time and makes optimal absorption possible. It is well known that the terminal ileum has an important role in the uptake of nutrients and is the only specific site of the intestine where vitamin B₁₂ and bile salts are absorbed.

The ileocaecal valve also serves as a microbiological barrier between small and large bowel. The presence of colonic bacteria is undesirable in the ileum. The mechanical characteristics, the abundant lymphatic tissue, and the motoric reaction on pH change caused by the refluxing bacteria are responsible for keeping the barrier alive [46].

According to these, it is easy to understand that structural or functional failure of this unit may lead to a dysfunctional absorption and a change in bowel habit, especially in developing children.

Although the specific anatomy, embryology and physiology of the ileocaecal valve have been extensively studied in the past, its importance in clinical practice remains undervalued. The loss of the ileocaecal valve is thought to be generally well tolerated, therefore not enough attention has been paid to prevent its loss. Only few sporadic attempts have been made to reconstruct the valve using small bowel nipple valve, telescope or submucosally tunnelled anastomosis in specific conditions like Short Bowel Syndrome and Crohn's disease [6, 7, 59, 60, 69]. These reconstructions, based on the old valve concept, focused mainly on reconstructing the anti-reflux property, but the restoration of a functional ileo-caecal junction had not been considered. However a recent neuro-anatomic study suggests the possibility of reconstructing a functional ileo-caecal junction. This concept is based on the observation that there are no specific neuro-anatomic features of a sphincter seen in the ileocaecal valve. There are no specific nerve structures or a thickened homogeneous smooth muscle, like that present in the pyloric or internal anal sphincter. In contrast, the ileocaecal valve resembles a simple intussusception of the ileum into the caecum. Based on this, Cserni et al. suggested that a simple double layer end-to-side, 1-2 cm intussuscepted ileo-colostomy would be the best option for reconstruction of the ileocaecal valve, that would possibly allow recovery of the ileo-colic reflexes and a functional ileocolic junction [15]. The application of this simple technique in routine ileo-colostomy, instead of the usual end-to-end and side-to-side techniques, may help avoid complications originating from the loss of the ileocaecal valve. Such simplified ileo-caecal valve reconstruction should become part of the Autologous Intestinal Reconstruction of Short Bowel Syndrome, and surgery for Crohn's disease, and should be considered in otherwise healthy patients when the ileocaecal valve is resected.

This thesis gathers evidence to justify ileocaecal valve reconstruction. It focuses on the clinical importance of the ileocaecal junction using a clinical database from a large paediatric institution in the United Kingdom, the Royal Manchester Children's University Hospital and clinical data, research experience and results from the Medical Health Science Centre, University of Debrecen, Hungary.

In the introduction we outline the most recent up to date knowledge on the anatomy, histology, embryology and physiology of the ileocaecal valve in order to better understand its function. Additionally we review the present literature regarding clinical pathology related to the ileocaecal valve, the knowledge regarding the importance of the valve in Crohn's disease, Short Bowel Syndrome patients and in otherwise healthy patients. The possibility of the ileocaecal valve reconstruction is briefly reviewed as well.

Our first aim, from the clinical database, was to identify and analyse the surgical conditions that lead to loss of the ileocaecal valve in children, and to determine how these adverse effects could be prevented. We review the relations of a rare and not well known cause of ileocaecal loss i.e. proximal large bowel volvulus in children, by using data of patients treated with this condition in Manchester and Debrecen and data from a systematic review of the literature.

It is generally believed that otherwise healthy children tolerate the loss of the ileocaecal valve, but there is no specific data in the literature to support this belief. Our second objective, therefore, was to evaluate the long term complications seen after the loss of the ileocaecal junction in patients that did not suffer from Crohn's disease or Short Bowel Syndrome. The loss of a certain segment of the terminal ileum alone may lead to diarrhoea due to the laxative effect of unabsorbed bile salts [2]. The loss of the caecum and ascending

colon may diminish the reabsorption of water and may cause diarrhoea. We decided to determine which part of the ileocaecal junction (ileum, valve, or caecum) is mostly responsible for the complications that arise from its loss.

The third goal was to review the importance of the valve in our Short Bowel Syndrome patients. It is believed that patients with Short Bowel Syndrome and an intact ileocaecal valve can survive with a shorter segment of small bowel and require a shorter duration of total parenteral nutrition [21]. In order to find more evidence of its importance we assessed how the presence of the intact valve influenced the outcome of children with Short Bowel Syndrome.

Attempts have been made to reduce the risk of recurrence of Crohn's disease by reconstructing the ileocaecal valve in adult patients [6, 7]. Our fourth intention was to review the importance of the valve in children with Crohn's disease. Data of Crohn's disease patients that underwent resection of the ileocaecal valve were analysed.

The final and summarised aim of our research was to stress the general importance of the ileocaecal valve, and to justify attempts to reconstruct it as part of *Autologous Gastro-Intestinal Reconstructive Surgery* in patients with Short Bowel Syndrome, Crohn's disease and even in otherwise healthy patients.

2. REVIEW OF THE LITERATURE

2.1. Anatomy of the ileocaecal junction

2.1.1. Macroscopic anatomy

The ileocaecal valve is situated at the junction of the ileum and the caecum. The first macroscopic anatomical reports described the ileocaecal valve (ICV) as a fold of ileal mucosa that projects into the lumen of the caecum [46]. However recent studies have shown that the ileocaecal junction resembles a full thickness intussusception of the terminal ileum into the caecum [5]. The length of the intussusception in an adult varies from 0.5cm to 2cm. Cross section of the ileocaecal valve displays both muscular and mucosal layers of the terminal ileum folding into the lumen of the caecum. The anatomy of the human ICV can be observed in Figure 1.

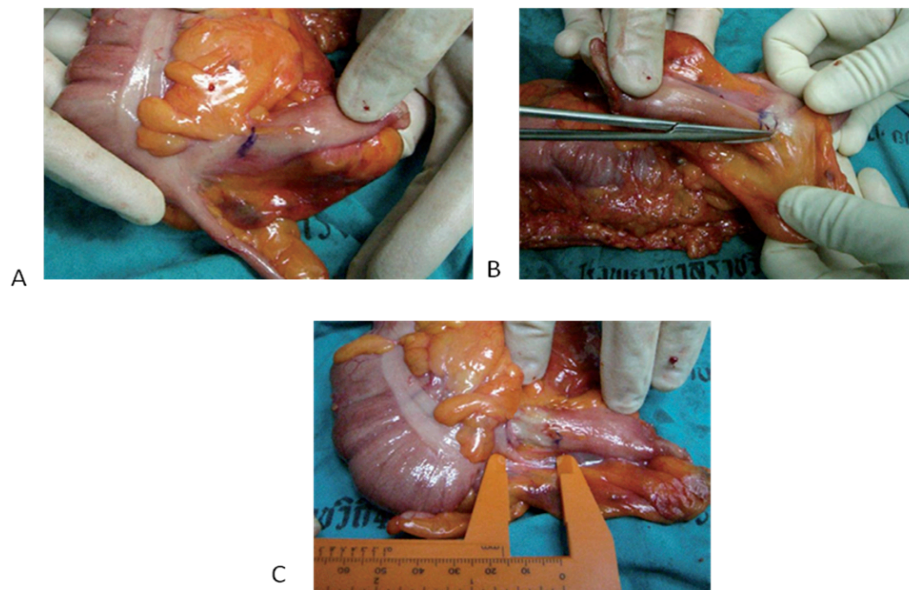


Figure 1.

Image shows the post-mortem dissection of a normal human ICV. Reduction of the intussusceptum part of the terminal ileum from the caecal wall (blue marker). A: Point of intussusception. B: Dissection and reduction of intussusception. C: Length of intussusception after reduction. Image imported from Awapittaya et al (5)

2.1.2. Microscopic anatomy

The ICV consists of three distinct muscle layers. There is an external circular muscle layer that is continuous with that of the caecal circular muscle layer, and an inner circular muscle layer that is continuous with that of the ileal circular muscle layer. The two circular muscle layers are connected at the free end of the valve. The junction of the ileal and caecal circular muscle fibres appears as an annular sphincter described by DiDio (1968) [20]. The third muscle layer that makes up the ICV is a single longitudinal muscle layer that is secondary to a fusion of the ileal and caecal longitudinal muscle layers. We demonstrated the microscopic anatomy of the ileocaecal valve in the pig (very similar to human) in Figure 2, using smooth muscle actin (SMA) immunohistochemistry.

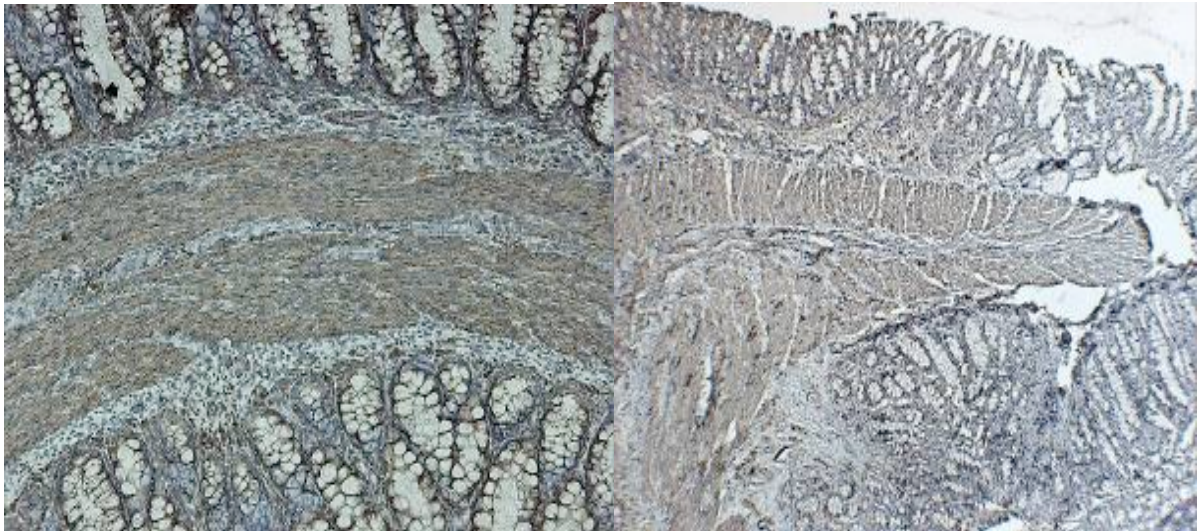


Figure 2.

Left: Ileocaecal valve of newborn pig, cross section, smooth muscle actin (SMA) immunohistochemistry, 40X magnification. The two circular muscle layers separated by a longitudinal one is clearly seen. Caecal mucosa on the top, ileal mucosa on the bottom. **Right:** : Ileocaecal valve of a 4 weeks-old-pig, longitudinal section, smooth muscle actin (SMA) immunohistochemistry, 40X magnification. The connection of the two circular muscle layers are separated by the fused longitudinal layer and connected at the tip of the valve. Ileal mucosa on the top, caecal on the bottom. (Images are made in Children's Research Centre, Univ.College Dublin by T Cserni)

There are two distinct origins of the enteric nervous system (ENS), separated by the muscle layers at the base and body of the ICV. The external ENS originates from the caecum and, as for the caecum consists of superficial submucosal, deep submucosal, and myenteric plexuses. The internal ENS originates from the ileum and its structure resembles that of the ileum. There is a direct connection between ileal and caecal ENS at the free end of the valve. Immunostaining has also shown the existence of myenteric interstitial cells of Cajal in the ileal and caecal plexuses that are connected at the free end of the ICV [15]. We demonstrated the distinct plexuses by fluorescence immunohistochemistry (Figure 3) and by NADPHd staining of whole-mounts preparations of the ileal and caecal plexuses (Figure 4).

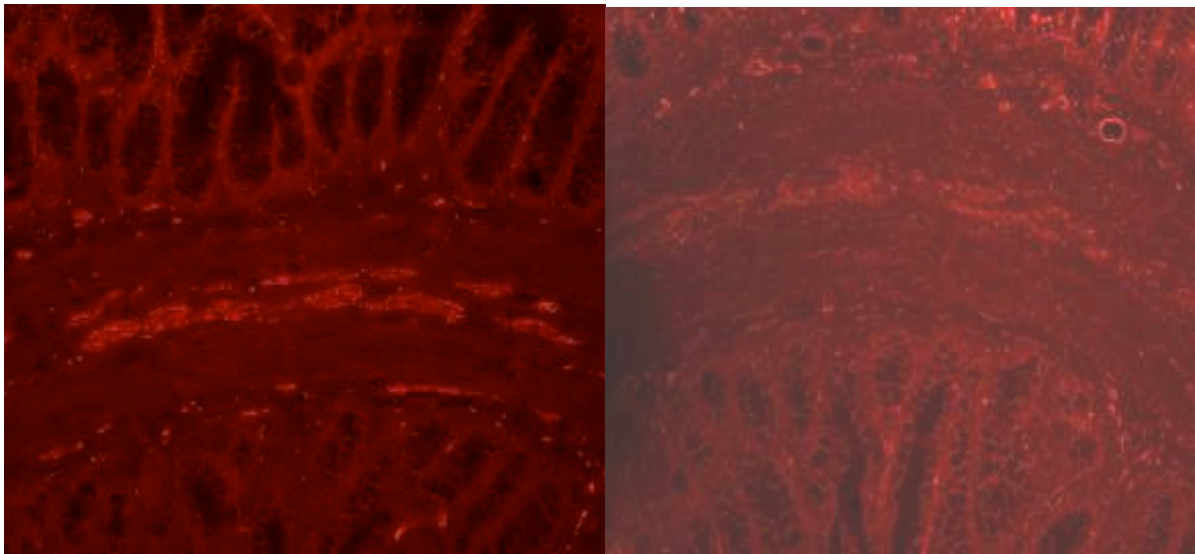


Figure 3.

Left: Ileocaecal valve of newborn pig cross section, 40X magnification. PGP 9.5 fluorescence immunohistochemistry. Upper mucosa caecum, lower mucosa ileum. Positively stained ganglia clearly visible in caecal and ileal submucosal plain. In the middle, myenteric ganglia are situated in 2 distinct, separated layers. Ileal ganglia are larger and more dense.

Right: Ileocaecal valve of newborn pig cross section, 40X magnification. ICC fluorescence immunohistochemistry. The interstitial Cajal cell network is clearly visible around the myenteric and submucosal ganglia. (Images are made in Children's Research Centre, Univ.College Dublin by T Cserni)

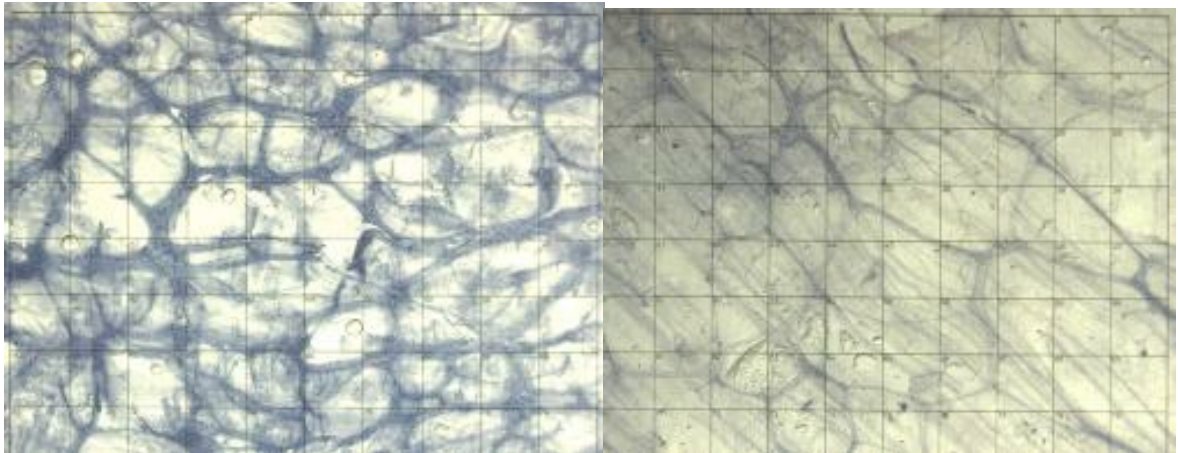


Figure 4.

Left: Ileal origin myenteric plexus within the ICV stained with NADPHd histochemistry (Whole mount preparation) **Right:** Caecal origin myenteric plexus within the ICV stained with NADPHd histochemistry (Whole mount preparation). The difference in the spatial pattern of the two plexuses is obvious. Graticula size is 1 mm. (Images are made in Children's Research Centre, Univ.College Dublin by T Cserni)

2.1.3. Embryology

The primordial (primitive) gut at the beginning of the fourth week is closed at its cranial end by the oropharyngeal membrane and at its caudal end by the cloacal membrane. The primordial gut forms during the fourth week as the head, tail, and lateral folds incorporate the dorsal part of the yolk sac into the embryo. The endoderm of the primordial gut gives rise to most of the epithelium and glands of the digestive tract. The muscular, connective tissue and other layers of the wall of the digestive tract are derived from the splanchnic mesenchyme surrounding the primordial gut. For descriptive purposes the primordial gut is divided into the foregut, the midgut, and the hindgut. The ileocaecal junction is a derivative of the midgut and is therefore supplied by the superior mesenteric artery, the artery of the midgut. Between the 6th and 10th week of embryological development the midgut rotates 270° anticlockwise and elongates resulting in loops of

jejunum and ileum [50]. The primordium of the caecum is the caecal diverticulum, which appears in the sixth week as a swelling on the antimesenteric border of the caudal limb of the midgut loop. After the 10th week of gestation, the mesentery of the caecum fuses with the posterior abdominal wall thereby fixing the caecum and the ileocaecal valve in the right iliac fossa. There is no evidence in the literature of the ileum intussuscepting into the caecum during embryological development, to form the ileocaecal valve.

2.2. Physiology of the ileocaecal junction

2.2.1. Hydrostatic characteristics

The ileocaecal valve regulates the passage of stool from the small to the large bowel by providing anterograde resistance to the forward movement of stool, and retrograde resistance to the reflux of stool from the caecum back into the ileum. This has been justified in vivo by measuring the hydrostatic pressure of the ileocaecal valve that would need to be overcome for stool to move anterogradely or retrogradely. The pressures required to overcome the anterograde and retrograde resistance of the ileocolic valve in dogs were 21.60 ± 3.96 cmH₂O and 25.8 ± 4.92 cmH₂O respectively [17].

2.2.2. Microbiological function

The flora of the ileum and the colon are completely different. The ileocaecal valve has a role in preventing microorganisms that normally flourish in the colon from coming into contact with the ileum. Beyond the hydrostatic barrier and reflexes the abundant lymphatic tissue may be responsible for this microbiological barrier function. Replacing the barrier function of the valve led to the idea of replacing the valve in Crohn's disease after ileocaecal

resection. Studies have shown a significantly lower recurrence rate after ICV reconstruction [6, 7].

2.2.3. Reflexes

The ileocaecal valve is a highly specialised segment of the gastrointestinal tract which regulates the anterograde passage of chyme from the ileum to the caecum and prevents retrograde reflux of caecal contents into the ileum. This is achieved through an excitatory/inhibitory reflex mechanism mediated through the myenteric nerve plexuses at the ileocaecal junction.

Ileocaecal inhibitory reflex: Ileal distension secondary to the arrival of chyme from the proximal bowel initiates the relaxation of the ileocaecal sphincter and the caecum, allowing the chyme to pass into the caecum.

Caeco-ileal excitatory reflex: Distension of the caecum by the chyme that has migrated from the ileum, stimulates the contraction of the sphincter and relaxation of the ileum, preventing the reflux of caecal contents back into the ileum [46, 63].

2.3. Clinical pathology of the ileocaecal junction

2.3.1. Agnesia

Jejunioileal atresia occurs in 1:330 to 1:1500 live births [38]. Despite one third of intestinal atresias being located in the distal ileum, agnesis of the ileocaecal valve is rare. Only five cases of ileocaecal valve atresia have been reported in the English literature [12,

16, 22]. Agenesis of the ICV has been shown to be accompanied by agenesis of the vermiform appendix as demonstrated in a case report of a neonate by Cserni et al 2006 [16].

2.3.2. Conditions leading to loss of ileocaecal junction

2.3.2.1. Intussusception

Intussusception is defined as the full-thickness invagination or telescoping of a proximal portion of intestine (intussusceptum) into a distal contiguous portion of intestine (intussusciens). In a population-wide survey in Switzerland, the yearly mean incidence of intussusception was 38, 31, and 26 cases per 100, 000 live births in the first, second, and third year of life respectively [11]. Intussusception occurs most often near the ileocaecal junction, indeed 90% of cases are ileocolic. Nonoperative reduction using pneumatic pressure by enema under fluoroscopic guidance is the treatment of choice for a stable child and is successful in 95% of children with an ileocolic intussusception [18]. A Foley catheter or feeding tube is inserted into the rectum and air is insufflated for 3 minutes at increasing pressures: 80, 100 and 120mmHg. This process is monitored by fluoroscopy and a successful reduction is indicated by the free flow of air into the small bowel. If the first attempt is not successful, a second attempt can be made. Failure of conservative management is an indication for surgery [18]. During open surgery the intussusceptum needs to be gently pushed back rather than pulled out, to avoid injury. The reduction of an intussusception can be undertaken laparoscopically, however a massive intussusception may cause difficulties.

If an intussusception is not reduced early, venous and lymphatic congestion occur and eventually lead to arterial obstruction, ischaemia and necrosis of the ileocaecal junction. At

this stage it becomes necessary to perform a limited right hemicolectomy, with consequent loss of the ileocaecal valve.

2.3.2.2. Volvulus

2.3.2.2.1. Malrotation and small bowel volvulus

The first description of intestinal development was written by Mall in 1898 [47]. Frazer and Robins in 1915 [31] expanded on the observations of Mall, and in 1923 Dot extended the embryologic observations to the problems encountered clinically [22]. The most accepted model of midgut maturation involves four distinct stages: (1) herniation, (2) rotation, (3) retraction, and (4) fixation. Due to the disproportionate growth and elongation of the midgut during the fourth week of embryological development, the midgut herniates into the extra-embryonic coelom in the proximal part of the umbilical cord.

Next the bowel makes three 90 degree anticlockwise rotations around the superior mesenteric artery. The first 90 degree rotation occurs outside the abdomen. The second commences during return of the bowel into the abdominal cavity during the 10th gestational week. The duodeno-jejunal junction now passes posterior to the superior mesenteric artery. The last 90 degree rotation occurs in the abdomen. The primitive intestine has now completed a 270 degree anticlockwise rotation, allowing the duodeno-jejunal limb to be positioned to the left of the superior mesenteric artery while the caeco-colic limb is on the right (Figure 5). Fixation of the ascending and descending colon subsequently occurs. Disruption of any of these vital steps leads to the spectrum of malrotation encountered clinically.

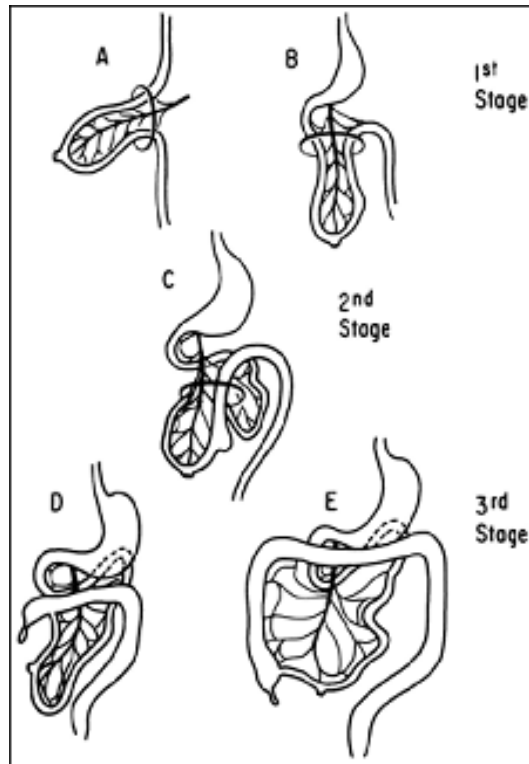


Figure. 5:

Stages in normal intestinal rotation. A, gestational age 6 weeks; B, 8 weeks; C, 9 weeks; D, 11 weeks and E, 12 weeks [27].

In malrotation the mesentery between the duodeno-jejunal junction and the caecum is narrow. The entire small bowel hangs on the trunk of the superior mesenteric vessels in one mass. This arrangement and the lack of fixation to the retroperitoneum predispose the malrotated bowel to volvulus around the mesenteric vessels and this may lead to massive intestinal necrosis and a short bowel state.

The incidence of intestinal malrotation is 1 in 500 live births. Up to 75% present during the first month of life and a further 15% present within the first year [30]. Copious bilious vomiting and a flat abdomen are the cardinal signs, and malrotation with midgut volvulus must be the presumed diagnosis until proven otherwise. The best study for

demonstrating a malrotation and volvulus is an upper gastrointestinal contrast study (Figure 6). The normal location of the duodeno-jejunal junction is to the left side of the spinal column at the level of the gastric outlet. If the duodeno-jejunal junction is not in the correct position emergency surgery is indicated [45].

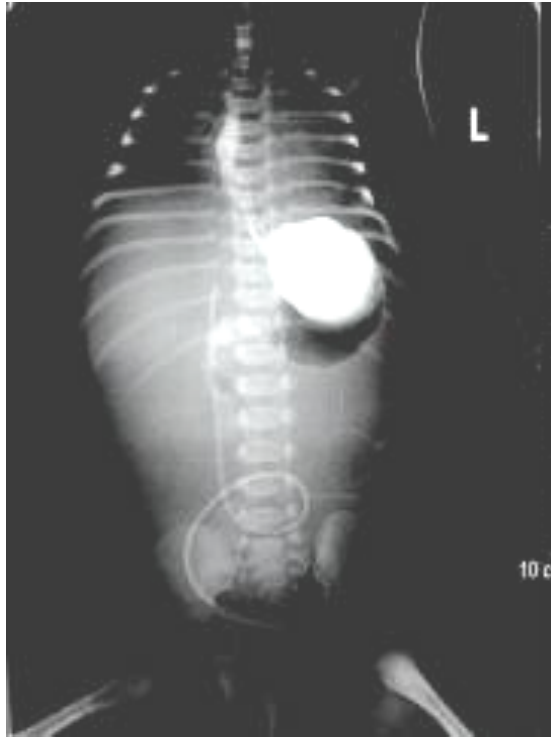

Figure 6:

An upper GI contrast showing the duodeno-jejunal junction is on the right side of the spine. It has a corkscrew appearance and there is no gas seen in the lower abdomen. This is very suggestive of midgut volvulus.
(Image from Josa Andras Teaching Hospital, Nyíregyháza, Hungary)

In 1936 William E. Ladd emphasised the importance of releasing the intra abdominal congenital bands compressing the duodenum, widening the base of the mesentery and placing the caecum in the left upper quadrant[44]. The principles of the modern procedure are almost unchanged from those of Ladd (Figure 7).

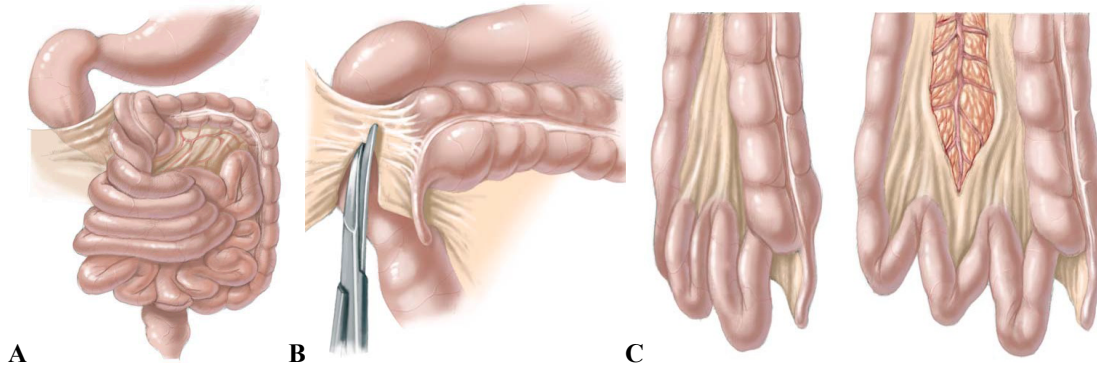


Figure 7:

Ladd's Procedure. A. Derotate volvulus anticlockwise. B. Divide the congenital Ladd's bands crossing from the caecum to the duodenum, liver and gallbladder. C. Broaden the narrow mesenteric base by dividing the peritoneal folds [50].

Intra-operatively up to 15% of cases will have strangulation of the blood supply to the midgut [49]. This may lead to irreversible ischaemia with loss of large lengths of bowel, even extending from the duodeno-jejunal junction to the transverse colon. Hence the ileocaecal valve may be lost. In a case series published in 2011, the case notes of 9 infants (median age 15 days) who underwent surgery for malrotation were reviewed. One (11%) of the patient had a right hemicolectomy with loss of the ileocaecal valve [52].

2.3.2.2.2. Proximal large bowel volvulus

Colonic volvulus was first described by Rokitansky in 1836. Proximal large bowel volvulus involves any segment from the caecum to the transverse colon undergoing an axial twist on its mesentery. Caecal volvulus (which invariably involves a variable amount of terminal ileum and ascending colon) occurs so rarely in children that its true incidence is unknown [68]. Until recently only 40 cases of proximal large bowel volvulus had been described in the English literature [65], but we have added six making it a total of 46 cases [28]. Summary of demographics, clinical features, investigations, management and mortality are in Table 1. An anatomical prerequisite for caecal volvulus is a mobile caecum which is

present in up to 26% of the normal population [55]. Neurodevelopmental delay and chronic constipation have been shown to be the two conditions most commonly associated with proximal large bowel volvulus in children [28]. In a review of the literature 69% of patients each had neurodevelopmental delay and chronic constipation [28]. The presenting features of proximal large bowel volvulus include colicky abdominal pain, abdominal distension and vomiting.

Clinical Features	Our Series	Published data	Summary
Number of patients	6	36	42
Age median (range)	12 (3-14) years	9.5 (0-18) years	10 (0-18) years
Male:Female	2:4	19:17	21:21
Neurodevelopmental delay	5/6	24/36	29/42
History of constipation	6/6/	23/36	29/42
Colicky abdominal pain	6/6/	35/36	41/42
Abdominal distension	6/6	36/36	42/42
Vomiting	5/6	30/36	35/42
Plain abdominal radiograph	6/6	36/36	42/42
Barium Enema	1/6	14/36	14/42
Surgery	6/6	36/36	42/42
Mortality	1/6	5/36	6/42
Caecum involved	6/6	26/36	32/42
Terminal ileum involved	1/6	4/36	5/42
Ascending colon involved	4/6	12/36	16/42
Transverse colon involved	3/6	14/36	17/42

Table 1.

Summary of demographics, clinical features, investigations, management and mortality of proximal large bowel volvulus

Plain abdominal radiograph findings may indicate faecal loading and extreme dilated bowel loops. Barium enema findings include the classic “bird’s beak” deformity representing the complete occlusion of intestinal lumen as a result of the volvulus (Figure 8).

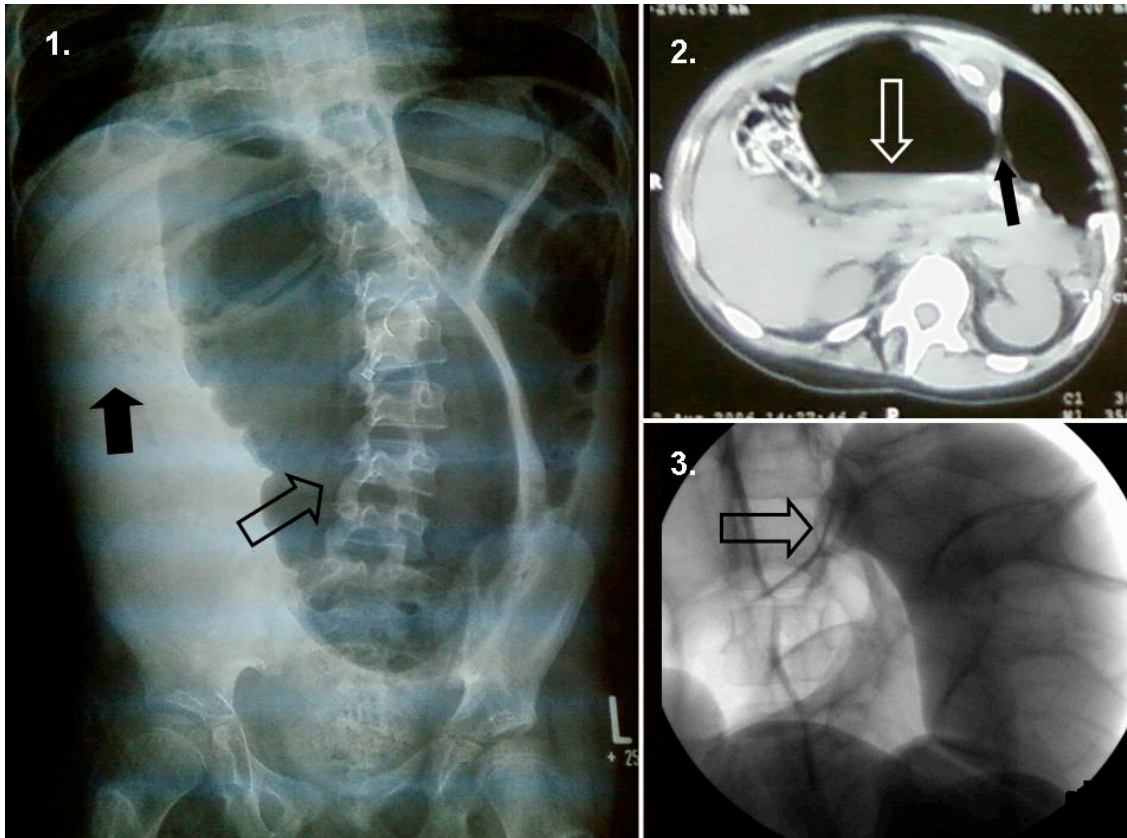


Figure 8.

Image 1. and Image 2. belong to the same patient, who had neurodevelopmental delay, chronic constipation. The extremely dilated large bowel (not only caecum, but ascending, transverse and descending colon as well) was loaded with faeces. The volvulus resulted in an extremely dilated and necrotic caecum. The ascending colon was involved half way up to the hepatic flexure. The rest of the colon was dilated as well, but fully viable. Due to the chronic constipation and faecal loading the twisted colon was more dilated than the intestine proximal of the obstruction.

Image 1: Plain abdominal film showing large bowel distension. One arrow points to the distended bowel loop, while the other points to the faecal impaction. Fine gas pattern can be seen in the transverse colon and rectum. This indicates massive faecal impaction and dilatation.

Image 2: CT scan demonstrating large bowel distension with an arrow pointing to the air-fluid level. The “septum” seen between the dilated air fluid filled loops suggests volvulus.

Image 3: Barium enema showing the classic ‘bird’s beak’ deformity in another child with caecal volvulus including transverse colon. The arrow points to the bird’s beak deformity [28].

As the condition is so rare, its diagnosis is often delayed and most if not all require surgical intervention with simple detorsion with or without fixation to the retroperitoneum, bowel resection followed by a temporary stoma or primary anastomosis. The caecum is involved in 76% of cases of proximal large bowel volvulus, therefore often the ileocaecal valve is at risk of being resected intra-operatively if the ischaemia has progressed to such an extent that the bowel becomes non-viable (Figure 9).

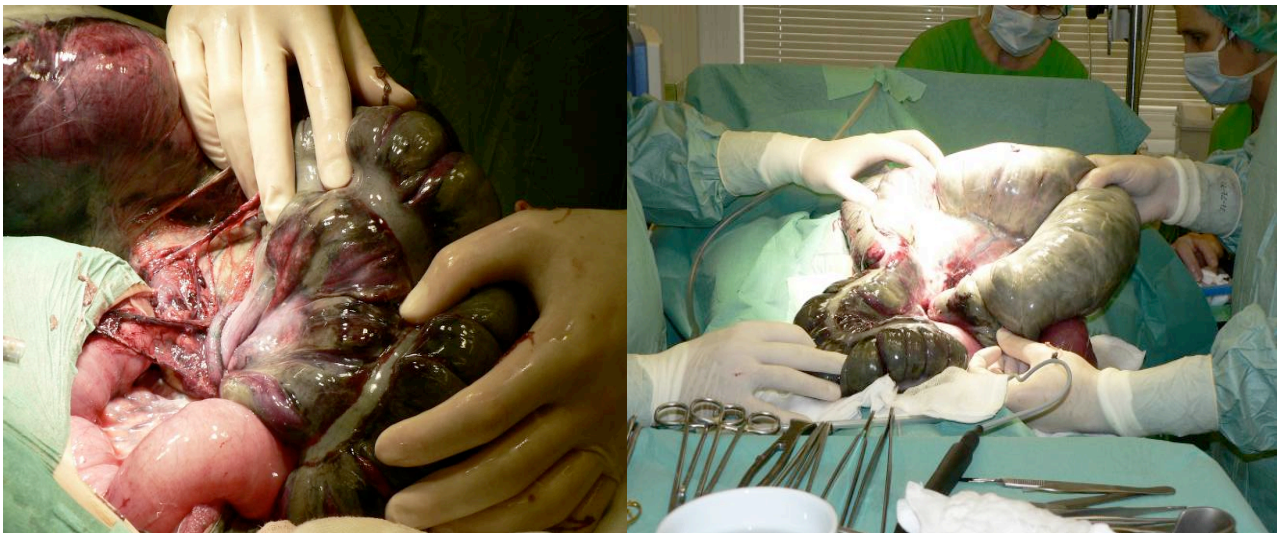

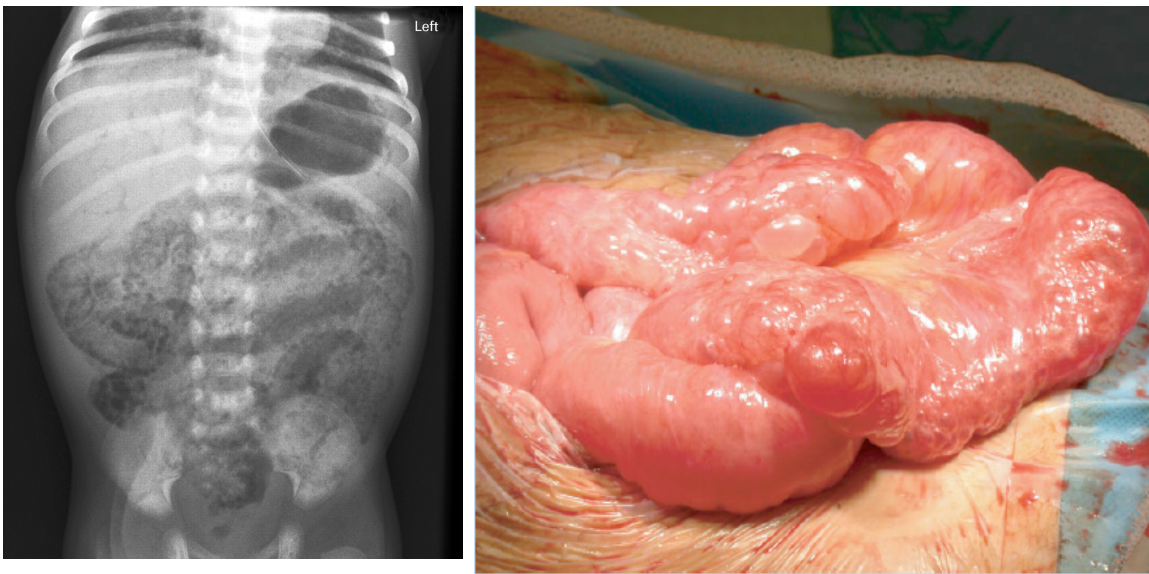
Figure 9.

Intraoperative images of large bowel volvulus. Note the extreme dilatation of the impacted colon, necrosis is seen. After untwisting the volvulus the degree of dilatation-impaction can be seen on the right image. The operation has been performed at the Paediatric Surgical Department, University of Debrecen.

The overall mortality from this condition in children has been shown to be 14% [28], which may be a consequence of a delay in the diagnosis and the fact that children with proximal large bowel volvulus tend to have comorbid conditions like severe neurological impairment that predisposes them to a poor post-operative course.

2.3.2.2.3. Necrotising enterocolitis

Necrotising enterocolitis (NEC) was first described by W.E. Berdon et al in 1964. NEC is the most common gastrointestinal emergency in the newborn infant, and is a result of ischaemic necrosis of the intestinal mucosa. It is associated with inflammation, invasion of enteric gas forming organisms, and dissection of gas into the bowel wall and portal venous system (Figure 10).



A

B

Figure 10.

A: Plain film showing Bell stage II NEC with massive pneumatosis intestinalis and portal venous gas. B: Intra-operative picture showing pneumatosis intestinalis.(source: google image)

NEC occurs in 1 to 3 per 1000 live births and is seen predominantly in premature infants with an incidence of about 6-7% in very low birth weight (VLBW) infants (birth weight < 1500g) [67]. It affects males and females equally and involves the terminal ileum

in 60 to 75% of patients [39]. The mortality of NEC is inversely proportional to the weight at birth, approaching 90% in infants less than 1000g at birth [58].

Ischemia-reperfusion, and infection play a major role in the pathogenesis of NEC, but the exact mechanism remains unknown. It is probably a heterogenous disease resulting from multiple factors that result in mucosal injury in a susceptible host.

NEC can be classified into three stages according to the Bell staging criteria, based on the severity of systemic, intestinal and radiological findings. In stage I (suspected disease), there are mild systemic and abdominal signs and the abdominal radiograph may be normal or show mild dilatation. In stage II (definite disease) the patient has laboratory changes (metabolic acidosis, thrombocytopenia) and specific radiological signs (pneumatosis intestinalis or portal venous gas). In stage III (advanced disease), there are severe systemic signs (hypotension), and severe laboratory signs (DIC). Additionally the child may have marked abdominal distension and be peritonitic with evidence of pneumoperitoneum on the abdominal radiograph [39].

Current surgical options for the management of NEC include peritoneal drainage, proximal diverting stoma, resection with enterostomies, and resection with primary anastomosis. Infants with Stage III NEC affecting the ileocaecal region may undergo resection with stoma formation or a primary anastomosis.

Interestingly NEC more commonly affects the terminal ileum [39], which may compromise the normal function of the ileocaecal junction and predispose to its loss during surgical intervention. In addition to this, intestinal stricture post resolution of NEC, as a

result of fibrosis and scarring in the ischaemic tissue, commonly affects the ileocaecal valve. Resection of the stricture usually leads to the loss of the valve.

In a retrospective case series of infants undergoing surgery for NEC conducted at Great Ormond Street Hospital (UK's leading children's hospital), 40 out of 83 infants (48%) underwent resection of the ileocaecal valve. There were no significant differences in gestational age, birth weight, and age at onset of NEC between infants who had the ileocaecal valve resected and those that did not. Surprisingly there was no difference in survival rate between the two groups [26]. This may be due to the fact that most patients did not have Short Bowel Syndrome, hence no difference in mortality, however there may have been a significant difference in morbidity such as chronic diarrhoea, had they looked into it.

2.3.2.2.4. Crohn's disease

Crohn's disease (CD) is a chronic, idiopathic transmural inflammation that can affect any part of the gastrointestinal tract. The disease was first described in 1904 by the Polish surgeon Antoni Lesniowski and then later in 1932 by the American Gastroenterologist Burrill Benrnard Crohn, after whom the disease was named. The only prospective national survey of IBD in children aged less than 16 years in the UK showed the incidence to be 5.2 per 100,000 individuals per year, with a mean age at diagnosis of 11.9 years [62]. The incidence of Crohn's disease has been shown to double from 3.5 to 6 per 100,000 individuals per year from 1997 to 2006, in South Ontario, Canada [37]. Abdominal pain, diarrhoea and weight loss were considered to be the classic triad of CD but now only a minority present in this way. A very large population based survey of childhood CD in the UK found that the majority (72%) of patients complain of abdominal pain [61].

Studies have shown the ileocolic region is one of the most common anatomical sites to be afflicted in children who have Crohn's disease [53]. Surgery is rarely indicated except for perforation, abscess or fistula formation and for severe stricture (Figure 11), but the ileocaecal region is often subjected to resection and primary anastomosis with loss of the ileocaecal valve.

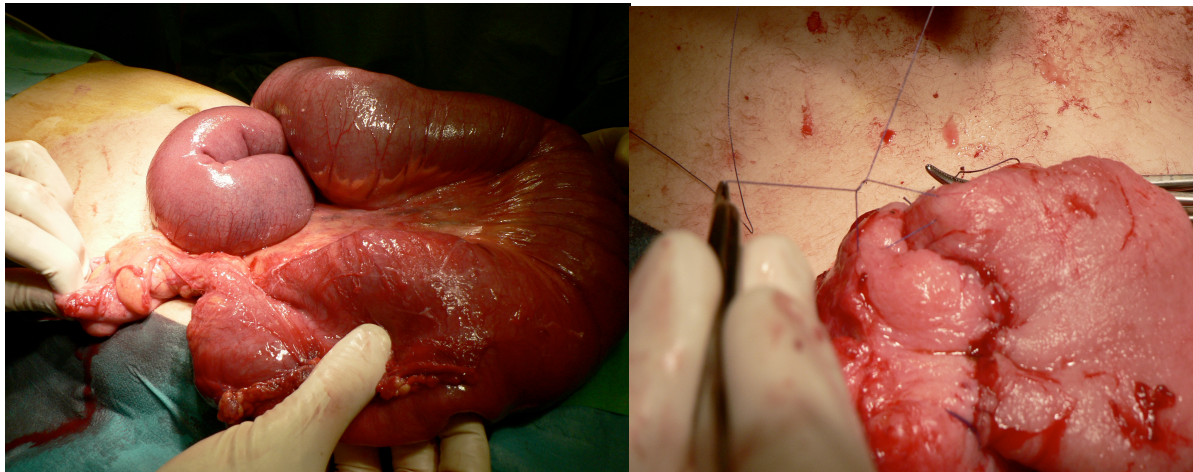


Image 11.

Stricture at the ileocaecal junction of a patient with CD caused bowel obstruction. Resection and end to side intussuscepted double layer ileo-colic anastomosis was performed to replace ICV. On the left dilated small bowel loops and the stricture at the ICV. The second layer of sutures of the end-to-side intussuscepted ileo-colic anastomosis. Procedure was performed at the Paediatric Surgical Department, University of Debrecen.

Resection of the ileocaecal valve may result in colo-ileal reflux and colonisation of the small bowel with colonic micro-organisms, which increase small intestinal permeability and precede clinical relapse of CD [54]. Bakkevoold conducted a prospective study between 1993 and 2003, looking at the effect of a small bowel nipple valve anastomosis on the clinical recurrence rate in the neoterminal ileum [7] after ileocaecal or ileocolic resection for CD. The recurrence rate in the neoterminal ileum after 1, 3, 4 and 5 years was 11%, 20%, 23% and 24% respectively. These recurrence rates were significantly less than previously

published rates after a standard anastomosis following ICV resection. Rutgeerts et al [60] and Olaison et al [54] found clinical anastomotic recurrence of 20-37% after 1 year and 34-86% after 3 years. The German Advanced Surgical Treatment Study Group conducted a randomised controlled trial looking at whether stapled side-to-side anastomosis, compared to hand-sewn end-to-end anastomosis, results in a decreased recurrence of Crohn's disease following ileocolic resection (primary endpoint). The secondary endpoint was to focus on the early postoperative results comparing both methods. There was no difference between the two types of anastomosis in terms of the early postoperative complications (e.g. bleeding, wound infection, anastomotic leak, first postoperative stool, duration of hospital stay) [70]. The study was terminated early due to insufficient patient recruitment, therefore the primary endpoint was not attained.

2.3.2.2.5. Complicated appendicitis (appendix mass)

An appendix mass is formed by an inflamed appendix that is wrapped up by the omentum and adjacent loops of bowel. The appendix might be perforated, however the purulent fluid is generally well contained within the mass, preventing generalised contamination of the peritoneal cavity. A recent meta-analysis estimated that approximately 9% of all children with acute appendicitis have an inflammatory mass at presentation [3]. Others suggest that the occurrence of a mass is more frequent, approaching 30%, under 5-years-of age [33].

Patients with an appendix mass can present in a variety of ways. Most commonly the patient presents with a 3-4 day history of right iliac fossa pain and fever, with localised but not generalised peritonitis. Examination may reveal a palpable mass in the right iliac

fossa. The diagnosis can be verified by Ultrasound or CT, and ultimately by examination under anaesthesia. Surgical intervention in patients with an appendix mass is considered more hazardous than in simple uncomplicated appendicitis because of the extensive adhesions between the appendix and the surrounding viscera. The inflammatory process will render the wall of the bowel friable and prone to full thickness tears during the dissection. Aggressive surgical intervention may lead to bowel resection i.e. loss of ileocaecal valve. The appendix mass may respond to intravenous antibiotics within 24-48 hrs, and appendectomy can be done more easily and safely [33, 40] after the resolution of the mass. A recent systematic review of the literature has shown that the risk of recurrent appendicitis following a period of conservative management of an appendix mass was 20%, which has led some to argue that an interval appendicectomy should not routinely follow in patients who have settled on conservative management, especially bearing in mind that the risk of operative complication is 3% [40].

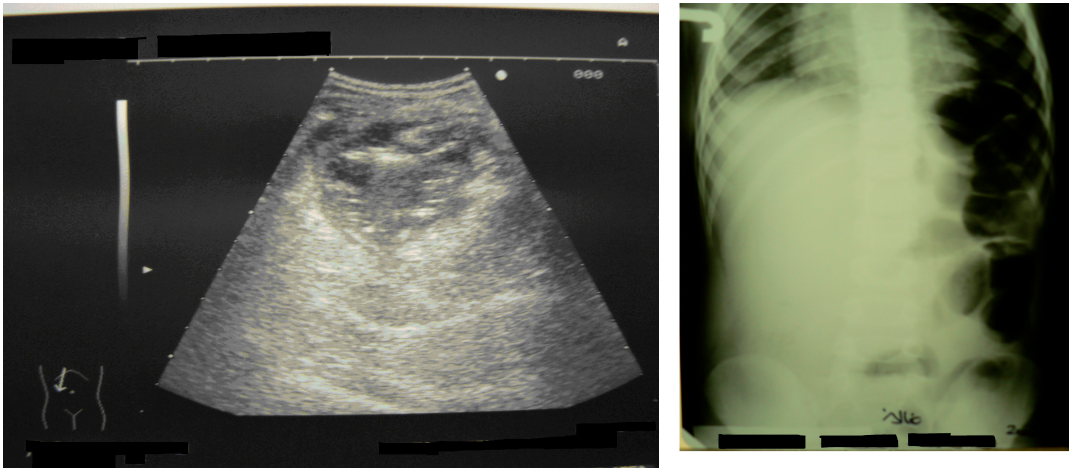


Figure 12.

A: US abdomen showing an area of mixed echogenicity representing an appendix mass. B: Plain abdominal radiograph showing a radio-opacity on the right hand side with displacement of gas filled bowel loops to the left. The radio-opacity represents an appendix mass. These cases have been successfully managed by conservative management followed by laparoscopic appendicectomy at Debrecen University.

2.4. Summary of the clinical importance of the ileocaecal junction

2.4.1. Ileocaecal junction in healthy patients

The anatomy, embryology, and physiology of the ileocaecal valve have been studied in the past, but its importance in clinical practice is still undervalued. The loss of the ileocaecal valve is thought to be generally well tolerated; however there is no actual evidence to be found in the literature. In general not enough attention is paid to prevent its loss. The fact that a few patients with chronic intractable diarrhoea had previously undergone a right hemicolectomy drew the author's attention to the issue. One of the aims of this thesis was to reveal the real incidence of complications seen after ICV loss in otherwise healthy patients.

2.4.2. Ileocaecal junction in Short Bowel Syndrome

According to the literature the role of the ileocaecal valve in Short Bowel Syndrome is controversial. Some have suggested that the presence of the valve reduces the dependence on parenteral nutrition in terms of the frequency of its use in a given time period and its overall duration [8]. Additionally the presence of the ileocaecal valve in patients with SBS is thought to allow the patient to achieve enteral autonomy with a shorter segment of small bowel [21]. Zurita et al 2004 [69], reconstructed the ileocaecal valve following massive intestinal resection by performing an ileocolic invagination secured with sutures. SBS patients with the neovalve showed lower weight loss, lower frequency of stool at 3 months and 1 year, and no bacterial overgrowth, compared to patients that had a simple end-to-end anastomosis following ICV loss.

In a review of 161 patients undergoing bowel resection for NEC, the ICV was not associated with a better survival, a longer duration of TPN or an increase in mortality and morbidity [23]. It has been concluded that the loss of ICV is well tolerated. However in this study the residual bowel length and long term complications e.g. bowel habit, were not commented on. It is likely that there were Short Bowel Syndrome patients among the NEC patients, but because not all of the NEC patients suffered massive intestinal loss (less than 10 % of the patients had pan-intestinal NEC) the conclusion does not necessarily relate to the Short Bowel Syndrome. Further evidence regarding the importance of the valve would support an attempt at preservation and reconstruction of the ICV in Short Bowel Syndrome.

2.4.3. Ileocaecal junction in Crohn's disease

Based on the physiology of the ileocaecal valve it is clear that passage of colonic bacteria into the terminal ileum may cause ileitis. Recognising this and the high recurrence rate of Crohn's disease after ileocaecal resection, Bakkevold undertook a prospective study in which he reconstructed a nipple-like small bowel valve following resection for Crohn's disease. He found that the recurrence rates of Crohn's disease in these patients were significantly less than previously published in the same time period [6, 7]. There is no data regarding relapse of Crohn's disease in children after ICV resection.

2.5. Autologous Gastro-intestinal Reconstructive Surgery (AGIR)

Autologous Gastro-intestinal Reconstructive Surgery has been developed to treat intestinal failure in Short Bowel Syndrome, particularly since intestinal transplantation still carries a significant morbidity and mortality. The survival rate of intestinal transplantation has been improving; 90% at 1yr, 55% at 5yrs and 45-50% at 10 yrs in selected centres, but high dose immunosuppression and serious co-morbidities are still of major concern. Therefore presently AGIR should remain the first line of treatment for severe SBS [19].

There are different target points of surgical intervention in SBS such as increased transit time by using reverse segments, colonic interpositions, and small bowel nipple valves. Other surgical measures include improved peristalsis in grossly dilated adapted bowel by tailoring the lumen and lengthening the bowel length. Relatively little attention has been placed on replacing the ileocaecal valve in AGIR. In this chapter we briefly review the most popular AGIR procedures.

2.5.1. Reverse segments and colonic interpositions

The use of a reversed segment represents a resistance or delay, but not an obstruction. Small bowel loops are isolated on a vascular pedicle, rotated, and anastomosed in a reverse fashion. The antiperistaltic direction will slow down transit. The 180° rotation on the mesentery is not tight and does not cause ischemia [8].

The use of colonic interposition as an adjuvant procedure in the management of short bowel syndrome was first described in 1971 [41]. It utilizes the slower colonic motility to slow transit and to delay nutrient loss, thus allowing a longer mucosal contact for absorption. It is believed that the colon may also take over small bowel mucosal function [8]. The segment

of colon can be inserted pre-jejunal or pre-ileal, resulting in reduced transit time, enhanced vitamin B₁₂, carbohydrate, and fat absorption and an increase in weight gain secondary to a more prolonged exposure of nutrients to the absorbing small bowel mucosa [8, 41].

2.5.2. Lengthening and tailoring procedures

After massive resection the residual intestine tries to adapt to the loss, to improve absorption and increase intestinal transit time. This includes micro- and macroscopic changes, smooth muscle hypertrophy, increases in villus height, crypt depth, proliferation of enterocytes and macroscopic bowel dilatation [8, 35]. At a certain point the increased diameter prevents proper approximation of the bowel walls [19]. This leads to a sloshing motion of the intraluminal contents and disorganised anterograde progression. These dilated segments become potential sites of stasis and bacterial overgrowth. Lengthening and tailoring techniques are designed to correct the two major functional problems of adapted short bowel: stasis leading to bacterial overgrowth and disordered motility [8]. At present the Bianchi longitudinal intestinal lengthening and tailoring (LILT) and the serial transverse enteroplasty (STEP) procedures have gained popularity and have been shown to improve enteral autonomy in patients with short bowel syndrome [10, 42]. However both techniques have their limitations.

2.5.2.1. Longitudinal intestinal lengthening (LILT)

Mr Bianchi (Manchester UK) introduced his technique in 1980. During a LILT procedure the bowel is divided longitudinally along the antimesenteric border. The mesenteric border is divided longitudinally in the midline, passing between the blood vessels.

This results in two fully vascularised hemisegments. The two hemisegment are to be tubularised and then anastomosed isoperistaltically..

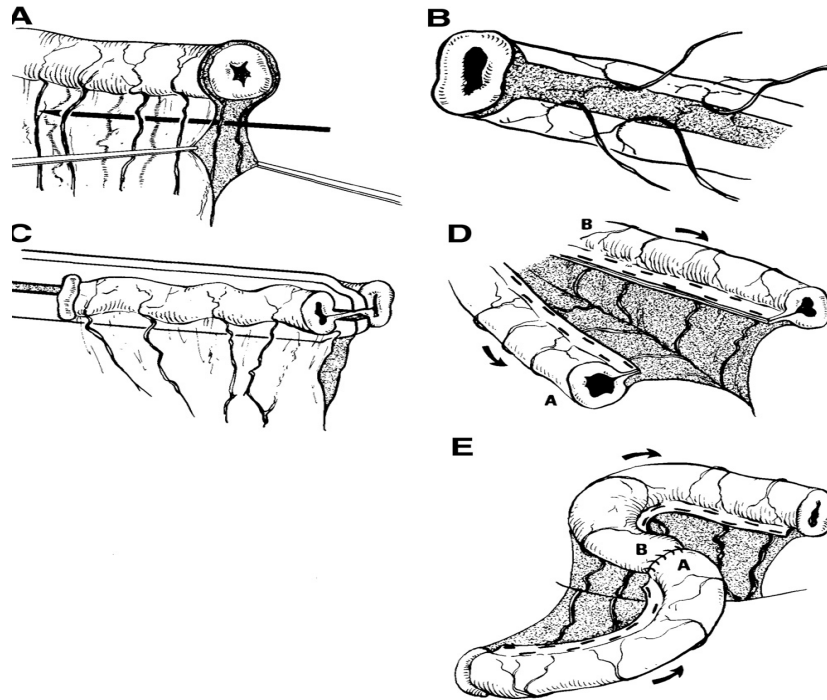


Figure 13

The LILT procedure. (A) Creation of the mesenteric tunnel. (B) View of the divided mesentery. (C) Division of the dilated bowel into 2 hemi-loops. (D) View of the two new bowel hemi-loops. (E) Reanastomosis in an iso-peristaltic manner. [8]

2.5.2.2. Serial Transverse Enteroplasty (STEP)

Serial Transverse Enteroplasty (STEP) was first described by Kim et al 2003 [42] as an alternative to the Bianchi LILT procedure for the surgical treatment of short bowel. GIA stapler is applied sequentially, from alternating and opposite directions, in a transverse and partially overlapping fashion creating a zig-zag like channel of approximately 2 to 2.5cm in diameter. The staplers are inserted through small mesenteric defects between consecutive

blood vessels. The staplers are placed from the 90° and 270° positions (0° being the mesenteric border). The end result is creating a channel of bowel that is both smaller in diameter and longer in length than the original bowel.

The STEP procedure has advantages over the Bianchi LILT in that it is easier to perform; there is no anastomosis, the bowel is never opened, and the mesentery is never jeopardised. Additionally the degree of bowel tapering is customisable; the Bianchi procedure requires a 50% reduction in circumference, whereas with the STEP the channel size and thus the diameter, is determined by the surgeon. One drawback in the STEP procedure is that it disorganises the orientation of the muscle fibres within the intestine. The circular muscle fibres will become longitudinal and the longitudinal fibres will become circular to the flow of intestinal content or axis of the new bowel. It is not clear whether peristalsis recovers after the STEP procedure, or whether the new bowel is just a passive tube (Figure 13).

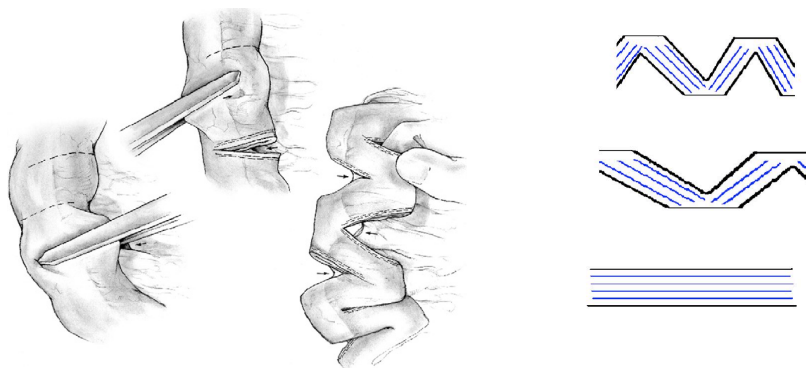


Figure 14

STEP procedure: Staplers applied perpendicular to the bowel in an alternating fashion are used to divide the bowel in a zig-zag fashion, reducing its diameter and increasing its overall length. However altering the orientation of muscle fibers causes the circular fibres to become longitudinal and the longitudinal, circular.

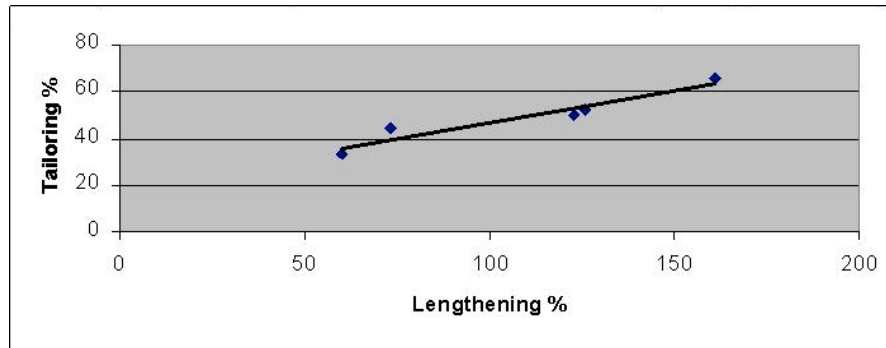
2.5.2.3. Spiral Intestinal Lengthening and Tailoring (SILT)

The SILT is a new concept of the Autologous Intestinal Reconstructive Surgery developed by our team [14]. In SILT a spiral incision is made on the bowel wall then it is stretched along its longitudinal axis and retubularised (Figure 14). The advantage of this technique over the Bianchi's procedure is that it is easier, it does not compromise the mesentery and is customizable (Graph 1). The SILT does not alter the orientation of the muscle fibres to the same extent as the STEP procedure. The SILT procedure allows spiral/oblique orientation of the circular muscle fibres, which is more physiological than the STEP.



Figure: 15

On the left: bowel simulator cut at 60° and tubularised, note the orientation of the circular muscle fibres.
On the right: SILT on ex vivo porcine bowel



Graph 1:

The relation of tailoring and lengthening in SILT model shows how flexible is this procedure

We believe that the SILT will provide an additional and promising alternative to present lengthening and tailoring procedures, which is relatively easy to perform, customizable and leaves less structural change on the functional anatomy on the lengthened bowel. In vivo animal studies are in progress and initial results are very promising (Figure 16).

2.5.3. Ileocaecal valve reconstruction

Although attempts have been made to reconstruct the ICV in the past, its role is still undervalued. The sporadic indication for ICV reconstruction was in Short Bowel Syndrome and Crohn's disease, but no one considered it in otherwise healthy patients.

This is probably due to the technical difficulties and failure of understanding of the real anatomy, physiology and function of the ICV. The surgical techniques used were intussusception-like small bowel nipple valve, submucosal tunnelling and telescope anastomosis, Figure 17 [15].

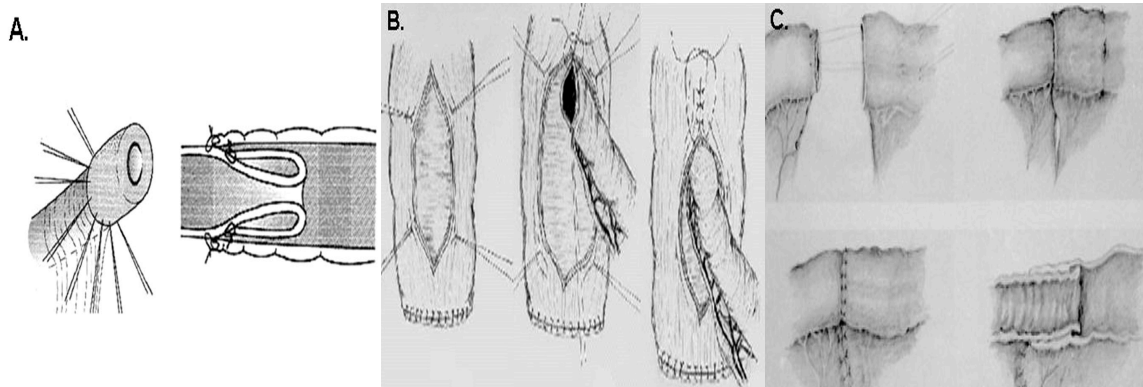


Figure 17

Different ileocecal anastomosis techniques: A: Ricotta valve. B: Meagawa submucosal anastomosis. C: Zurita telescope anastomosis.

These valves were usually able to replace the reflux control, but failed to reproduce anterograde flow control and were not able to fully replace the ICV [15]. Studying its anatomy and neuroanatomy a new concept of ICV replacement emerged. The structure of the neuromuscular components within the ICV suggested that the ICV does not look like a classical sphincter as was previously suggested [46], the valve is rather a result of a simple intussusception of the terminal ileum into the caecum. This observation led to the idea that the ICV could be replaced more physiologically by an ileo-caecal end-to-side intussusception like the ileo-colic anastomosis seen in Figure 18.

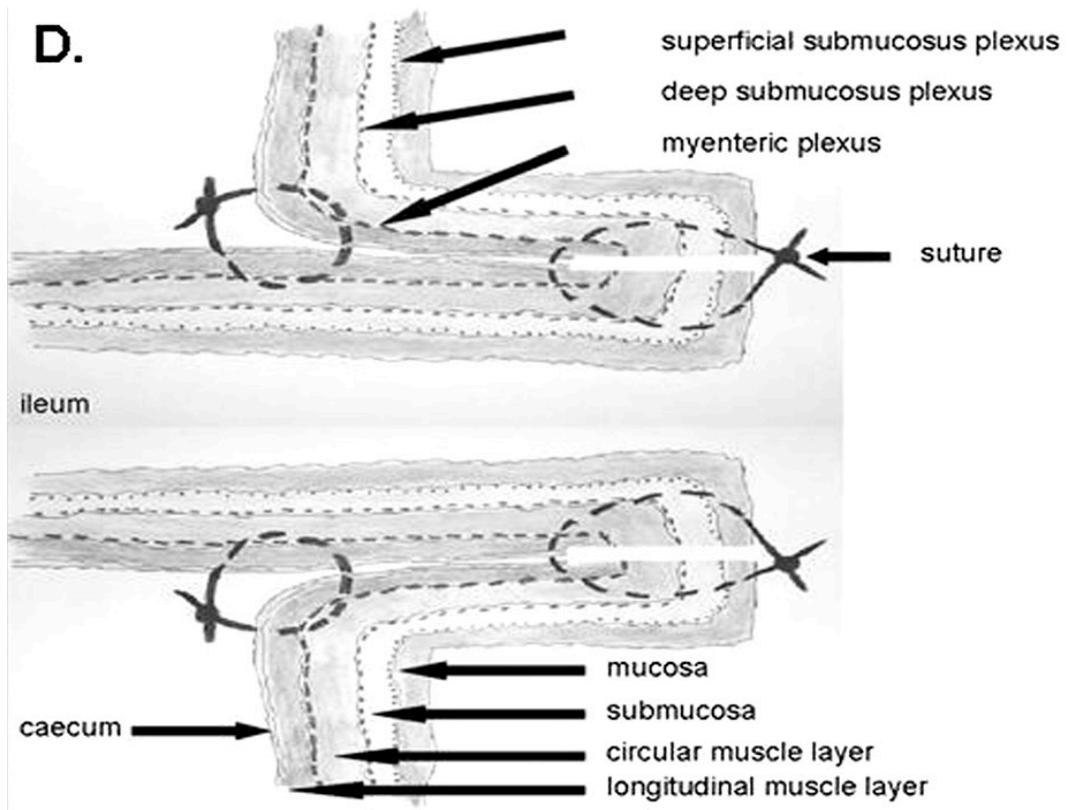


Figure 18

New design of ileocaecal anastomosis by suturing the ileum end to the side of the caecum and telescoping the anastomosis into the caecum with 2nd layer serosal sutures [15].

3. AIMS

Our main goal was to find more evidence to reinforce the clinical importance of the ileocaecal valve and justify its preservation and reconstruction.

3.1. Analysis of the occurrence of surgical diseases leading to loss of the ileocaecal junction

Our first aim was to evaluate the different surgical diseases that may result in the loss of the ileocaecal valve, either directly or indirectly in order to shed light on possible prevention.

3.2. Analysis of the importance of the ileocaecal junction in healthy patients

We aimed to investigate the importance of the ileocaecal valve in patients that are otherwise healthy and not suffering from Short Bowel Syndrome and Crohn's disease, by studying the clinical outcome in the patients who lose their ileocaecal valve and comparing them to a control group of patient whose ICV is preserved.

3.3. Analysis of the importance of the ileocaecal junction in Short Bowel Syndrome

We aimed to evaluate the importance of the ileocaecal valve in patients with short gut by comparing the survival in patients without an ileocaecal valve to those in whom it was preserved.

3.4. Analysis of the importance of the ileocaecal junction in Crohn's disease

We aimed to evaluate the importance of the ileocaecal valve in patients with Crohn's disease by determining whether or not the risk of recurrent terminal ileal disease is higher in patients without an ileocaecal valve compared to those in whom it has been preserved.

4. MATERIAL AND METHODS

4.1. Occurrence of surgical diseases leading to loss of the ileocaecal junction

4.1.1. Database

The case notes of children that had undergone surgery at Royal Manchester Children's hospital was the source of our data.

4.1.2. Data collection

Between 1998 and 2010, the case notes of children who underwent surgery leading to a loss of the ileocaecal valve at Royal Manchester Children's Hospital were analysed retrospectively. The cases notes were retrieved by the Audit Department at the children's hospital by identifying patients that had the following operations: hemicolectomy, limited hemicolectomy, colectomy, caecum resection, and large bowel resection.

4.1.3. Data analysis

We collected data on the patient demographics and the various pathologies that led to the loss of the ileocaecal valve, whether pre- or post-operatively. We took note of the type of surgical intervention undertaken in each patient.

4.2. The ileocaecal junction in healthy patients

4.2.1. Database

The case notes of children that had undergone surgery at Royal Manchester Children's hospital was the source of our data.

4.2.2. Data collection

Between 1998 and 2010, the case notes of 99 children who underwent resection of the right hemi-colon and terminal ileum at Royal Manchester Children's hospital were reviewed retrospectively. The patients were categorised into three groups: *Group 1*: resection of the ileocaecal valve (limited right hemicolectomy with less than 10cm resection of ileum and less than 10cm of caecum), *Group 2*: right hemicolectomy, with resection of the terminal ileum, up to 10cm, and more than 10cm but less than half of the length of the colon, and *Group 3*: resection of the terminal ileum by more than 10cm but less than 25cm (Figure 19). The patients that were excluded included those who had no follow-up and patients with underlying pathology associated with chronic diarrhoea such as Crohn's disease and short gut.

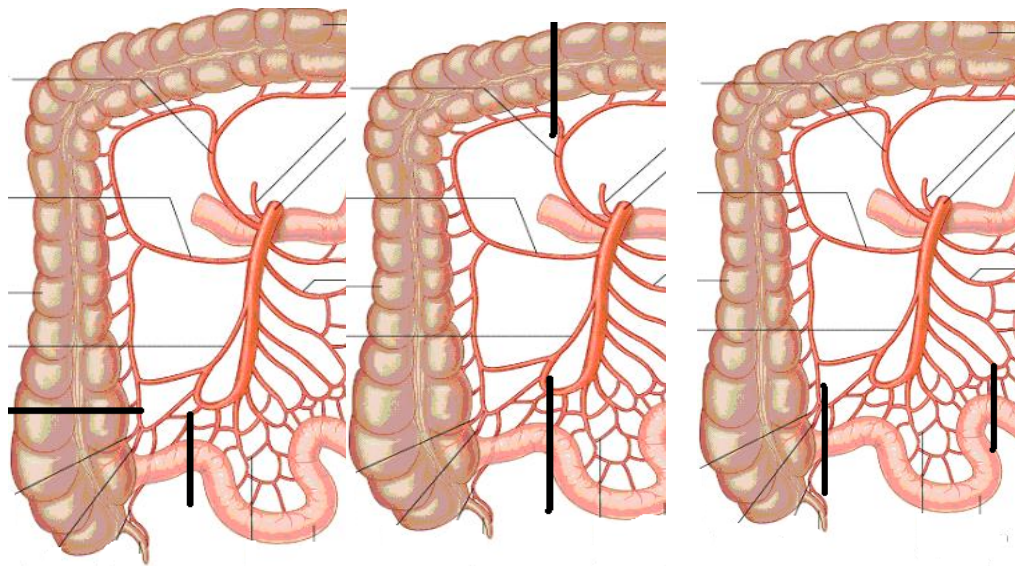


Figure 19.

Group 1: Limited hemicolectomy (ICV) , ileum <10 cm, colon < 10 cm **Group 2:** Hemicolectomy , ileum <10 cm, 10 cm< colon < half colon length **Group 3:** Limited ileal resection ,10 cm< ileum < 25 cm

4.2.3. Data analysis

We looked at the patient demographics, the type of surgery undertaken, whether or not they developed chronic diarrhoea and for how long. In addition we evaluated the length of post-operative follow-up.

4.2.4. Statistics

A Pearson Chi-square test was used to compare the three groups to ascertain if there was a statistically significant difference in the number of patients developing chronic diarrhoea postoperatively.

4.3. The ileocaecal junction in Short Bowel Syndrome

4.3.1. Database

The database of the Paediatric Autologous Bowel Reconstruction and Rehabilitation Unit (PABRRU) at the Royal Manchester Children's Hospital was retrospectively analysed. Records of the patients with short gut who had undergone a LILT (longitudinal intestinal lengthening and tailoring) procedure from 1981-2006 have been reviewed with the permission of the clinical director of the unit (Permission attached in the appendix)

4.3.2. Data collection

We collected data under two main groups of patients with short gut, those that had survived (group A) and those that died (group B). In each group we looked at the length of the remaining small bowel, whether or not the ICV was present, and the extent of the large bowel that remained.

4.3.3. Data analysis & Statistics

A Fisher's exact test was used to determine if there was a significant difference in the proportion of patients with an intact ICV between the survival and non-survival group. An unpaired t-test was used to compare the mean length of small bowel between the survival and non-survival group. Additionally an unpaired t-test was used again to compare the mean length of small bowel in the survival group between patients with an intact ICV and patients without an ICV.

4.4. The ileocaecal junction in Crohn's disease

4.4.1. Database

The case notes of children that had undergone surgery at Royal Manchester Children's hospital was the source of our data.

4.4.2. Data collection

Between 1998 and 2010, the case notes of 99 children who had undergone a right hemicolectomy at Royal Manchester Children's Hospital were reviewed. The patients with a pre-operative diagnosis of Crohn's disease which was later confirmed on histology post-operatively were included.

4.4.3. Data analysis

We looked at patient demographics, type of surgery, length of follow-up, frequency of relapse and whether or not they developed chronic diarrhoea or failure to thrive post-operatively.

5. RESULTS

5.1. Occurrence of surgical diseases leading to loss of the ileocaecal junction

A total of 74 children who had undergone a right hemicolectomy, with subsequent loss of the ileocaecal valve, were included in the study. The male to female ratio was 1.4:1, and the mean age of the patients was 3.6 years (range 0 – 17 years). The various pathologies that led to the operative intervention along with the number of children that had these pathologies (in bracket) are as follows: intussusception (17), necrotising enterocolitis (16), appendix mass (8), Crohn's disease (7), intestinal duplication cyst (5), colonic volvulus (5), intestinal perforation (4), colonic atresia (2), ileal atresia (2), ileal and colonic atresia (2) lymphoma (1), colonic angiodysplasia (1), meconium ileus (1), intestinal stricture (1), gastroschisis with a detached caecum (1) and bowel obstruction secondary to an adhesive band (1). Data are summarised in Table 2.

Demographics	Number
- mean age (range)	3.6 (0 – 17)
- male:female ratio	1.4:1
Pathology	
- intussusception	17
- necrotising enterocolitis	16
Appendix mass	8
Crohn's disease	7
Intestinal duplication	5
Colonic volvulus	5
Atresia- colonic- ileal- ileal and colonic	6 , 2-2-2-
Intestinal perforation	4
Lymphoma	1
Colonic angiodysplasia	1
Meconium ileus	1
Intestinal stricture	1
Gastroschisis	1
Adhesive small bowel obstruction	1

Table 2:

Summary of patient demographics and pathologies leading to loss of IVC.

5.2. The ileocaecal junction in healthy patients

Group 1: 26 patients underwent a limited right hemicolectomy. Chronic diarrhoea was documented in seven cases (27%). The duration of chronic diarrhoea varied between a minimum of 2 and a maximum of 120 months, an average 30 months. The age range at the time of surgery was 0-15 years. The primary diagnoses were intussusception (13), appendix mass (6), terminal ileal stricture (1), duplication cyst (3), colonic atresia (2), and adhesive bowel obstruction (1).

Group 2: 22 patients underwent an extended right hemicolectomy as previously defined. Chronic diarrhoea was reported in six cases (27%). The duration of diarrhoea was 6-60 months, an average of 30 months. The age range at the time of surgery was 9 days – 15 years. The primary diagnoses were necrotising enterocolitis (16), intussusception (2), lymphoma (1), colonic atresia (1), caecal perforation (1), and cystic mass in the ileocaecal area (1).

Group 3: 13 patients underwent resection of the terminal ileum, and none developed diarrhoea. The age range at the time of surgery was 2 days – 11 years. The primary diagnoses were intussusception (7), adhesive small bowel obstruction (2), ileal perforation (1), ileal cyst (1), meconium ileus (1), and duplication cyst (1).

In terms of the number of patients developing chronic diarrhoea, there was a statistically significant difference between Group 1 and Group 3 ($p = 0.0038$) and between Group 2 and Group 3 ($p = 0.043$). But there was no significant difference between Group 1 and Group 2 ($p = 0.947$).

	Group 1	Group 2	Group 3
Resection	Limited right hemicolectomy (ICV)	Right hemicolectomy	10cm < Ileal resection < 25cm
Total number of patients	26	23	13
Age at surgery	0-15 years	9 days – 15 years	2 days – 11 years
Chronic diarrhoea	7 (27%)	6(26%)	0 (0%)
Duration of diarrhoea in months (mean)	2-120 (30)	6-60 (30)	0 (0)
p value	G1 vs G3 = 0.0038	G2 vs G3 = 0.043	
	G1 vs G2 = 0.947		

Table 3:

Summary of the three different groups and the statistically significant difference in the development of chronic diarrhoea between the three groups.

5.3. The ileocaecal junction in Short Bowel Syndrome

Thirty four patients underwent bowel lengthening in the Paediatric Autologous Bowel Reconstruction and Rehabilitation Unit (PABRRU) in the Royal Manchester Children's Hospital between 1981 and 2006. Twenty one patients survived while 11 patients died within 5 years after the procedure. Data are summarised in table 4.

Patients survived			Patients did not survived		
Patient	Small bowel length (cm)	ICV retained	Patient	Small bowel length (cm)	ICV retained
1	46	Yes	1	35	No
2	45	Yes	2	30	No
3	45	No	3	33	Yes
4	98	No	4	39	Yes
5	45	No	5	58	No
6	38	Yes	6	33	No
7	90	No	7	60	No
8	40	No	8	36	No
9	110	No	9	25	No
10	34	Yes	10	28	No
11	73	No	11	90	no
12	30	Yes			
13	50	Yes			
14	70	No			
15	60	No			
16	110	No			
17	40	No			
18	60	No			
19	100	No			
20	120	No			
21	35	No			
22	110	No			
23	68	No			

Table 4:

Patients with Short Bowel Syndrome who had survived and did not survive.

Proportion of ICV in the survival and non-survival groups:

Six patients of the 23 who survived did not lose the ICV, 17 of the 23 patients survived without ICV. Only two of the 13 non-survival patients had an intact ICV and the remaining 11 of 13 died without an ICV. There was no statistically significant ($p = 0.38$) difference between the groups in terms of the proportion of patients with an intact ICV (Figure 21.).

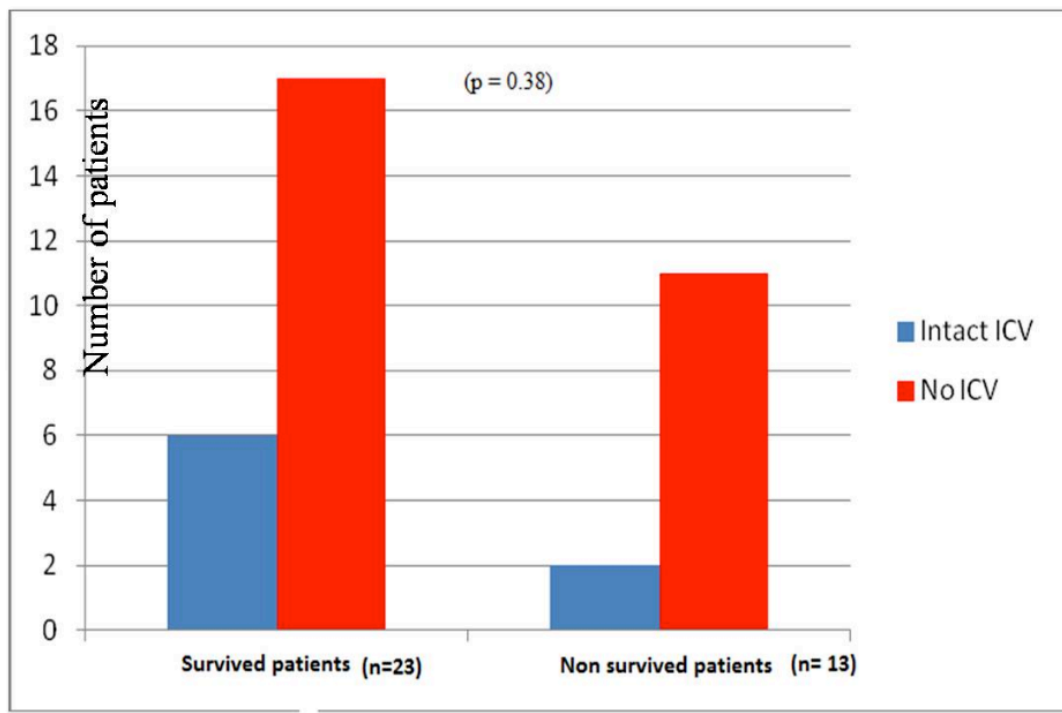


Figure 20.

Number of patient with our without ICV in survival and non-survival groups. There is no significant difference in the proportion of intact ICV between the two groups.

Small bowel length in the survival group if ICV present vs. missing:

A significantly ($p = 0.002$) shorter bowel length was required to survive if the ICV was present versus if the ICV was missing. ($40.5 \pm 7.74\text{cm}$) vs. ($74.9 \pm 29.0 \text{ cm}$). Results are shown in Figure 21

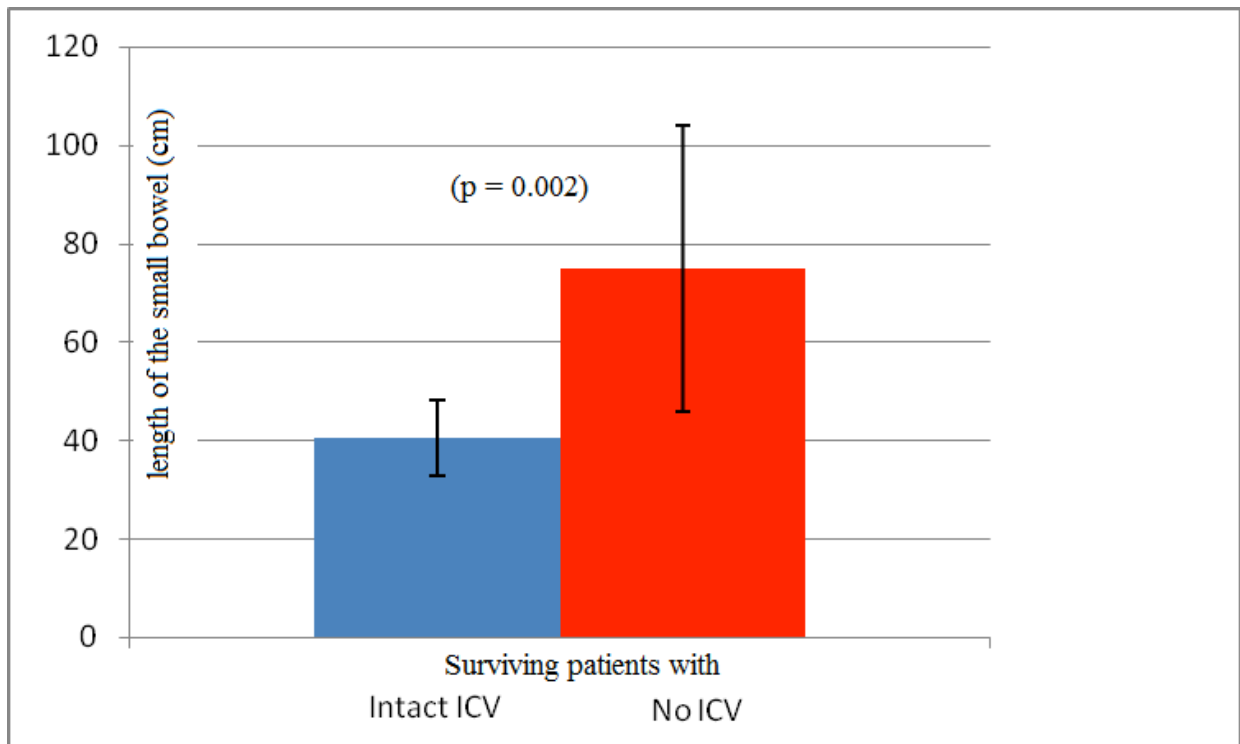


Figure 21.

The mean length of the small bowel (cm) in the survival group with and without ICV

Small bowel length in the non- survival group if ICV present vs. missing:

In the non-survival group the mean length of small bowel was $36 \pm 4,24$ cm with an intact ICV and 43.88 ± 21.35 cm without an ICV.

An unpaired t test showed that there was no significant difference between these two groups ($p = 0.629$). (Figure 22.)

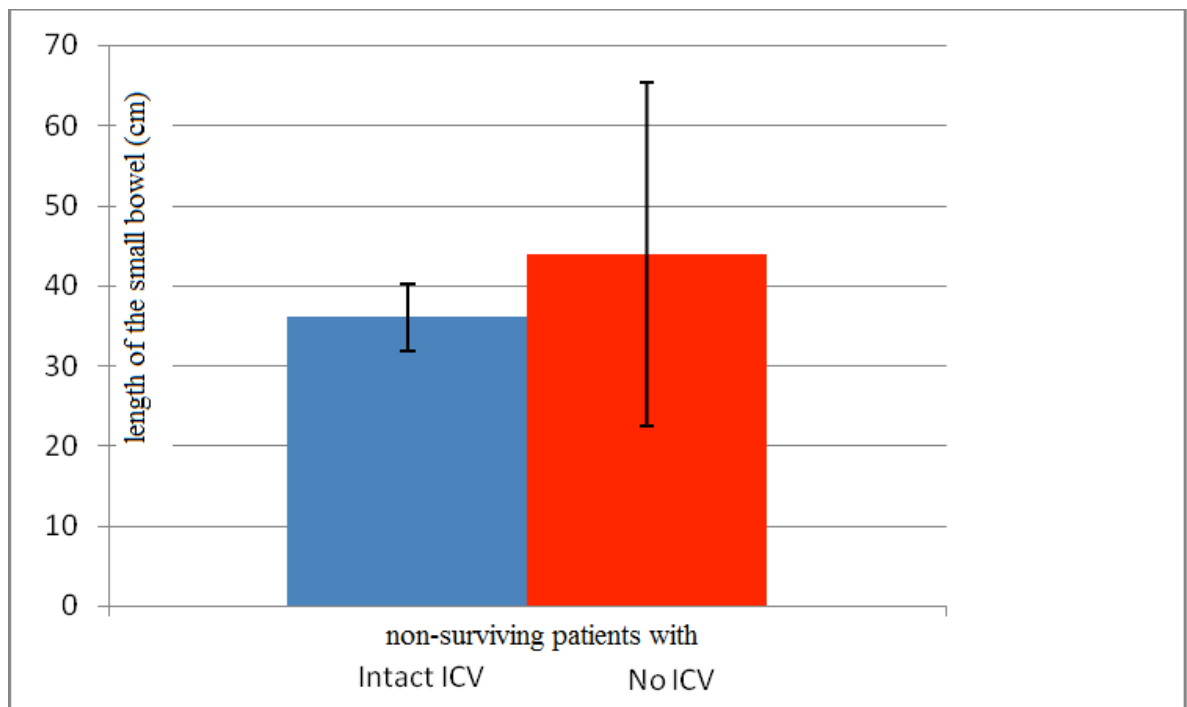


Figure 22.

The mean length (cm) of the small bowel in the non-survival group with and without an intact ICV

The length of small bowel in the survival group vs. the non-survival group:

The mean lengths of small bowel (\pm SD) in the survival and non-survival groups were 66.0 ± 32.5 cm and 42.5 ± 19.4 cm respectively (Figure 23). An unpaired t-test with Welch correction showed that patients in the survival group had a significantly longer segment of small bowel ($p = 0.0098$)

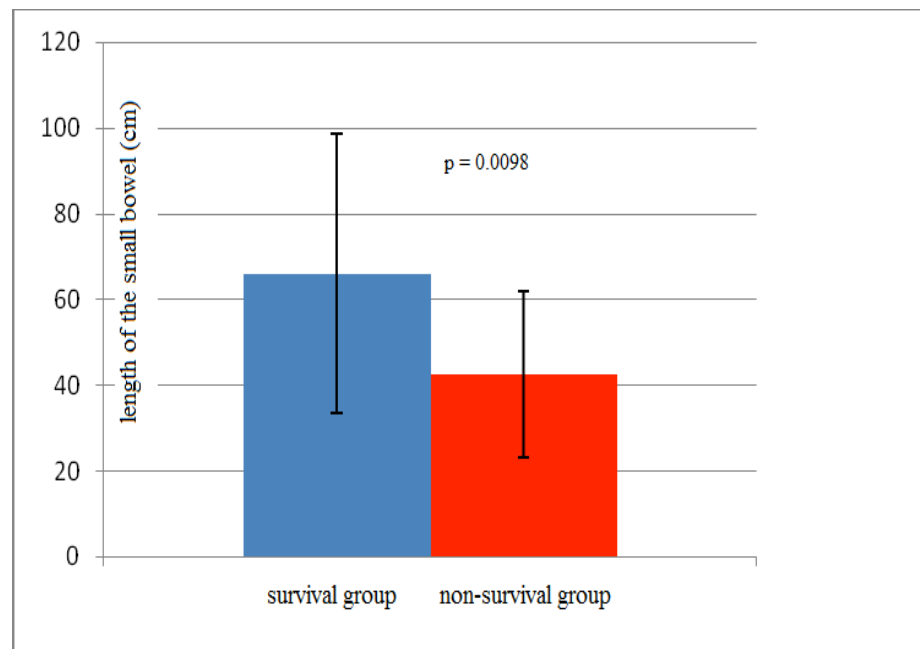


Figure 23.

The mean length of small bowel in the survival group vs the non-survival group

The minimum length of small bowel in the survival group with and without an ICV::

In the survival group the minimum length of small bowel was 30cm in patients with an intact ICV and 35cm in patients without an ICV (Figure 24.)

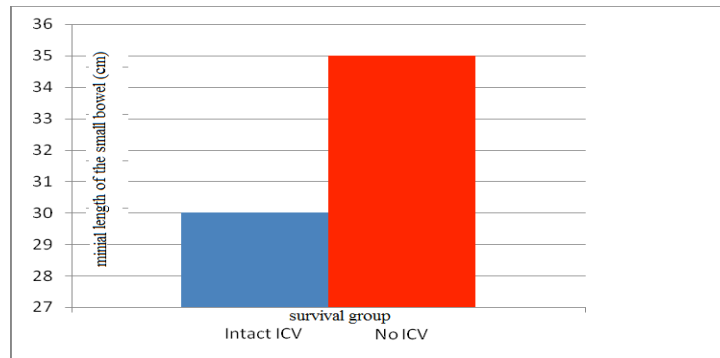


Figure 24

The minimum length (cm) of small bowel in survival group.

The maximum length of small bowel in the non- survival group with and withoutan ICV::

In the non-survival group the maximum length of small bowel was 39cm in patients with an ICV and 90cm in patients without an ICV.

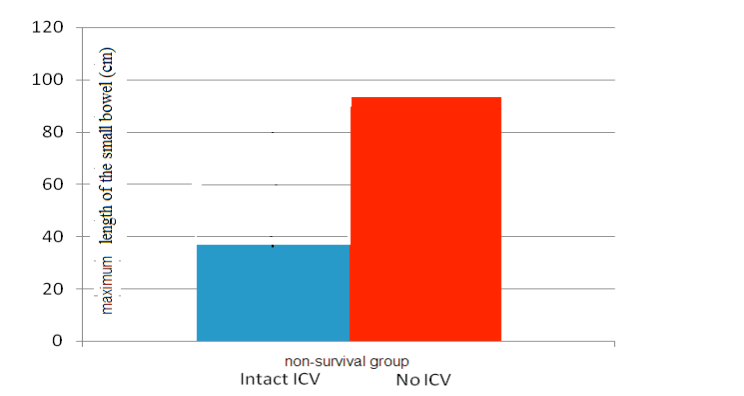


Figure 25

The maximum length (cm) of small bowel in non- survival group

5.4. The ileocaecal junction in Crohn disease

There were only 6 patients with an underlying diagnosis of Crohn’s disease who underwent a right hemicolectomy with a simple end to end anastomosis without reconstruction of the ileocaecal valve. Five were male, with a median age of 14.5 years (range 5 – 15 years) and a median follow-up of 18 months (range 12 – 60 months). Post-operatively 4 patients developed chronic diarrhoea, 2 patients had failure to thrive and three patients developed recurrent Crohn’s disease. The data is summarised in Table 6.

Patient	Sex	Age (yrs)	Length of follow-up (months)	Relapse of Crohn’s disease (time frame postop)	Failure to thrive	Chronic diarrhoea
1	m	14	24	no	no	no
2	m	11	60	yes (1yr, 5yrs)	no	yes
3	m	5	12	no	no	no
4	m	15	48	yes	yes	yes
5	m	14	12	yes (1 yr)	no	yes
6	f	14	12	no	yes	yes

Table 6:

Summary demographics, and postoperative complications in patients with CD undergoing a right hemicolectomy.

6. DISCUSSION

6.1. Occurrence of surgical diseases leading to loss of the ileocaecal junction

There are a number of congenital and acquired conditions that can lead to a loss of the ICV. Our data looking retrospectively at the children who had undergone surgery that involved excision of the ICV between 1998 and 2010, identified intussusception (22%), necrotising enterocolitis (21%), appendix mass (10%) and Crohn's (9%) disease as being the four most common pathologies. This is significant because these pathologies have a relatively high incidence in various age groups.

Intussusception is the commonest cause of intestinal obstruction in infants with an incidence of 1.4 – 4 per 1000 live births. The primary site of intussusception is at the ileocaecal junction hence it is no surprise that this may lead to necrosis of the ICV [18]. According to our data the mean age of intussusception was 7 months (range 0 – 75months) means the primary intussusception (with no lead point) is more likely to result in loss of the ICV. However in the vast majority of the cases reduction of the intussusception under radiology guidance is possible, but surgery may be required if conservative management is unsuccessful and the intussuscepted bowel is stuck in the colon. Intraoperatively the manual reduction technique of pushing the apex of the intussusceptum out of the intussuscipens, and not simply pulling at it distally, needs to be considered more thoroughly in light of the adverse outcomes of losing the ICV. The surgical decision to remove or leave the compromised ICV may be influenced by our study stressing the importance of the valve. Introducing a combined antibiotic prophylaxis, closer observation, longer postoperative fasting time or TPN may aid surgeons in taking the decision to leave a not severely

compromised ICV or make attempt to reconstruct tears or perforations at the ileocaecal junction.

Necrotising enterocolitis is the most common gastrointestinal emergency in the neonatal period [incidence of 1 – 3 per 1000 live births]. The median age of our patients was 1 month (range 0 – 6 months). It has been suggested that NEC usually starts at the ileocaecal junction [39]. This may explain the high frequency of resection of the ICV in acute NEC. The primary site of stricture that is frequently seen post NEC is the ICV. This may be another reason for ICV resection. The GOS study found no difference in survival in NEC after ICV resection, and even less postoperative strictures were seen after removal of the ICV [26], however no long term follow up on bowel habit was evaluated. The morbidity of patients with NEC requiring surgical intervention is high. Taking the mildest risk to save ICV does not seem appropriate. Elective reconstruction of the valve after recovery seems to be a better option.

Patients with spontaneous intestinal perforations seen in this study were newborns with a median age of 6.5 days (range 3 – 20 days). These cases might be considered as NEC, however recently it has been considered as a separate entity [48].

Acute appendicitis is the commonest surgical emergency in children overall (life time risk of 6.7% for girls and 8.7% for boys [1]. Surprisingly complicated appendicitis was the third most common cause of ICV loss in our study. This may come from the absolute frequency of appendicitis compared to intussusception or NEC. However resection of the ICV is not a frequently performed practice even in complicated appendicitis. There are only 8 patients identified in a 12-year period. Considering the number of appendectomies performed in this large centre, approximately 200 appendicectomies per year, this is not a

large number (0.003 per year). Unexpected complications during the surgery, including a massive appendix mass, and injury to the ileum or caecum, and the belief that the resection of the ICV is well tolerated may have made the operating surgeon resect the ileocolic junction. It is known that in advanced appendicitis, especially with an appendix mass, the bowel loops are adherent and their wall is oedematous and fragile. Therefore separation of the mass may lead to serosal tears or perforations. If an appendix mass is diagnosed preoperatively, conservative management with combined antibiotics and interval appendectomy is recommended by many authors to avoid bowel injury complications [33]. Considering that more attention to the preoperative diagnosis of complicated appendicitis may have prevented resection of the ICV, a long history of abdominal pain, young age (under 5), and a palpable mass should raise the suspicion of an appendix mass. Ultrasound examination or examination-under-anaesthesia prior to surgery are effective methods of diagnosing an appendix mass. Conservative treatment has high efficacy, only 5-10 % of patients do not respond after 24-48 hrs on combined antibiotics and may require surgery. Considering this protocol and the recognition of the importance of the ICV may force surgeons to avoid the resection of the ICV in these cases.

The incidence of Crohn's disease is rising again worldwide (incidence of CD has doubled from 3.5 to 6 per 100,000 individuals per year from 1997 to 2006 [37]). Crohn's disease primarily affects the terminal ileum and ICV. Crohn's disease was expected to be prevalent among the diseases leading to loss of the ICV. However surgery is not the first line treatment of Crohn's disease especially nowadays since biological therapy became available. Complications unresponsive to medical therapy such as abscess, fistula, and intestinal

stricture may necessitate ICV resection. In these cases ICV reconstruction may be an option, especially if we consider that the relapse rate is higher if reflux control of ICV has been lost.

Colonic volvulus is a rare condition, but we identified nearly the same number of patients (5) as CD (7) patients who had lost the ICV. Neurodevelopmental delay and severe chronic constipation were found to be the most commonly associated diseases [28]. The presenting symptoms of large bowel volvulus occur quite frequently in children with neurodevelopmental delay and chronic constipation without volvulus and may respond to enema and laxatives. The rarity of the volvulus and the lack of adequate communication in a child with neurodevelopmental delay is the main reason why the diagnosis of volvulus may be delayed. Plain abdominal radiography may be helpful if it demonstrates extreme colonic dilatation and a relative absence of gas in the colon distal to the obstruction. The typical finding on contrast enema is a narrowed, twisted colon with a “bird’s beak” deformity (See Figure 8). The grossly dilated bowel segment with air-fluid level separated with septa has been considered as specific features of volvulus on CT scan. Contrast enema in severe chronic constipation is not only diagnostic, but therapeutic as well, because gastrografin is known to aid faecal dilution [55].

Early diagnosis of patients with PLBV makes conservative management, contrast enema detorsion, or early surgery possible preventing ICV loss. Otherwise reconstruction of ICV remains the option if compromised ICV needs to be removed.

It is surprising, but the lack of small bowel volvulus in our study suggests that volvulus due to malrotation rarely affects the ICV. According to the literature however, the ICV is lost in 11 % of small bowel volvulus [52].

Small bowel atresia does not necessarily lead to ICV loss, except in the rare case of ICV agenesis as mentioned in the introduction. However in an apple peel small bowel atresia the terminal ileum may not be viable and resection may be necessary.

Other causes like lymphoma, colonic angiodysplasia, meconium ileus, intestinal stricture, gastroschisis, and adhesive small bowel obstruction can be considered as sporadic cases leading to ICV loss.

6.2. The ileocaecal junction in healthy patients

We have found a significant difference ($p < 0.05$) between the groups including ileocaecal valve resection (Group 1 and Group 2) and the ileal resection control group (Group 3) regarding the complications. This result suggests that loss of the ileocaecal valve has significant (27%) long term risk to patients that are not suffering from Crohn's disease or Short Bowel Syndrome. It could be argued that these complications originate only from the loss of the ileocaecal valve after a right hemicolectomy. The resection always affects the terminal ileum to some extent. The last segment of the terminal ileum is known as the only site for bile salt reabsorption. On losing the terminal part of the ileum, the non reabsorbed bile salts that pass into the colon may induce diarrhoea due to their laxative effect [2]. It has been shown that approximately 20 cm of terminal ileum loss is still well tolerated [23]. This is in accordance with our observations in Group 3. Therefore we postulate that the complications caused by a right hemicolectomy, including removal of less than 10 cm of ileum in Group 1 and 2, is unlikely to be due to loss of the ileum.

During a right hemicolectomy, part of the ascending and transverse colon are resected. Loss of the colon reduces the reabsorption of water and electrolytes from the intraluminal

faeces, which may result in diarrhoea. We found no significant difference ($p = 0.947$) between Group 1 and 2 indicating that the extent of colonic loss, up to half of the colon, does not influence the rate of complications. Therefore it is unlikely the diarrhoea that occurs after a right hemicolectomy is attributable to colonic loss.

6.3. The ileocaecal junction in Short Bowel Syndrome

Bianchi (1999) suggested that the intact ICV is a good prognostic factor in SBS [9]. In the present series it appears that larger proportion of the patients have intact ICV in the survival group compared to the non-survival group (6/23 vs 2/13), however it did not reach statistical significance ($p = 0.38$). The relative small numbers in our series may distort result of statistical analysis. On the other hand it is easy to understand that other parameters like the absolute length of small bowel are stronger determining factors of survival. We showed that the survival group had a significantly longer segment of small bowel compared to the non-survival group: $66.0 \pm 32.5\text{cm}$ vs $42.5 \pm 19.4\text{cm}$. It is possible that conditions not affecting the ICV are resulting shorter bowel segment loss than more extensive diseases destroying the ICV. It is also known the quality of the remaining bowel really matters. The terminal ileum for example is the most valuable part of the small bowel because of the differences in absorption of vitamin B₁₂ and bile salts. Conditions affecting the ICV more likely affecting the terminal ileum than jejunum, but loss of a certain length of ileum with an intact ICV may cause less dramatic problems than loss of the same length of ileum alone. It is also possible that the terminal ileum associated with the intact ICV rather than the valve itself is responsible for the better survival [2, 8, 9]. If we were able to categorise patients in a group of SBS with

terminal ileum and no ICV and a group of SBS with no terminal ileum but an intact ICV we would be able to divide the importance of the ICV and the terminal ileum. Unfortunately the relative low incidence of the SBS makes this almost impossible. This however increase the value of our results gained in the previous research with healthy patients where we learned that the ICV itself is of significant importance. This however increase the value of our results gained in the previous research with healthy patients where we learned that the ICV itself is of significant importance.

The fact that in the survival group the mean length of small bowel with intact ICV was significantly shorter ($p=0.002$) than the mean length of small bowel without ICV clearly demonstrates that children survives with a significant shorter bowel if ICV is intact.

Our results suggest that the presence of an ICV-like structure (valve/sphincter) acting as an antegrade flow control between a short small bowel segment and the large bowel will delay transit, allows better absorption, reduce TPN dependency and possible improves survival. We believe that these findings justify attempts to reconstruct ICV in SBS compared to a simple end-to-end anastomosis

6.4. The ileocaecal junction in Crohn disease

However we found that very limited number of children underwent surgery due to Crohn's disease complications. We demonstrated that 50% of our patients with Crohn's disease undergoing a right hemicolectomy followed by a simple end to end anastomosis without reconstruction of the ICV developed recurrent Crohn's disease. This cannot be fully explained by the loss of the ICV. However Bakkevold 2009 showed that patients with

Crohn's disease who had construction of a nipple valve ileocolic anastomosis to mimic the ICV following resection, had a lower rate of recurrent Crohn's disease, 11% after 1 year, than previously published data 37% after 1 year [60]. 75 % of our patients have chronic diarrhoea after ICV resection, which may originate from the Crohn disease itself, but we learned that in otherwise healthy patients, loss of the ICV alone may result in chronic diarrhoea in about 27 %. Our data shows that to preserve or reconstruct the ICV in patients with Crohn's disease may be quite important.

6.5. Summary of the new results and conclusions

This thesis focuses on the clinical importance of the ileocaecal junction. Shows evidence and justifies attempts for its surgical reconstruction in Short Bowel Syndrome, Crohn's disease and in otherwise healthy children.

In the first section using clinical database analyses, the surgical conditions leading to loss of the original ileocaecal junction in children were established. The main cause leading to loss of the ileocaecal junction is age related: necrotising enterocolitis in the newborn period, intussusception in infancy, complicated appendicitis and inflammatory bowel disease and large bowel volvulus in adolescence. Accurate diagnosis of these conditions and the appreciation of the value of the ICV may prevent the need for resection of the valve.

In the second section the long term complications seen after the loss of the ileocaecal junction is analysed in otherwise healthy patients. Three groups of patients underwent limited hemicolectomy, hemicolectomy and resection of 10-25 cm ileum have been statistically compared. The results showed the loss of the original junction has significant long term morbidity. 27% of the patients developed long term diarrhoea and it comes only from the loss

of the ileocaecal valve. The loss of 10-25 cm terminal ileum and the loss of the ascending colon have no significant role in the postoperative complications.

In the third section the relation of the intact ICV and the survival in Short Bowel Syndrome has been analysed. Our results suggested that a significantly shorter (40.5 ± 7.74 cm vs. 74 ± 29.0 cm) small bowel length is required for survival if the ICV is intact. In the fourth section we looked at patients with Crohn's disease undergoing surgical intervention and ileocaecal resection. It was shown that a very high rate (75%) of chronic diarrhoea and disease recurrence (50%) occurred after loss of the ICV. However this is not attributable only to loss of the ICV. CD patients, especially, may benefit from preservation or reconstruction of the ICV.

Our results showed that ileocaecal valve reconstruction should be considered as part of Autologous Gastrointestinal Reconstructive Surgery in Short Bowel Syndrome. Patients with Crohn's disease and even otherwise healthy patients may benefit from ileocaecal reconstruction as well.

Keywords: ileocaecal valve, short bowel, autologue gastrointestinal reconstructive surgery

7. References

7.1 List of referenced literature

1. Addiss DG, Shaffer N, Fowler BS, Tauxe RV: The epidemiology of appendicitis and appendectomy in the United States. *Am J Epidemiol* 1990, 132:910-25.
2. Aldini R, Roda A, Festi D, Sama C, Mazzella G, Bazzoli F, Morselli AM, Roda E, Barbara L: Bile acid malabsorption and bile acid diarrhea in intestinal resection. *Dig Dis Sci.* 1982, 27:495-502.
3. Andersson RE, Petzold MG. Nonsurgical treatment of appendiceal abscess or phlegmon: a systematic review and meta-analysis. *Ann Surg* 2007;246:741-8.
4. Auvin S, Molinié F, Gower-Rousseau C, Brazier F, Merle V, Grandbastien B, Marti R, Lerebours E, Dupas JL, Colombel JF, Salomez JL, Cortot A, Turck D: Incidence, clinical presentation and location at diagnosis of pediatric inflammatory bowel disease: a prospective population-based study in northern France (1988-1999). *J Pediatr Gastroenterol Nutr.* 2005, 41:49-55.
5. Awapittaya B, Pattana-arun J, Tansatit T, Kanjanasilpa P, Sahakijrungruang C, Rojanasakul A: New concept of ileocecal junction: intussusception of the terminal ileum into the cecum. *World J Gastroenterol.* 2007, 13:2855-7.
6. Bakkevoold KE. Nipple valve anastomosis for preventing recurrence of Crohn disease in the neoterminal ileum after ileocolic resection: A prospective pilot study. *Scand J Gastroenterol.* 2000, 35:293-9.
7. Bakkevoold KE: Construction of an ileocolic neosphincter - Nipple valve anastomosis for prevention of postoperative recurrence of Crohn's disease in the neoterminal ileum after ileocecal or ileocolic resection. A long-term follow-up study. *J Crohns Colitis.* 2009, 3:183-8.
8. Bianchi A. From the cradle to enteral autonomy: the role of autologous gastrointestinal reconstruction: *Gastroenterology.* 2006, 130:S138-46.
9. Bianchi A: Experience with longitudinal intestinal lengthening and tailoring. *Eur J Pediatr Surg.* 1999, 9:256-9.
10. Bianchi A: Intestinal lengthening: a technique for increasing small intestinal length. *J Pediatr Surg* 1980, 15:145- 51.
11. Buettcher M, Baer G, Bonhoeffer J, Schaad UB, Heininger U: Three-year surveillance of intussusception in children in Switzerland. *Pediatrics.* 2007, 120:473-80.

12. Cacciari A, Mordenti M, Ceccarelli PL, Ruggeri G: Ileocaecal valve atresia: our surgical approach. *Eur J Pediatr Surg* 2004, 14: 435–9.
13. Chabert J, Pellissier S, Eribon O, Roche M : Reversed bowel segments for the treatment of short bowel syndrome: assessment of their minimal length in correlation with electromyographic pattern in the rat. *Neurogastroenterol Motil.* 2000, 12:53-63.
14. Cserni T, Takayasu H, Muzsnay Z, Varga G, Murphy F, Folaranmi SE, Rakoczy G. New idea of intestinal lengthening and tailoring: *Pediatr Surg Int.* 2011, 27:1009-13. Epub 2011 Apr 17.
15. Cserni T, Paran S, Kanyari Z, O'Donnell AM, Kutasy B, Nemeth N, Puri P: New insights into the neuromuscular anatomy of the ileocecal valve. *Anat Rec (Hoboken).* 2009, 292:254-61.
16. Cserni T, Magyar A, Németh T, Paran TS, Csízy I, Józsa T: Atresia of the ileocecal junction with agenesis of the ileocecal valve and vermiform appendix: report of a case. *Surg Today.* 2006, 36:1126-8.
17. Cserni T, Szekeres JP, Furka I, Németh N, Józsa T, Mikó I: Hydrostatic characteristics of the ileocolic valve and intussuscepted nipple valves: an animal model. *J Invest Surg.* 2005, 18:185-91.
18. Daneman A, Navarro O: Intussusception. Part 2: An update on the evolution of management. *Pediatr Radiol* 2004, 34:97.
19. Devesa JM, Botella-Carretero JI, López Hervás P, Rey A, Die J, Calero A: UltraShort Bowel Syndrome: surgical management and long-term results of an exceptional case. *J Pediatr Surg.* 2008, 43:E5-9. Review.
20. DiDio LJA. 1968. Jejunum and ileum. In: *The sphincters of the digestive system. Anatomical functional and surgical considerations.* Baltimore: William and Wilkins. p 52–196.
21. Dorney SF, Ament ME, Berquist WE, Vargas JH, Hassall E: Improved survival in very short small bowel of infancy with use of long-term parenteral nutrition. *J Pediatr.* 1985, 107:521-5.
22. Dott N.M: Anomalies of intestinal rotation: Their embryology and surgical aspects, with the report of five cases. *Br J Surg* 1923, 11:251-286.
23. Duro D, Jaksic T, Duggan C: Multiple micronutrient deficiencies in a child with Short Bowel Syndrome and normal somatic growth. *J Pediatr Gastroenterol Nutr.* 2008, 46:461-4.

24. Ein SH, Venugopal S, Mancer K: Ileocaecal atresia. *J Pediatr Surg* 1985, 20:525–8.
25. Ein SH, Shandling B: Is interval appendectomy necessary after rupture of an appendiceal mass? *J Pediatr Surg*. 1996, 31:849-50.
26. Fasoli L, Turi RA, Spitz L, Kiely EM, Drake D, Pierro A: Necrotizing enterocolitis: extent of disease and surgical treatment. *J Pediatr Surg*. 1999, 34:1096-9.
27. Filston HC, Kirks DR: Malrotation--the ubiquitous anomaly. *J Pediatr Surg* 1981, 16:614-20.
28. Folaranmi S, Cho A, Tareen F et al: Proximal large bowel volvulus in children: 6 new cases and a review of the literature. *J Pediatr Surg*. 2012 (In Press)
29. Folaranmi S, Rakoczy G, Bruce J, Humphrey G, Bowen J, Morabito A, Kapur P, Morecroft J, Craigie R, Cserni T: Ileocaecal valve: how important is it? *Pediatr Surg Int*. 2011, 27:613-5.
30. Ford E.G., Senac Jr. M.O., Srikanth M.S., et al: Malrotation of the intestine in children. *Ann Surg* 1992, 212:172-178.
31. Frazer T.E., Robbins R.F: On the factors concerned in causing rotation of the intestine in man. *J Anat Physiol* 1915, 50:74-110.
32. Geer DA, Arnaud G, Beitler A, et al: Colonic volvulus. The Army Medical Center experience 1983-1987. *Am Surg* 1991, 57:295-300.
33. Gillick J, Velayudham M, Puri P: Conservative management of appendix mass in children. *Br J Surg*. 2001, 88:1539-42.
34. Goh BK, Chui CH, Yap TL, Low Y, Lama TK, Alkouder G, Prasad S, Jacobsen AS. Is early laparoscopic appendectomy feasible in children with acute appendicitis presenting with an appendiceal mass? A prospective study. *J Pediatr Surg*. 2005 Jul;40(7):1134-7.
35. Goulet O, Ruemmele F, Lacaille F, Colomb V. Irreversible intestinal failure. *J Pediatr Gastroenterol Nutr*. 2004 Mar;38(3):250-69.
36. Grassi R, Pinto A, Valente T, Rossi G, Catalano O, Rotondo A, et al: Massive enterolithiasis associated with ileal dysgenesis. *Br J Radiol* 1997, 70:207–9.
37. Grieci T, Bütter A: The incidence of inflammatory bowel disease in the pediatric population of Southwestern Ontario. *J Pediatr Surg*. 2009, 44:977-80.

38. Grosfeld JL. Jejunioileal atresia and stenosis. In: O'Neill JA, Rowe MI, Grosfeld JL, Fonkalsrud EW, Coran AG, editors. *Pediatric surgery*. 5th ed. St. Louis: Mosby; 1998. p. 1145–58.
39. Grosfeld JL, Cheu H, Schlatter M, West KW, Rescorla FJ. Changing trends in necrotizing enterocolitis. Experience with 302 cases in two decades. *Ann Surg*. 1991 Sep;214(3):300-6; discussion 306-7.
40. Hall NJ, Jones CE, Eaton S, Stanton MP, Burge DM: Is interval appendectomy justified after successful nonoperative treatment of an appendix mass in children? A systematic review. *J Pediatr Surg*. 2011, 46:767-71.
41. Hutcher NE, Salzberg AM: Pre-ileal transposition of colon to prevent the development of the Short Bowel Syndrome in puppies with 90% small intestinal resection. *Surgery* 1971, 70:189-97.
42. Kim HB, Fauza D, Garza J, Oh JT, Nurko S, Jaksic T: Serial transverse enteroplasty (STEP): a novel bowel lengthening procedure. *J Pediatr Surg*. 2003, 38:425-9.
43. Kumar D, Phillips SF. 1987. The contribution of external ligamentous attachments to function of the ileocecal junction. *Dis Colon Rectum* 30:410–416.
44. Ladd W: Congenital obstruction of the duodenum in children. *N Engl J Med* 1932, 206:277-283.
45. Little, D. Malrotation. In *Ashcraft's Pediatric Surgery 5th Edition*; Holcomb, G, Murphy, P; Saunders: 2010, p420-422
46. Malbert CH: The ileocolonic sphincter. *Neurogastroenterol Motil*. 2005, 17 Suppl 1:41-9.
47. Mall F.P: Development of the human intestine and its position in the adult. *Johns Hopkins Hosp Bull* 1898, 9:197-208.
48. Meyer CL, Payne NR, Roback SA: Spontaneous, isolated intestinal perforations in neonates with birth weight less than 1,000 g not associated with necrotizing enterocolitis. *J Pediatr Surg*. 1991, 26:714-7.
49. Millar AJ, Rode H, Cywes S. Malrotation and volvulus in infancy and childhood. *Semin Pediatr Surg*. 2003, 12:229-36.
50. Moore, K, Persaud, T. In *The Developing Human, Clinically Oriented Embryology 6th Edition*; Moore, K, Persaud, T; Saunders: Philadelphia, 1998, p283

51. Myrvold H, Tindel MS, Isenberg HD, Stein TA, Scherer J, Wise L: The nipple valve as a sphincter substitute for the ileocecal valve: prevention of bacterial overgrowth in the small bowel. *Surgery*. 1984, 96:42-7.
52. Nasir AA, Abdur-Rahman LO, Adeniran JO: Outcomes of surgical treatment of malrotation in children. *Afr J Paediatr Surg*. 2011, 8:8-11.
53. Okada M, Yao T, Fuchigami T, Iida M, Date H: Anatomical involvement and clinical features in 91 Japanese patients with Crohn's disease. *J Clin Gastroenterol*. 1987, 9:165-71.
54. Olaison G, Smedh K, Sjö Dahl R. Natural course of Crohn's disease after ileocolic resection: endoscopically visualised ileal ulcers preceding symptoms. *Gut*. 1992, 33:331-5.
55. Patton D. Of gastrointestinal radiology, bread and butter; or, the flowering of barium sulfate. *Invest Radiol* 1994;29:472.
56. Petty JK, Ziegler MM: Operative strategies for necrotizing enterocolitis: The prevention and treatment of short-bowel syndrome. *Semin Pediatr Surg*. 2005 14:191-8.
57. Pierro, A, Ong, E. Malrotation. In *Pediatric Surgery*; Puri, P, Hollwarth, M; Springer: New York, 2006, p298-200.
58. Pokorny WJ, Garcia-Prats JA, Barry YN: Necrotizing enterocolitis: incidence, operative care, and outcome. *J Pediatr Surg*. 1986, 21:1149-54.
59. Ricotta J, Zuidema GD, Gadacz TR, Sadri D: Construction of an ileocecal valve and its role in massive resection of the small intestine. *Surg Gynecol Obstet*. 1981, 152:310-4.
60. Rutgeerts P, Geboes K, Vantrappen G, Beyls J, Kerremans R, Hiele M. Predictability of the postoperative course of Crohn's disease. *Gastroenterology*. 1990, 99:956-63.
61. Sawczenko A, Sandhu BK: Presenting features of inflammatory bowel disease in Great Britain and Ireland. *Arch Dis Child*. 2003, 88:995-1000.
62. Sawczenko A, Sandhu BK, Logan RF, Jenkins H, Taylor CJ, Mian S, Lynn R: Prospective survey of childhood inflammatory bowel disease in the British Isles. *Lancet*. 2001, 357:1093-4.
63. Shafik A, El-Sibai O, Shafik AA. Physiological assessment of the function of the ileocecal junction with evidence of ileocecal junction reflexes. *Med Sci Monit*. 2002 , 8:629-35.
64. Sah SP, Bhadani PP: *Enterobius vermicularis* causing symptoms of appendicitis in Nepal. *Trop Doct*. 2006, 36:160-2.

65. Takada K, Hamada Y, Sato M, Fujii Y, Teraguchi M, Kaneko K, Kamiyama Y: Cecal volvulus in children with mental disability. *Pediatr Surg Int.* 2007, 23:1011-4.
66. Touloukian RJ. Intestinal atresia and stenosis. In: Ashcraft KW, Holder TM, editors. *Pediatric surgery.* 2nd ed. Philadelphia: Saunders; 1993 p. 305–19.
67. Uauy RD, Fanaroff AA, Korones SB, Phillips EA, Phillips JB, Wright LL: Necrotizing enterocolitis in very low birth weight infants: biodemographic and clinical correlates. National Institute of Child Health and Human Development Neonatal Research Network. *Pediatr.* 1991, 119:630-8.
68. Vo NJ, O'Hara SM, AlonsoMH: Cecal volvulus: a rare cause of bowel obstruction in a pediatric patient diagnosed pre-operatively by conventional imaging studies. *Pediatr Radiol* 2005, 35:1128-31.
69. Zurita M, Raurich JM, Ramírez A, Gil J, Darder J. A new neovalve type in Short Bowel Syndrome surgery. *Rev Esp Enferm Dig.* 2004, 96:110-8.
70. Zurbuchen U, Kroesen AJ, Knebel P, Betzler MH, Becker H, Bruch HP, Senninger N, Post S, Buhr HJ, Ritz JP; German Advanced Surgical Treatment Study Group. Complications after end-to-end vs. side-to-side anastomosis in ileocecal Crohn's disease-early postoperative results from a randomized controlled multi-center trial (ISRCTN-45665492). *Langenbecks Arch Surg.* 2012.

7.2. The list of publications on which the thesis was based on



UNIVERSITY AND NATIONAL LIBRARY UNIVERSITY OF DEBRECEN
KENÉZY LIFE SCIENCES LIBRARY

Register Number: DEENKÉTK/26/2014.

Item Number:

Subject: Ph.D. List of Publications

Candidate: Semiu Eniola Folaranmi

Neptun ID: VYE2MS


Doctoral School: Doctoral School of Clinical Medicine

List of publications related to the dissertation

1. **Folaranmi, S.E.**, Cho, A., Tareen, F., Morabito, A., Rákóczy, G., Cserni, T.: Proximal large bowel volvulus in children: 6 new cases and 3 review of the literature.
J. Pediatr. Surg. 47 (8), 1572-1575, 2012.
DOI: <http://dx.doi.org/10.1016/j.jpedsurg.2011.10.064>
IF: 1.383
2. Cserni, T., Takayasu, H., Muzsnay, Z., Varga, G., Murphy, F., **Folaranmi, S.E.**, Rákóczy, G.: New idea of intestinal lengthening and tailoring.
Pediatr. Surg. Int. 27 (9), 1009-1013, 2011.
DOI: <http://dx.doi.org/10.1007/s00383-011-2900-x>
IF: 1.253
3. **Folaranmi, S.**, Rákóczy, G., Bruce, J., Humphrey, G., Bowen, J., Morabito, A., Kapur, P., Morecroft, J., Craigie, R., Cserni, T.: Ileocaecal valve: How important is it?
Pediatr. Surg. Int. 27 (6), 613-615, 2011.
DOI: <http://dx.doi.org/10.1007/s00383-010-2841-9>
IF: 1.253

List of other publications

4. Oragui, E., Eli, N., **Folaranmi, S.**, Soosainathan, S.: An Unusual Case of Fibular (Postaxial) Polydactyly: Extrametatarsal Head with Fused Duplication of the Proximal Phalanx.
The Journal of Foot and Ankle Surgery. 51 (4), 468-471, 2012.
DOI: <http://dx.doi.org/10.1053/j.jfas.2011.10.046>
IF: 0.86



5. **Folaranmi, S.E.**, Oragui, E., Craigie, R.J., Minford, J., Humphrey, G.: An unusual presentation of pheochromocytoma (Discussion and Diagnosis).
Acta Paediatr. 100 (11), 1510-1511, 2011.
DOI: <http://dx.doi.org/10.1111/j.1651-2227.2011.02402.x>
IF:2.073

6. **Folaranmi, S.E.**, Mehta, G., Datta, D., Holdstock, G.: Suspected intestinal tuberculosis might be Crohn's disease.
Case Report. Med. 2010, 4 p., 2010.
DOI: <http://dx.doi.org/10.1155/2010/695461>

7. **Folaranmi, S.E.**: General surgery.
In: Oxford specialist handbook of applied medicine and surgery in dentistry. auth. Athanasios Kalantzis, Crispin Scully, Oxford University Press, Oxford, 246-280, 2010.

8. Lyras, D.N., Kazakos, K., Verettas, D., Chronopoulos, E., **Folaranmi, S.**, Agrogiannis, G.: Effect of combined administration of transforming growth factor-b1 and insulin-like growth factor I on the mechanical properties of a patellar tendon defect model in rabbits.
Acta Orthop. Belg. 76 (3), 380-386, 2010.
IF:0.392

9. Zaidi, T., Sudall, C., Kauffmann, L., **Folaranmi, S.**, Khalil, B., Morabito, A.: Physical outcome and quality of life after total esophagogastric dissociation in children with severe neurodisability and gastroesophageal reflux, from the caregiver's perspective.
J. Pediatr. Surg. 45 (9), 1772-1776, 2010.
DOI: <http://dx.doi.org/10.1016/j.jpedsurg.2010.04.022>
IF:1.308

Total IF of journals (all publications): 8.522

Total IF of journals (publications related to the dissertation): 3.889

The Candidate's publication data submitted to the Publication Database of the University of Debrecen have been validated by Kenezly Life Sciences Library on the basis of Web of Science, Scopus and Journal Citation Report (Impact Factor) databases.

6 February, 2014



8. ACKNOWLEDGEMENT

I would like to take this opportunity to thank my supervisors Dr. Tamas Cserni, consultant paediatric surgeon at University Teaching Hospital of the Medical Health and Science Centre University of Debrecen, Nyíregyháza, Hungary and Dr. George Rakoczy consultant paediatric surgeon at, Royal Manchester Children's University Hospital, Manchester UK. They have played a significant role and have been very supportive in guiding me through the write up of this thesis. I owe them an enormous amount of gratitude. Also both Dr Cserni and Dr Rakoczy have been instrumental in developing my operative skills as a paediatric surgeon, and for that I would like to thank them.

I would like to thank Mr Adrian Bianchi and Mr Antonino Morabito, consultant paediatric surgeons, specialists and internationally renowned experts in Short Bowel Syndrome for allowing me to review the data of their patients and supporting me in writing this thesis.

Special thanks to the Clinical Audit department at Royal Manchester Children's University Hospital, for collecting and providing the case notes of the patients.

Most importantly, I would like to express my heartfelt gratitude to my beautiful wife, Rhyannon, for her support and patience in allowing me the time to complete this work. She is my best friend and soul mate, and has prayed for me throughout the write up of this thesis.