

# Microscopic colitis in older adults: impact, diagnosis, and management

Istvan Fedor<sup>1</sup> , Eva Zold<sup>2</sup>  and Zsolt Barta<sup>3</sup> *Ther Adv Chronic Dis*

2022, Vol. 13: 1–15

DOI: 10.1177/  
20406223221102821© The Author(s), 2022.  
Article reuse guidelines:  
sagepub.com/journals-  
permissions

**Abstract:** Microscopic colitis (comprising lymphocytic and collagenous colitis, albeit an incomplete variant is gaining recognition as well) is a chronic, immune-mediated inflammatory state of the lower gastrointestinal tract (colon). The diagnosis requires diagnostic colonoscopy with characteristic histopathological findings. They have a propensity to present in senior populations (above 60 years of age), particularly women – who are approximately 2.5–3 times more likely to develop microscopic colitis. Preexisting other immune-inflammatory diseases are also shown to predispose patients for the development of microscopic colitis. The classic presentation is profuse watery diarrhea, often during the night or early morning hours. Fecal incontinence and abdominal pain are frequent as well. Thus, the disease impacts patients' quality of life and well-being. The first described cases date back to the seventies and eighties of the twentieth century, thereby they can be considered fairly recently discovered disease states. Our understanding of the disease and its pathophysiology is still incomplete. Although there is a lack of unified recommendation for treatment, most clinicians prefer the use of budesonide, and most published guidelines regard this locally acting glucocorticoid as the therapy of choice. In our article, we aimed for a brief, noncomprehensive overview of the clinical significance, diagnosis, and management of microscopic colitis.

**Keywords:** autoimmune, diarrhea, gastrointestinal, microscopic colitis

Received: 15 December 2021; revised manuscript accepted: 28 April 2022.

## Introduction

Microscopic colitis (MC) is a chronic immune-inflammatory bowel disease, with a tendency to affect senior individuals (generally  $\geq 65$  years of age), especially women.<sup>1–3</sup> MC was first described in the 1970s (first, collagenous colitis in 1976,<sup>4</sup> whereas the term 'microscopic colitis' was first mentioned in 1980). MC comprises two subtypes (lymphocytic and collagenous colitis, LC and CC, respectively), and a third incomplete (MCi) variant was described as well. Table 1 provides an overview and comparison of histologic findings. MC can account for 20% of cases of chronic diarrhea in the elderly ( $\geq 65$  years of age).<sup>5</sup> Nonetheless, rarely it can be present in other age groups, young people, and even children.<sup>6–9</sup> It is suggested that the pathogenesis of MC is related to derailed immune responses to the gut microenvironment triggered by exogenous factors (pharmacologic and lifestyle) in the

genetically susceptible.<sup>3,10</sup> There are certain overlaps in genetic risk with other immune-mediated disorders.<sup>11–13</sup>

The classical presentation of the disease is watery, nonbloody diarrhea, often presenting during the night and early morning hours. Nonetheless, the absence of diarrhea cannot be used for ruling out the disease, as some patients might experience chronic constipation or alternating periods of constipation and diarrhea.<sup>14</sup> The main diagnostic challenge of the disease is that it requires histologic sampling from multiple sites (2–4 samples taken from both left and right colon, into separate containers) during colonoscopy, as overt mucosal inflammation is not always visible on endoscopy. Nevertheless, nonspecific macroscopic signs – such as mildly edematous, hyperemic bowel wall, and even 'cat-scratch appearance' on bowel mucosa – can also indicate underlying MC.<sup>6,15–18</sup>

Correspondence to:

**Istvan Fedor**  
Department of Public Health and Epidemiology, Faculty of Medicine, University of Debrecen, Kassai Street 26., Debrecen 4012, Hungary

Department of Clinical Immunology, Doctoral School of Clinical Immunology and Allergology, Institute of Internal Medicine, Faculty of Medicine, University of Debrecen, Moricz Zs. Street 22., Debrecen 4004, Hungary

**fedor.istvan@med.unideb.hu**

**Eva Zold**  
Department of Clinical Immunology, Doctoral School of Clinical Immunology and Allergology, Institute of Internal Medicine, Faculty of Medicine, University of Debrecen, Debrecen, Hungary

**Zsolt Barta**  
GI Unit, Department of Infectology, Doctoral School of Clinical Immunology and Allergology, Faculty of Medicine, University of Debrecen, Debrecen, Hungary

\*Eva Zold and Zsolt Barta contributed equally to the article.

**Table 1.** Histological features of microscopic colitis and incomplete microscopic colitis (MC, MCi).

	Subgroups	Mononuclear inflammation of LP	Subepithelial collagenous band	Intraepithelial lymphocytosis
Microscopic colitis (MC)	CC	Moderately increased – chronic inflammation	> 10 µm – distinct pattern of fibrosis	Normal or slightly increased
	LC	Moderately increased – chronic inflammation	Normal or slightly thickened	>20 IELs per 100 cells
Microscopic colitis incomplete (MCi)	CCi and LCi	Slightly increased	between 5 and 10 µm	10–20 IELs per 100 cells

CC, collagenous colitis; IELs, intraepithelial lymphocytes; LC, lymphocytic colitis; LP, lamina propria.

### Epidemiology, risk factors, and pathogenesis

Reports on incidence and prevalence were mostly conducted in higher-income countries (the Netherlands, USA, Sweden, UK, Iceland, Denmark, and Catalonia).<sup>19–25</sup> Nevertheless, there are studies on incidence data in lower-income countries.<sup>26–28</sup> Albeit some of these reports are published in other languages, the abstracts are available in English as well, and they are valuable in the assessment of true epidemiologic data. The disease seems to be more common in Northern Europe and North America; there is possibly an increased rate in northern latitudes, similar to other inflammatory bowel diseases.<sup>29,30</sup>

Initially, MC was thought to be a rare disease entity. Early estimates on incidence ranged from 1 to 5 per 100,000 person-years in Europe and North America. After the initial description of the disease, the newly diagnosed cases of MC increased, until stabilizing.<sup>3,31</sup> The incidence plateaued in this century.<sup>32–34</sup> Recent studies approximate the incidence rate to be 7–25 per 100,000 person-years for MC.<sup>3,31</sup> Currently, they are comparable in the number of new cases to classical inflammatory bowel diseases; in certain countries, it even exceeds them.<sup>34</sup>

The initial increase in incidence might have had multiple underlying causes. One is the increased awareness of MC and the more frequent histologic sampling of colonic tissues. We would also like to point out that using different staining methods – other than classic HE – can increase the diagnostic sensitivity (in particular, CD3 staining) as they allow the identification of more intraepithelial lymphocytes.<sup>35,36</sup> Furthermore, as

demographic trends in Western societies have shown an increase in the proportion of the elderly, this phenomenon might also contribute to the increased incidence of MC (as the disease typically affects people past the age of sixty).

The two subtypes show comparable incidence, though the literature is not consistent in this regard. Whereas most studies reported CC to be more common,<sup>33,37</sup> other authors (data from Olmsted County in Minnesota and Sweden)<sup>38,39</sup> found LC to be the more prevalent. According to a recent nationwide cohort study in Sweden, the estimated lifetime risk of developing MC is around one in 115 women and one in 286 men.<sup>6,39</sup> Thereby, females are approximately 2.5–3 times more likely to develop MC during their lives. Lymphocytic and collagenous colitis also differ in their age of onset according to previous reports. The former is usually diagnosed earlier in life.

The exact pathophysiology is not yet understood. The underlying cause of the condition is likely to be multifactorial.<sup>2</sup> Widely recognized are medications. There is convincing evidence on non-steroid anti-inflammatory drugs (NSAIDs) being a risk factor for MC. Furthermore, proton pump inhibitors (PPIs), HMG-CoA reductase inhibitors (statins), and selective serotonin reuptake inhibitors (SSRIs) were also proposed to contribute to disease risk.<sup>40–43</sup> Less commonly anti-hypertensive medications were described as a possible underlying risk factor. These agents include angiotensin-converting-enzyme inhibitors and β-blockers, but the evidence for this is less well established.<sup>44,45</sup> Moreover, both menopausal estrogen replacement therapy (ERT) and the use of oral contraceptive pills (OCPs) were described as predisposing medication in a study

**Table 2.** Drugs as risk factor for microscopic colitis (from Beaugerie and Pardi).<sup>40</sup>

High likelihood	Intermediate likelihood	Low likelihood to cause microscopic colitis
Acarbose	Carbamazepine	Cimetidine
Aspirin and NSAIDs	Celecoxib	Gold salts
Clozapine	Duloxetine	Piascledine
Entocapone	Fluvastatin	Pembrolizumab
Flavonoids	Flutamide	Topiramate
Lansoprazole, Omeprazole,	Oxetorone	ACE inhibitors
Esomeprazole	Madopar <sup>a</sup>	Bisphosphonates
Ranitidine	Paroxetine	ARBs
Sertraline	Simvastatin	β-blockers
Ticlodipine	Stalevo <sup>b</sup>	

ACE, angiotensin-converting enzyme; ARBs, angiotensin receptor blockers; NSAIDs, nonsteroid anti-inflammatory drugs.  
<sup>a</sup>Madopar is an antiparkinson medication with levodopa and benseracide.  
<sup>b</sup>Stalevo is an antiparkinson agents with carbidopa, levodopa, and entocapone.

published by Burke *et al.* Their investigation yielded that ERT enhanced risk more than OCPs, and they found no difference between disease subtypes (LC and CC). Thereby, clinicians should carefully weigh the possible risks and benefits of prescribing ERT for women past menopause.<sup>46</sup> As the aforementioned agents are frequently prescribed, particularly in the elderly, physicians should be aware of possible adverse outcomes of triggering or exacerbating MC.<sup>5,47</sup> Medications that were proposed to play a role in the increased risk for MC are listed in Table 2.

Existing autoimmune and rheumatic diseases in patients' history can raise the possibility of MC. Smoking is also regarded as a risk factor for MC.<sup>48–50</sup> Smoking enhances the risk of collagenous colitis more than that of lymphocytic colitis.<sup>48,51</sup> It is also recognized as a predisposing factor for earlier disease development (the mean age at disease onset was found to be 42 years by Vigen *et al.*)<sup>49</sup>

Several genetic factors were proposed as contributing to the disease risk.<sup>52,53</sup> There are shared human leukocyte antigen (HLA) alleles with certain autoimmune diseases.<sup>12,13,53</sup> One of the common autoimmune comorbidities in MC is celiac disease (CeD). The two conditions share some HLA-susceptibility alleles.<sup>54–56</sup> A

key inflammatory cytokine, interleukin-6 gene polymorphisms also seem to contribute to disease risk.<sup>56,57</sup> In addition, it seems the two subtypes of MC have distinct genetic susceptibility factors, thereby challenging the concept of the conditions being the same entity.<sup>11,58</sup> The inheritable nature of MC is indicated by the increased incidence in families.<sup>59–62</sup>

### Diagnosis

The hallmark symptom is in most cases profuse, nonbloody diarrhea, with a detrimental impact on the patient's subjective quality of life. Differential diagnosis should exclude other possible causes of diarrhea – (common causes are listed in Table 3). Note that most entities present usually earlier in life, whereas the diagnosis of MC is uncommon in young adults. In contrast, classic inflammatory bowel diseases are mostly present in the first three to four decades of life, with another incidence peak later in the seventh decade of life.<sup>63</sup> CeD was classically regarded as a disease in the pediatric population, though the incidence of cases in adults is on the rise. Irritable bowel syndrome (IBS) also shows a predilection for younger adults, rarely present in the senior population.

As the name implies, for establishing the diagnosis of MC, endoscopic imaging with histologic

**Table 3.** Differential diagnosis of microscopic colitis.

Differential diagnosis	Features
Infectious colitis	Watery diarrhea, detection of toxin by PCR or positive stool studies
Celiac disease	Steatorrhea, positive celiac disease serologic tests, duodenal biopsy confirming crypt hyperplasia and villous atrophy. Age of presentation: bimodal, first peak in childhood (8–12 months of age) and a second in the third decade of life. Average age of diagnosis is 8 years (ranging from 1 to 17) <sup>64</sup>
Inflammatory bowel disease – IBD – Crohn’s disease and ulcerative colitis	Bloody diarrhea, colonoscopy might demonstrate friability, erosions, edema, crypt abscesses (ulcerative colitis), skip lesions, and cobblestone mucosa with transmural inflammation and noncaseating granulomas (Crohn’s disease). Average age of disease onset: bimodally distributed, disease usually presents before 30 years of age, and there is a second peak later in life, especially in women. <sup>65</sup>
Irritable bowel syndrome – Diarrheal subtype (IBS-D)	Non-remarkable physical examination findings, normal laboratory studies and negative colonoscopy, biopsy. Average age of presentation: typically in the third to fourth decade of life, usually before 35 years of age. <sup>66</sup>

sampling is required. Colonoscopy is preferred over flexible sigmoidoscopy, as it allows a more comprehensive investigation. Full colonoscopy is also preferred to rule out colon cancer, a common malignancy in the elderly (in fact more frequent than MC). Nonetheless, flexible sigmoidoscopy can still diagnose the majority of MC cases.<sup>67,68</sup> Colonoscopy can be performed without complications most of the time; colonic perforation was reported in sporadic cases.<sup>69–71</sup> The risk of perforation is low and generally regarded as safe. A meta-analysis reviewing the endoscopic findings written by Marlicz *et al.* found a prevalence of 1.1%.<sup>18</sup> Thereby, cautious insufflation and careful technique are recommended in practice. The associated risk is not as great in flexible sigmoidoscopy.

The lymphocytic colitis subtype (LC) is characterized by  $\geq 20$  lymphocytes per 100 epithelial cells in the colonic epithelium, without thickened subepithelial collagen band. In collagenous colitis (CC), there is the presence of a thickened ( $>10\mu\text{m}$ ) subepithelial collagen band and mucosal inflammatory infiltrate (lymphocytosis, albeit not to the degree of that seen in lymphocytic colitis). Thus, an overlap in the histologic picture in lymphocytic and collagenous colitis exists.<sup>72</sup> On this basis, some even proposed the possibility that the two conditions might represent the same disease in different stages (reviewed by Rasmussen and Munck<sup>72</sup>). Remarkably, some investigations reported the age of diagnosis of lymphocytic colitis to be somewhat younger,

thereby raising the question of whether lymphocytosis is a forerunner to collagen band thickening.<sup>6,23,73</sup> On the contrary, other authors described the average age of diagnosis of collagenous colitis to be lower.<sup>21,24</sup> The seemingly controversial data challenge the concept of the two diseases being the same, and one must bear in mind that the two conditions have distinct genetic susceptibility features.<sup>58</sup> From the clinical point of view, this has no importance. Both diseases should be treated with the same pharmacotherapy.

Mild to moderate lymphocytosis ( $>5$  lymphocytes per 100 epithelial cells) and mildly thickened collagen band ( $>5\mu\text{m}$ ) not sufficing for MC criteria are categorized as incomplete variants (MCi). Another possible variant was described, mostly in pediatric cases, called ‘clear cell colitis’.<sup>74</sup> Whereas MC is not as common in young adults ( $<30$  years) and children, there are few reports on pediatric cases with MC.<sup>7,8,75</sup>

The classical picture of the disease is chronic, watery diarrhea. Nevertheless, some authors already described patients without diarrhea, even with constipation.<sup>14</sup> We should emphasize that gastrointestinal dysmotility was reported in other inflammatory states of the gastrointestinal tract; inflammation might hinder intestinal peristalsis.<sup>41,76–78</sup> As other conditions can be an underlying cause of chronic diarrhea, it is important to consider alternative diagnoses in patients. For a list of possible other causes, see Table 3. One of the frequent diseases posing a differential

**Table 4.** Differentiating irritable bowel syndrome from microscopic colitis with clinical history.<sup>4</sup>

Patient history data	Irritable bowel syndrome	Microscopic colitis
Age of onset	Usually before 50 years of age	Mostly after 50 years of age, in senior individuals
Stool consistency	Variable, alternating	Usually watery
Abdominal pain or discomfort	Obligatory	Variably present
Diarrhea during night	Very rare, not typical	Possible
A feeling of inadequate bowel cleansing	Commonly reported	No
Weight loss	Rarely	Common
Fecal incontinence	Rarely	Common
Bloating, fullness	Common	Rarely
Other immune-mediated disorders	Rarely present	Commonly encountered

diagnostic difficulty is IBS. A substantial proportion of patients are misdiagnosed with IBS, thereby missing an opportunity for proper pharmacologic management.<sup>5,27,31,79</sup> An overview of the differential aspects of IBS and MC is provided in Table 4. Most physicians still consider IBS as a diagnosis of exclusion.<sup>80–83</sup> This view is being challenged though, as a comprehensive gastrointestinal workup is both financially taxing and time-consuming. Thereby, A Ford and Black proposed that IBS can be diagnosed positively, without excluding every other possible cause first.<sup>84,85</sup> Moreover, multiple pharmacologic agents are known to cause diarrhea as an adverse effect.<sup>43</sup>

While their characteristic bowel wall inflammation is mostly apparent *via* histologic sampling, non-specific, subtle macroscopic signs can be present on the mucosa, visible on endoscopy or traditional imaging techniques.<sup>6</sup> These changes are edematous bowel wall and the presence of mucosal tears, the appearance of ‘cat scratch mucosa’.<sup>15–17,86</sup> No known specific laboratory markers have been discovered so far. Elevated erythrocyte sedimentation rate, mild anemia, and certain autoantibodies might be present. The most common autoantibodies are rheumatoid factor (RF), antinuclear and antimitochondrial antibodies, antineutrophilic cytoplasmic antibodies (ANCA), anti-*Saccharomyces cerevisiae* antibodies (ASCA), and antithyroid peroxidase (TPO) antibodies.<sup>87,88</sup> These findings are most likely to be related to comorbid immune conditions. Very rarely patients

may develop protein-losing enteropathy and consequent hypoalbuminemia.<sup>89–91</sup>

Because of the absence of validated laboratory biomarkers, the subjective impact on patients’ quality of life can be used as an approximate for disease activity. Patients with less than 3 daily stools and less than one liquid present little or no effect on their perceived well-being, for which reason this definition has been proposed as a criterion for clinical remission by Hjortswang *et al.*<sup>31,92</sup>

#### Impact on patients’ quality of life

Although not objectively measurable, the self-reported patient quality of life is usually impaired.<sup>93–95</sup> Disease anxiety is common in patients suffering from MC, especially in cases with fecal incontinence.<sup>93,94</sup> It can be a contributing factor for social isolation and has detrimental effects on free-time activities, limiting the possible options for elderly retired patients. For those still employed, the frequent rush to the bathroom can elicit feelings of embarrassment in front of coworkers. Fatigue, poor sense of smell and taste, loss of appetite are also common. These factors can contribute to the social isolation of affected patients.<sup>93</sup> Certain patients are also prone to have poorer self-esteem, regarding themselves as a burden for others. Consequently, adequate control of the disease can also contribute to the psychological well-being of the patients, enabling them to have a more fulfilling social life.

### Complications and comorbidities

Despite MC's negative impact on patients' well-being, the disease itself is usually benign, without grave clinical sequelae. There is no known associated risk for malignancy of the colon (distinguishing feature from ulcerative colitis).<sup>96–98</sup> There is a slightly increased risk for lung cancer, but these findings should also consider smoking as a confounding factor: As smoking predisposes patients to both MC and lung cancer, possibly both conditions originate from this risk factor.<sup>96</sup>

Although the absorption of macronutrients generally remains intact, patients have an increased tendency for developing reduced bone mass and mineral content.<sup>99,100</sup> The exact underlying process behind this is not yet fully understood, possibly a combination of chronic glucocorticoid treatment with an inflammatory state. Thus, patients are recommended to pay attention to their mineral – calcium – intake as well as adequate vitamin-D status.<sup>5</sup>

As indicated, patients with preexisting immune-mediated inflammatory diseases have a greater risk for the development of MC.<sup>101,102</sup> The most frequently reported associated condition is CeD.<sup>102–104</sup> Patients with CeD, with adequate gluten-free diet adherence, might still have gastrointestinal complaints if they develop MC. MC and CeD share susceptibility genetic factors, partially explaining their frequent association.<sup>54,55</sup> Furthermore, the differential diagnosis of MC should also exclude CeD (see Table 3).

Whereas progressive systemic sclerosis or CREST syndrome (calcinosis, Raynaud's phenomenon, esophageal dysmotility, sclerodactyly, teleangiectasia) has certain overlapping features with collagenous colitis, their association is rare, and not frequently encountered.<sup>76,105,106</sup> Diseases affecting the thyroid are also possibly encountered. Not only do patients with MC seem to have a higher risk for developing autoimmune conditions of the thyroid gland, but patients with Hashimoto thyroiditis might display increased epithelial lymphocytosis in their intestinal lining.<sup>107,108</sup>

The current view is that the development of MC is generally not a forerunner to classical inflammatory bowel diseases (Crohn's and ulcerative colitis). The latter two diseases are generally present at a younger age (often in childhood).<sup>109–111</sup> Both Crohn's disease and ulcerative colitis are known

to have a more thoroughly explored pathogenesis, and they also feature manifestations outside the gastrointestinal tract. Nevertheless, given the shared genetic susceptibility factors and the possible connection between the disease states, it is hardly surprising that association with classic IBD in patients is possible. Cases with comorbid IBD were recently described by Khalili *et al.*<sup>112</sup>

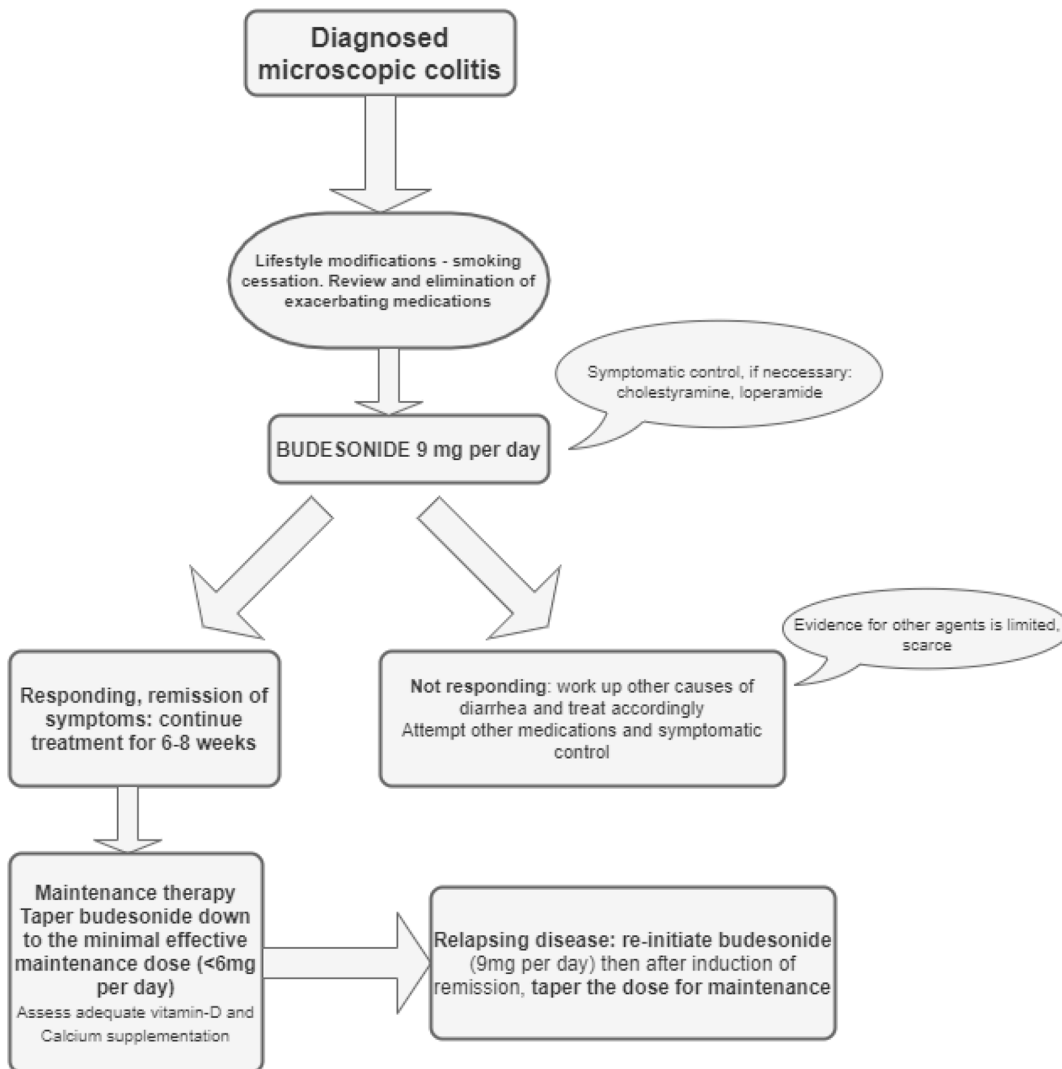
### Management

The therapeutic intervention aims the symptomatic control of the disease. This can significantly improve patients' reported quality of life. Hjortswang *et al.*<sup>92</sup> proposed remission criteria according to their research with health-related quality of life questionnaires. They suggested clinicians should preferentially aim for appropriate disease control with less than 3 stools per day, with no watery diarrhea.<sup>31,92</sup> Histologic remission is also warranted with adequate therapies.<sup>113</sup>

Whenever possible, causative and aggravating medications<sup>40,42,43,45,114,115</sup> NSAIDs, PPIs, SSRIs, cigarette smoking,<sup>49,50</sup> and alcohol should be eliminated. Clinicians are thereby advised to review the medications of patients and assess other risk factors. A treatment approach flow-chart is depicted in Figure 1. Were these measures insufficient to achieve proper disease control, pharmacologic therapy is indicated.

The cornerstone of treatment is budesonide, a glucocorticoid with predominantly local-topical effects, confined to the intestines and hepatic tissues.<sup>116,117</sup> Generally, after the induction of remission (9 mg budesonide per day for 6–8 weeks), a low-dose maintenance therapy is indicated. Reports and recommendations suggest that tapering down to the minimal effective dose is required to avoid relapses of the disease. This dosage can be as low as 3 mg every other day. Patients who do not receive adequate maintenance therapy often relapse with their symptoms.<sup>118</sup>

The relapse rate after withdrawal of budesonide can be as high as 80% and can occur as soon as 2 weeks.<sup>119</sup> Factors contributing to enhanced relapse rate are a longer duration of symptoms before treatment (more than 12 months), advanced age (above sixty years), and more severe baseline disease activity (frequency of daily diarrheas exceeding 5).



**Figure 1.** A proposed treatment algorithm for microscopic colitis (regardless of whether collagenous or lymphocytic colitis or incomplete variant). Note that the backbone of therapy is adequate risk factor assessment and elimination along with properly administered budesonide. Nonetheless, about 10–20% of patients are refractory for budesonide treatment; in those cases, other drugs might prove effective.

Patients with persisting symptoms can be treated with the bile-acid binding agent cholestyramine (4 g, taken multiple times per day) in combination with loperamide. If symptoms are adequately improving, the administration of cholestyramine should last until the resolution of diarrhea. Cholestyramine can be particularly effective in cases with bile-acid malabsorption.<sup>120,121</sup>

For symptomatic control of the disease, another therapeutic option is bismuth-subsalicylate for relapsing patients. It has been found to alleviate disease activity and is generally safe for short-term use. Apart from reducing the episodes of

diarrhea, it can also contribute to histologic remission of the disease. Thus far, no larger sample group randomized control trials have been conducted with bismuth subsalicylate. Therefore, information about efficacy is derived from a small open-label trial (low-quality evidence).<sup>122</sup> A dose of  $3 \times 262$  mg three times per day (9 tablets) was found to improve symptom control.<sup>123</sup> Prolonged administration is not recommended due to possible toxicity.<sup>31</sup>

Treatments with other agents, such as systemic glucocorticoids, aminosalicylates, and immunosuppressant agents (like methotrexate or azathioprine),

display less favorable outcomes.<sup>124–126</sup> The remission rate with budesonide is approximately 80%, whereas other therapeutic interventions are generally not as effective. Particularly the systemic administration of prednisone yielded a remission rate not better than placebo in a small randomized clinical trial.<sup>125</sup> Thereby, the response rate of prednisone is inferior to budesonide, and the latter is also found to be better in maintaining remission. The side effect profile of prednisone is also unfavorable.<sup>126,127</sup>

As aminosalicylates are frequently used in the management of other inflammatory bowel diseases, they were studied in comparison with budesonide. However, in MC, the efficacy of aminosalicylates was nonsuperior to placebo.<sup>128</sup> Before the advent of local budesonide therapy, aminosalicylates were compared with systemic glucocorticoids and reported to be inferior.<sup>88</sup>

Tumor necrosis factor (TNF)- $\alpha$  inhibitors show excellent efficacy in cases of other inflammatory bowel diseases, thereby there were investigations and case reports with these agents (infliximab, adalimumab) in MC as well.<sup>129–131</sup> Although in certain cases TNF- $\alpha$  blocking biologic therapy can be effective in induction of remission, they are generally not indicated. They might offer a solution for patients who are refractory to budesonide treatment.

Furthermore, TNF blockers might even worsen the symptoms of MC. Previous reports are available on cases, where the administration of TNF- $\alpha$  inhibitors caused patients to develop the histologic picture of collagenous colitis. The exact pathophysiology underlying this phenomenon is not yet elucidated. Possibly there is a transforming growth factor- $\beta$  (TGF- $\beta$ ) overactivity, as a consequence of TNF- $\alpha$  inhibition. Excess collagen synthesis and fibrous tissue remodeling thus can be an adverse effect of TNF- $\alpha$  blocking biologics.<sup>132</sup> The role of different inflammatory cytokines in regulating extracellular matrix (ECM) structural homeostasis was described previously.<sup>133–135</sup>

The role of TGF- $\beta$  was described in other conditions with excessive fibrous thickening.<sup>136–139</sup> In pulmonary fibrosis and systemic sclerosis, there is evidence for excessive TGF- $\beta$  activity. Currently, there are no recommendations for administering antifibrotic agents in collagenous colitis, though

they might be beneficial and delay the progression of collagen band thickening.

Another novel therapeutic option is vedolizumab, targeting  $\alpha_4\beta_7$  integrin. This monoclonal antibody is already approved for the treatment of Crohn's disease and ulcerative colitis, and there are indeed promising results in refractory cases of MC as well.<sup>140–142</sup> Remarkably, it seems to be effective in patients who are otherwise refractory to traditional therapy with budesonide and other immunomodulant agents.<sup>142</sup> More investigations are required to judge its true efficacy, as in another case series, vedolizumab only induced and maintained remission in less than half of the patients.<sup>140</sup>

Surgical management of MC is regarded as a last resort, reserved for patients who are refractory to medical therapy. There are no larger reports available; most publications thus far are case series or individual case reports.<sup>64,65,143–145</sup> Ileostomy (fecal stream diversion) can be effective in elderly patients. In addition to the resolution of diarrhea, there were also observable improvements in collagen band thickening in patients with collagenous colitis. After the restoration of intestinal continuity, half of the patients relapsed both clinically and histologically. This highlights the possible role of luminal microbial factors in the pathogenesis of the disease.<sup>66</sup> Other surgical options include sigmoidostomy and colectomy. Nonetheless, surgical management is falling out of favor, as available medical therapies are effective in the vast majority of cases, without the risks associated with surgical procedures.

### Closing remarks and conclusion

Our article has its limitations as not being a comprehensive review, solely focusing on clinical aspects of the disease. Thereby, we did not aim to recapitulate current concepts about the genetic background of the disease. Moreover, we did not include a more in-depth description of therapies, other than budesonide, due to lack of sufficient evidence. Currently, other agents have no solid basis for recommendations, and the evidence of their efficacy is mostly empirical. We sought only to briefly provide an overview for clinicians in the recognition and management of this disease entity, mostly emphasizing practical points.

MC is not uncommon in senior populations; its incidence is comparable to that of other

inflammatory bowel diseases. Women are more likely to suffer from this disease, especially those with preexisting immune-inflammatory conditions. Typically MC manifests with chronic non-bloody diarrhea, though a smaller proportion of patients might even experience periods of constipation or only abdominal pain. Recommended treatment is the local glucocorticoid preparation budesonide. After induction of remission (typically 9 mg budesonide per day for 6–8 weeks), treatment should be titrated down to a minimal effective dose as maintenance therapy. Without adequate maintenance, the relapse rate can be as high as 80%. In case of persisting diarrhea, symptomatic control of the disease can be achieved with cholestyramine or bismuth-subsalicylate. Surgical approaches should be regarded as a last resort in medication refractory cases. Patients should have their bone mineral density checked regularly, and clinicians are advised to prescribe vitamin D and adequate calcium supplementation.

## Declarations

### Ethics approval and consent to participate

Not applicable.

### Consent for publication

Not applicable.

### Author contributions


**Istvan Fedor:** Conceptualization; Writing – original draft.


**Eva Zold:** Conceptualization; Supervision; Writing – review & editing.

**Zsolt Barta:** Conceptualization; Supervision; Writing – review & editing.

### ORCID iDs

Istvan Fedor  <https://orcid.org/0000-0002-4368-7709>

Eva Zold  <https://orcid.org/0000-0002-3212-6877>

Zsolt Barta  <https://orcid.org/0000-0002-8200-6937>

### Acknowledgements

I would like to express gratitude to Dora Bencze, who read and provided valuable comments on the initial version of the manuscript. I am also grateful for my supervisors (Eva Zold and Zsolt Barta) for helping in the finalization of the paper and the acquisition of publication charges.

## Funding

The authors received no financial support for the research, authorship, and/or publication of this article.

## Conflict of interest statement

The authors declared no potential conflicts of interest with respect to the research, authorship, and/or publication of this article.

## Availability of data and materials

Data used in this paper is available on public domains, with DOI.

## References

1. Ohlsson B. New insights and challenges in microscopic colitis. *Therap Adv Gastroenterol* 2015; 8: 37–47.
2. Shor J, Churrango G, Hosseini N, *et al.* Management of microscopic colitis: challenges and solutions. *Clin Exp Gastroenterol* 2019; 12: 111–120.
3. Burke KE, D’Amato M, Ng SC, *et al.* Microscopic colitis. *Nat Rev Dis Prim* 2021; 7: 39.
4. Lindström CG. ‘Collagenous colitis’ with watery diarrhoea – a new entity? *Pathol Eur* 1976; 11: 87–89.
5. Münch A, Sanders DS, Molloy-Bland M, *et al.* Undiagnosed microscopic colitis: a hidden cause of chronic diarrhoea and a frequently missed treatment opportunity. *Frontline Gastroenterol* 2020; 11: 228–234.
6. Mellander MR, Ekbohm A, Hultcrantz R, *et al.* Microscopic colitis: a descriptive clinical cohort study of 795 patients with collagenous and lymphocytic colitis. *Scand J Gastroenterol* 2016; 51: 556–562.
7. El-Matary W, Girgis S, Huynh H, *et al.* Microscopic colitis in children. *Dig Dis Sci* 2010; 55: 1996–2001.
8. Singh P, Das P, Jain AK, *et al.* Microscopic colitis in children with chronic diarrhea. *J Pediatr Gastroenterol Nutr* 2013; 57: 240–244.
9. Windon AL, Almazan E, Oliva-Hemker M, *et al.* Lymphocytic and collagenous colitis in children and adolescents: comprehensive clinicopathologic analysis with long-term follow-up. *Hum Pathol* 2020; 106: 13–22.
10. Pardi DS. Diagnosis and management of microscopic colitis. *Am J Gastroenterol* 2017; 112: 78–85.

11. Westerlind H, Mellander MR, Bresso F, *et al.* Dense genotyping of immune-related loci identifies HLA variants associated with increased risk of collagenous colitis. *Gut* 2017; 66: 421–428.
12. Green HD, Beaumont RN, Thomas A, *et al.* Genome-wide association study of microscopic colitis in the UK Biobank confirms immune-related pathogenesis. *J Crohn's Colitis* 2019; 13: 1578–1582.
13. Bonfiglio F, Raj T, Torres J, *et al.* Collagenous colitis is associated with HLA immune-mediated diseases 2021; 159: 549–561.
14. Thörn M, Sjöberg D, Holmström T, *et al.* Collagenous colitis without diarrhoea at diagnosis – a follow up study. *Scand J Gastroenterol* 2019; 54: 194–197.
15. Kane JS, Rotimi O and Ford AC. Macroscopic findings, incidence and characteristics of microscopic colitis in a large cohort of patients from the United Kingdom. *Scand J Gastroenterol* 2017; 52: 988–994.
16. Baudet JS and Aguirre-Jaime A. Factors related to the development of cat scratch colon during colonoscopy. *Endoscopy* 2013; 45: 582–584.
17. Shiratori Y and Fukuda K. Collagenous colitis diagnosed by endoscopically induced mucosal tears. *BMJ Case Rep* 2019; 12: e230570.
18. Marlicz W, Skonieczna-Żydecka K, Yung DE, *et al.* Endoscopic findings and colonic perforation in microscopic colitis: a systematic review. *Dig Liver Dis* 2017; 49: 1073–1085.
19. Verhaegh BP, Jonkers DM, Driessen A, *et al.* Incidence of microscopic colitis in the Netherlands. A nationwide population-based study from 2000 to 2012. *Dig Liver Dis* 2015; 47: 30–36.
20. Pardi DS, Loftus EVJ, Smyrk TC, *et al.* The epidemiology of microscopic colitis: a population based study in Olmsted County, Minnesota. *Gut* 2007; 56: 504–508.
21. Fernández-Bañares F, Salas A, Forné M, *et al.* Incidence of collagenous and lymphocytic colitis: a 5-year population-based study. *Am J Gastroenterol* 1999; 94: 418–423.
22. Fernández-Bañares F, Salas A, Esteve M, *et al.* Evolution of the incidence of collagenous colitis and lymphocytic colitis in Terrassa, Spain: a population-based study. *Inflamm Bowel Dis* 2011; 17: 1015–1020.
23. Fumery M, Kohut M, Gower-Rousseau C, *et al.* Incidence, clinical presentation, and associated factors of microscopic colitis in northern France: a population-based study. *Dig Dis Sci* 2017; 62: 1571–1579.
24. Agnarsdottir M, Gunnlaugsson O, Orvar KB, *et al.* Collagenous and lymphocytic colitis in Iceland. *Dig Dis Sci* 2002; 47: 1122–1128.
25. Vigren L, Olesen M, Benoni C, *et al.* An epidemiological study of collagenous colitis in southern Sweden from 2001–2010. *World J Gastroenterol* 2012; 18: 2821–2826.
26. Essid M, Kallel S, Ben Brahim E, *et al.* [Prevalence of the microscopic colitis to the course of the chronic diarrhea: about 150 cases]. *Tunis Med* 2005; 83: 284–287.
27. Valle Mansilla JL, León Barúa R, Recavarren Arce S, *et al.* [Microscopic colitis in patients with chronic diarrhea]. *Rev Gastroenterol Del Peru Organo of La Soc Gastroenterol Del Peru* 2002; 22: 275–278.
28. Gado AS, Ebeid BA, El Hindawi AA, *et al.* Prevalence of microscopic colitis in patients with chronic diarrhea in Egypt: a single-center study. *Saudi J Gastroenterol* 2011; 17: 383–386.
29. Holmes EA, Rodney Harris RM and Lucas RM. Low sun exposure and vitamin D deficiency as risk factors for inflammatory bowel disease, with a focus on childhood onset. *Photochem Photobiol* 2019; 95: 105–118.
30. Stein AC, Gaetano JN, Jacobs J, *et al.* Northern latitude but not season is associated with increased rates of hospitalizations related to inflammatory bowel disease: results of a multi-year analysis of a national cohort. *PLoS ONE* 2016; 11: e0161523.
31. Miehle S, Guagnozzi D, Zabana Y, *et al.* European guidelines on microscopic colitis: United European Gastroenterology and European Microscopic Colitis Group statements and recommendations. *United Eur Gastroenterol J* 2021; 9: 13–37.
32. Wickbom A, Bohr J, Eriksson S, *et al.* Stable incidence of collagenous colitis and lymphocytic colitis in Örebro, Sweden, 1999–2008: a continuous epidemiologic study. *Inflamm Bowel Dis* 2013; 19: 23872387–23872393.
33. Tong J, Zheng Q, Zhang C, *et al.* Incidence, prevalence, and temporal trends of microscopic colitis: a systematic review and meta-analysis. *Off J Am Coll Gastroenterol | ACG* 2015; 110. [https://journals.lww.com/ajg/Fulltext/2015/02000/Incidence,\\_Prevalence,\\_and\\_Temporal\\_Trends\\_of.11.aspx](https://journals.lww.com/ajg/Fulltext/2015/02000/Incidence,_Prevalence,_and_Temporal_Trends_of.11.aspx)

34. Weimers P, Ankersen DV, Lophaven S, *et al.* Incidence and prevalence of microscopic colitis between 2001 and 2016: a Danish nationwide cohort study. *J Crohn's Colitis* 2020; 14: 1717–1723.
35. Cooper R, Papworth NJ, Harris C, *et al.* Counting intraepithelial lymphocytes: a comparison between routine staining and CD3 immunohistochemistry. *Int J Surg Pathol* 2020; 28: 367–370.
36. Engel PJH, Fiehn AK, Munck LK, *et al.* The subtypes of microscopic colitis from a pathologist's perspective: past, present and future. *Ann Transl Med* 2018; 6: 69.
37. Sonnenberg A and Genta RM. Lymphocytic and collagenous colitis: epidemiologic differences and similarities. *Dig Dis Sci* 2013; 58: 2970–2975.
38. Gentile NM, Khanna S, Loftus EV Jr, *et al.* The epidemiology of microscopic colitis in Olmsted County from 2002 to 2010: a population-based study. *Clin Gastroenterol Hepatol* 2014; 12: 838838–838842.
39. Bergman D, Clements MS, Khalili H, *et al.* A nationwide cohort study of the incidence of microscopic colitis in Sweden. *Aliment Pharmacol Ther* 2019; 49: 1395–1400.
40. Beaugerie L and Pardi DS. Review article: drug-induced microscopic colitis – proposal for a scoring system and review of the literature. *Aliment Pharmacol Ther* 2005; 22: 277–284.
41. Miehke S, Verhaegh B, Tontini GE, *et al.* Microscopic colitis: pathophysiology and clinical management. *Lancet Gastroenterol Hepatol* 2019; 4: 305–314.
42. Verhaegh BP, de Vries F, Masclee AA, *et al.* High risk of drug-induced microscopic colitis with concomitant use of NSAIDs and proton pump inhibitors. *Aliment Pharmacol Ther* 2016; 43: 1004–1013.
43. Lucendo AJ. Drug exposure and the risk of microscopic colitis: a critical update. *Drugs R D* 2017; 17: 79–89.
44. Fernández-Bañares F, de Sousa MR, Salas A, *et al.* Epidemiological risk factors in microscopic colitis: a prospective case-control study. *Inflamm Bowel Dis* 2013; 19: 411–417.
45. Masclee GM, Coloma PM, Kuipers EJ, *et al.* Increased risk of microscopic colitis with use of proton pump inhibitors and non-steroidal anti-inflammatory drugs. *Am J Gastroenterol* 2015; 110: 749–759.
46. Burke KE, Ananthakrishnan AN, Lochhead P, *et al.* Identification of menopausal and reproductive risk factors for microscopic colitis—results from the nurses' health study. *Gastroenterology* 2018; 155: 1764–1775.
47. O'Toole A. Optimal management of collagenous colitis: a review. *Clin Exp Gastroenterol* 2016; 9: 31–39.
48. Yen EF, Pokhrel B, Du H, *et al.* Current and past cigarette smoking significantly increase risk for microscopic colitis. *Inflamm Bowel Dis* 2012; 18: 1835–1841.
49. Vigren L, Sjöberg K, Benoni C, *et al.* Is smoking a risk factor for collagenous colitis? *Scand J Gastroenterol* 2011; 46: 1334–1339.
50. Burke KE, Ananthakrishnan AN, Lochhead P, *et al.* Smoking is associated with an increased risk of microscopic colitis: results from two large prospective cohort studies of US women. *J Crohn's Colitis* 2018; 12: 559–567.
51. Jaruvongvanich V, Poonsombudlert K and Ungprasert P. Smoking and risk of microscopic colitis: a systematic review and meta-analysis. *Inflamm Bowel Dis* 2019; 25: 672–678.
52. Norén E, Mellander MR, Almer S, *et al.* Genetic variation and gene expression levels of tight junction genes indicates relationships between PTEN as well as MAGI1 and microscopic colitis. *Dig Dis Sci* 2018; 63: 105–112.
53. Stahl E, Roda G, Dobbyn A, *et al.* Collagenous colitis is associated with HLA signature and shares genetic risks with other immune-mediated diseases. *Gastroenterology* 2020; 159: 549–561.
54. Fine KD, Do K, Schulte K, *et al.* High prevalence of celiac sprue-like HLA-DQ genes and enteropathy in patients with the microscopic colitis syndrome. *Am J Gastroenterol* 2000; 95: 1974–1982.
55. Fernández-Bañares F, Esteve M, Farré C, *et al.* Predisposing HLA-DQ2 and HLA-DQ8 haplotypes of coeliac disease and associated enteropathy in microscopic colitis. *Eur J Gastroenterol Hepatol* 2005; 17: 1333–1338.
56. Pisani LF, Tontini GE, Vecchi M, *et al.* Microscopic colitis: what do we know about pathogenesis? *Inflamm Bowel Dis* 2016; 22: 450–458.
57. Koskela RM, Karttunen TJ, Niemelä SE, *et al.* Cytokine gene polymorphism in microscopic colitis association with the IL-6-174 GG genotype. *Eur J Gastroenterol Hepatol* 2011; 23: 607–613.

58. Westerlind H, Bonfiglio F, Mellander MR, *et al.* HLA associations distinguish collagenous from lymphocytic colitis. *Am J Gastroenterol* 2016; 111: 1211–1213.
59. Abdo AA, Zetler PJ and Halparin LS. Familial microscopic colitis. *Can J Gastroenterol* 2001; 15: 341–343.
60. Järnerot G, Hertervig E, Grännö C, *et al.* Familial occurrence of microscopic colitis: a report on five families. *Scand J Gastroenterol* 2001; 36: 959–962.
61. Phull PS, Vijayan B, Bisset WM, *et al.* Familial collagenous colitis involving a 6-year old child. *J Crohns Colitis* 2012; 6: 606–609.
62. Wickbom A, Nyhlin N, Montgomery SM, *et al.* Family history, comorbidity, smoking and other risk factors in microscopic colitis: a case-control study. *Eur J Gastroenterol Hepatol* 2017; 29: 587–594.
63. Hou JK, Kramer JR, Richardson P, *et al.* The incidence and prevalence of inflammatory bowel disease among U.S. veterans: a national cohort study. *Inflamm Bowel Dis* 2013; 19: 1059–1064.
64. Münch A, Söderholm JD, Wallon C, *et al.* Dynamics of mucosal permeability and inflammation in collagenous colitis before, during, and after loop ileostomy. *Gut* 2005; 54: 1126–1128.
65. Williams RA and Gelfand DV. Total proctocolectomy and ileal pouch anal anastomosis to successfully treat a patient with collagenous colitis. *Am J Gastroenterol* 2000; 95: 2147.
66. Järnerot G, Tysk C, Bohr J, *et al.* Collagenous colitis and fecal stream diversion. *Gastroenterology* 1995; 109: 449–455.
67. Davidson S, Sjöberg K, Engel PJH, *et al.* Microscopic colitis in Denmark and Sweden: incidence, putative risk factors, histological assessment and endoscopic activity. *Scand J Gastroenterol* 2018; 53: 818–824.
68. Macaigne G, Lahmek P, Locher C, *et al.* Over 90% of cases of Microscopic Colitis can be diagnosed by performing a short colonoscopy. *Clin Res Hepatol Gastroenterol* 2017; 41: 333–340.
69. Sherman A, Ackert JJ, Rajapaksa R, *et al.* Fractured colon: an endoscopically distinctive lesion associated with colonic perforation following colonoscopy in patients with collagenous colitis. *J Clin Gastroenterol* 2004; 38: 341–345.
70. Allende DS, Taylor SL and Bronner MP. Colonic perforation as a complication of collagenous colitis in a series of 12 patients. *Am J Gastroenterol* 2008; 103: 2598–2604.
71. Hussain Z, Kelly S, Clarke A, *et al.* Colonic perforation in collagenous colitis: a systematic review of a rare complication and guidance on management. *Surg Endosc* 2010; 24: 2930–2934.
72. Rasmussen MA and Munck LK. Systematic review: are lymphocytic colitis and collagenous colitis two subtypes of the same disease – microscopic colitis. *Aliment Pharmacol Ther* 2012; 36: 79–90.
73. Erdem L, Yildirim S, Akbayir N, *et al.* Prevalence of microscopic colitis in patients with diarrhea of unknown etiology in Turkey. *World J Gastroenterol* 2008; 14: 4319–4323.
74. Jozefczuk J and Wozniewicz BM. Clear cell colitis: a form of microscopic colitis in children. *World J Gastroenterol* 2008; 14: 231–235.
75. Benchimol EI, Kirsch R, Viero S, *et al.* Collagenous colitis and eosinophilic gastritis in a 4-year old girl: a case report and review of the literature. *Acta Paediatr* 2007; 96: 1365–1367.
76. Ozaki H, Hori M, Kinoshita K, *et al.* Intestinal dysmotility in inflammatory bowel disease: mechanisms of the reduced activity of smooth muscle contraction. *Inflammopharmacology* 2005; 13: 103–111.
77. Bassotti G, Antonelli E, Villanacci V, *et al.* Gastrointestinal motility disorders in inflammatory bowel diseases. *World J Gastroenterol* 2014; 20: 37–44.
78. Akiho H, Ihara E, Motomura Y, *et al.* Cytokine-induced alterations of gastrointestinal motility in gastrointestinal disorders. *World J Gastrointest Pathophysiol* 2011; 2: 72–81.
79. Hilpüsch F, Johnsen PH, Goll R, *et al.* Microscopic colitis: a missed diagnosis among patients with moderate to severe irritable bowel syndrome. *Scand J Gastroenterol* 2017; 52: 173–177.
80. Spiegel BM, Farid M, Esrailian E, *et al.* Is irritable bowel syndrome a diagnosis of exclusion? A survey of primary care providers, gastroenterologists, and IBS experts. *Am J Gastroenterol* 2010; 105: 848–858.
81. Chey WD, Kurlander J and Eswaran S. Irritable bowel syndrome: a clinical review. *JAMA* 2015; 313: 949–958.
82. Defrees DN and Bailey J. Irritable bowel syndrome: epidemiology, pathophysiology, diagnosis, and treatment. *Prim Care* 2017; 44: 655–671.

83. Enck P, Aziz Q, Barbara G, et al. Irritable bowel syndrome. *Nat Rev Dis Prim* 2016; 2: 16014.
84. Black CJ. Review article: diagnosis and investigation of irritable bowel syndrome. *Aliment Pharmacol Ther* 2021; 54(Suppl. 1): S33–S43.
85. Black CJ and Ford AC. Best management of irritable bowel syndrome. *Frontline Gastroenterol* 2021; 12: 303–315.
86. Park HS, Han DS, Ro YO, et al. Does lymphocytic colitis always present with normal endoscopic findings? *Gut Liver* 2015; 9: 197–201.
87. Roth B, Gustafsson RJ and Ohlsson B. Auto-antibodies and their association with clinical findings in women diagnosed with microscopic colitis. *PLoS ONE* 2013; 8: e66088.
88. Terruzzi V and Minoli G. Collagenous colitis: a retrospective study of clinical presentation and treatment in 163 patients. *Gastrointest Endosc* 1997; 46: 200–201.
89. Raimo J, Coronel M, Criss A, et al. Collagenous colitis associated with protein losing enteropathy presenting with multiple venous thromboses. *Off J Am Coll Gastroenterol | ACG* 2010; 943: 105. [https://journals.lww.com/ajg/Fulltext/2010/10001/Collagenous\\_Colitis\\_Associated\\_with\\_Protein\\_Losing.943.aspx](https://journals.lww.com/ajg/Fulltext/2010/10001/Collagenous_Colitis_Associated_with_Protein_Losing.943.aspx)
90. Stark ME, Batts KP and Alexander GL. Protein-losing enteropathy with collagenous colitis. *Am J Gastroenterol* 1992; 87: 780–783.
91. Nakaya Y, Kaku Hosokawa S, Kataoka Y, et al. Acute onset collagenous colitis associated with protein-losing enteropathy. *J Gen Fam Med* 2017; 18: 135–138.
92. Hjortswang H, Tysk C, Bohr J, et al. Defining clinical criteria for clinical remission and disease activity in collagenous colitis. *Inflamm Bowel Dis* 2009; 15: 1875–1881.
93. Pihl Lesnovska K, Münch A and Hjortswang H. Microscopic colitis: struggling with an invisible, disabling disease. *J Clin Nurs* 2019; 28: 3408–3415.
94. Ogundipe OA and Campbell A. Microscopic colitis impacts quality of life in older people. *BMJ Case Rep* 2019; 12: 1–5.
95. Tome J, Kamboj AK and Pardi DS. Microscopic colitis: a concise review for clinicians. *Mayo Clin Proc* 2021; 96: 1302–1308.
96. Nyboe Andersen N, Munck LK, Hansen S, et al. All-cause and cause-specific mortality in microscopic colitis: a Danish nationwide matched cohort study. *Aliment Pharmacol Ther* 2020; 52: 319–328.
97. Bergman D, Khalili H, Roelstraete B, et al. Microscopic colitis and risk of cancer – a population-based cohort study. *J Crohn's Colitis* 2021; 15: 212–221.
98. Borsotti E, Barberio B, D'Inca R, et al. Low prevalence of colorectal neoplasia in microscopic colitis: a large prospective multi-center study. *Dig Liver Dis* 2021; 53: 846–851.
99. Lorinczy K, Lakatos G, Müllner K, et al. Low bone mass in microscopic colitis. *BMC Gastroenterol* 2011; 11: 58.
100. Greenberg I and Yen E. 221 Risk of bone density loss in microscopic colitis. *Off J Am Coll Gastroenterol | ACG* 2019; 114. [https://journals.lww.com/ajg/Fulltext/2019/10001/221\\_Risk\\_of\\_Bone\\_Density\\_Loss\\_in\\_Microscopic.221.aspx](https://journals.lww.com/ajg/Fulltext/2019/10001/221_Risk_of_Bone_Density_Loss_in_Microscopic.221.aspx)
101. Barta Z, Mekkel G, Csipo I, et al. Microscopic colitis: a retrospective study of clinical presentation in 53 patients. *World J Gastroenterol* 2005; 11: 1351–1355.
102. Sonnenberg A, Turner KO and Genta RM. Associations of microscopic colitis with other lymphocytic disorders of the gastrointestinal tract. *Clin Gastroenterol Hepatol* 2018; 16: 1762–1767.
103. Rönnblom A, Holmström T, Tanghøj H, et al. Celiac disease, collagenous sprue and microscopic colitis in IBD. Observations from a population-based cohort of IBD (ICURE). *Scand J Gastroenterol* 2015; 50: 1234–1240.
104. Stewart M, Andrews CN, Urbanski S, et al. The association of coeliac disease and microscopic colitis: a large population-based study. *Aliment Pharmacol Ther* 2011; 33: 1340–1349.
105. Abignano G, Scott N, Wollheim FA, et al. Collagenous colitis in systemic sclerosis: an overlooked and treatable complication. *J Clin Rheumatol* 2014; 20: 278–282.
106. Ekiz F, Coban S, Savas B, et al. Collagenous colitis in a patient with systemic sclerosis: a rare entity. *J Natl Med Assoc* 2007; 99: 681–682.
107. Gustafsson RJ, Roth B, Lantz M, et al. A cross-sectional study of subclinical and clinical thyroid disorders in women with microscopic colitis compared to controls. *Scand J Gastroenterol* 2013; 48: 1414–1422.
108. Cindoruk M, Tuncer C, Dursun A, et al. Increased colonic intraepithelial lymphocytes in patients with Hashimoto's thyroiditis. *J Clin Gastroenterol* 2002; 34: 237–239.
109. Sairenji T, Collins KL and Evans DV. An update on inflammatory bowel disease. *Prim Care – Clin off Pract* 2017; 44: 673–692.

110. Seyedian SS, Nokhostin F and Malimir MD. A review of the diagnosis, prevention, and treatment methods of inflammatory bowel disease. *J Med Life* 2019; 12: 113–122.
111. Guan Q. A comprehensive review and update on the pathogenesis of inflammatory bowel disease. *J Immunol Res* 2019; 2019: 7247238.
112. Khalili H, Burke K, Roelstraete B, *et al.* Microscopic colitis and risk of inflammatory bowel disease in a Nationwide Cohort Study. *Gastroenterology* 2020; 158: 1574–1583.
113. Carpenter HA, Tremaine WJ, Batts KP, *et al.* Sequential histologic evaluations in collagenous colitis. Correlations with disease behavior and sampling strategy. *Dig Dis Sci* 1992; 37: 1903–1909.
114. Bonderup OK, Fenger-Grøn M, Wigh T, *et al.* Drug exposure and risk of microscopic colitis: a nationwide Danish case-control study with 5751 cases. *Inflamm Bowel Dis* 2014; 20: 1702–1707.
115. Keszthelyi D, Penders J, Masclee AA, *et al.* Is microscopic colitis a drug-induced disease? *J Clin Gastroenterol* 2012; 46: 811–822.
116. Haidar A, Kaur S, Jackson N, *et al.* Medical treatment for microscopic colitis: a community hospital's experience. *Gastroenterology Res* 2017; 10: 329–333.
117. Miehke S, Acosta MB, Bouma G, *et al.* Oral budesonide in gastrointestinal and liver disease: a practical guide for the clinician. *J Gastroenterol Hepatol*. Epub ahead of print 30 March 2018. DOI: 10.1111/jgh.14151.
118. Miehke S, Madisch A, Voss C, *et al.* Long-term follow-up of collagenous colitis after induction of clinical remission with budesonide. *Aliment Pharmacol Ther* 2005; 22: 1115–1119.
119. Miehke S, Hansen JB, Madisch A, *et al.* Risk factors for symptom relapse in collagenous colitis after withdrawal of short-term budesonide therapy. *Inflamm Bowel Dis* 2013; 19: 2763–2767.
120. Ung KA, Gillberg R, Kilander A, *et al.* Role of bile acids and bile acid binding agents in patients with collagenous colitis. *Gut* 2000; 46: 170–175.
121. Chande N. Microscopic colitis: an approach to treatment. *Can J Gastroenterol* 2008; 22: 686–688.
122. Kafil TS, Nguyen TM, Patton PH, *et al.* Interventions for treating collagenous colitis. *Cochrane Database Syst Rev* 2017; 11: CD003575.
123. Fine KD and Lee EL. Efficacy of open-label bismuth subsalicylate for the treatment of microscopic colitis. *Gastroenterology* 1998; 114: 29–36.
124. Münch A, Bohr J, Vigren L, *et al.* Lack of effect of methotrexate in budesonide-refractory collagenous colitis. *Clin Exp Gastroenterol* 2013; 6: 149–152.
125. Munck LK, Kjeldsen J, Philipsen E, *et al.* Incomplete remission with short-term prednisolone treatment in collagenous colitis: a randomized study. *Scand J Gastroenterol* 2003; 38: 606–610.
126. Gentile NM, Abdalla AA, Khanna S, *et al.* Outcomes of patients with microscopic colitis treated with corticosteroids: a population-based study. *Am J Gastroenterol* 2013; 108: 256–259.
127. Sloth H, Bisgaard C and Grove A. Collagenous colitis: a prospective trial of prednisolone in six patients. *J Intern Med* 1991; 229: 443–446.
128. Miehke S, Madisch A, Kupcinkas L, *et al.* Budesonide is more effective than mesalamine or placebo in short-term treatment of collagenous colitis. *Gastroenterology* 2014; 146: 1222–1230e2.
129. Esteve M, Mahadevan U, Sainz E, *et al.* Efficacy of anti-TNF therapies in refractory severe microscopic colitis. *J Crohns Colitis* 2011; 5: 612–618.
130. Daferera N, Hjortswang H, Ignatova S, *et al.* Single-centre experience with anti-tumour necrosis factor treatment in budesonide-refractory microscopic colitis patients. *United European Gastroenterol J* 2019; 7: 1234–1240.
131. Pola S, Fahmy M, Evans E, *et al.* Successful use of infliximab in the treatment of corticosteroid dependent collagenous colitis. *Off J Am Coll Gastroenterol | ACG*. 2013; 108. [https://journals.lww.com/ajg/Fulltext/2013/05000/Successful\\_Use\\_of\\_Infliximab\\_in\\_the\\_Treatment\\_of.37.aspx](https://journals.lww.com/ajg/Fulltext/2013/05000/Successful_Use_of_Infliximab_in_the_Treatment_of.37.aspx)
132. Saad RE, Shobar R and Mutlu EA. Collagenous colitis development occurs after long standing mucosal healing in IBD with TNF-alpha inhibitors, and could be due to exaggerated healing response from excess TNF-alpha inhibition. *Med Hypotheses* 2019; 123: 90–94.
133. Cox TR and Erler JT. Remodeling and homeostasis of the extracellular matrix: implications for fibrotic diseases and cancer. *Dis Model Mech* 2011; 4: 165–178.

134. Taylor AJ, Ratner BD, Buttery LD, *et al.* Revealing cytokine-induced changes in the extracellular matrix with secondary ion mass spectrometry. *Acta Biomater* 2015; 14: 70–83.
135. Vaday GG and Lider O. Extracellular matrix moieties, cytokines, and enzymes: dynamic effects on immune cell behavior and inflammation. *J Leukoc Biol* 2000; 67: 149–159.
136. Fernandez IE and Eickelberg O. The impact of TGF- $\beta$  on lung fibrosis: from targeting to biomarkers. *Proc Am Thorac Soc* 2012; 9: 111–116.
137. Saito A, Horie M and Nagase T. TGF- $\beta$  signaling in lung health and disease. *Int J Mol Sci* 2018; 19: 1–18.
138. Ayers NB, Sun C and Chen SY. Transforming growth factor- $\beta$  signaling in systemic sclerosis. *J Biomed Res* 2018; 32: 3–12.
139. Varga J and Whitfield ML. Transforming growth factor-beta in systemic sclerosis (scleroderma). *Front Biosci (Schol Ed)* 2009; 1: 226–235.
140. Rivièrea P, Münchb A, Michettic P, *et al.* Vedolizumab in refractory microscopic colitis: an international case series. *J Crohn's Colitis* 2019; 13: 337–340.
141. Shipley LC, Ravi S, Russ KB, *et al.* Vedolizumab therapy in refractory microscopic colitis: a single center case series. *Clin Gastroenterol Hepatol* 2022; 20: 455–457.
142. Jennings JJ and Charabaty A. Vedolizumab-induced remission in 3 patients with refractory microscopic colitis: a tertiary care center case series. *Inflamm Bowel Dis* 2019; 25: E97.
143. Bowling TE, Price AB, al-Adnani M, *et al.* Interchange between collagenous and lymphocytic colitis in severe disease with autoimmune associations requiring colectomy: a case report. *Gut* 1996; 38: 788–791.
144. Yusuf TE, Soemijarsih M, Arpaia A, *et al.* Chronic microscopic enterocolitis with severe hypokalemia responding to subtotal colectomy. *J Clin Gastroenterol* 1999; 29: 284–288.
145. Varghese L, Galandiuk S, Tremaine WJ, *et al.* Lymphocytic colitis treated with proctocolectomy and ileal J-pouch-anal anastomosis: report of a case. *Dis Colon Rectum* 2002; 45: 123–126.

Visit SAGE journals online  
[journals.sagepub.com/  
 home/taj](https://journals.sagepub.com/home/taj)

 SAGE journals