



A critical appraisal on the treatment of acute appendicitis in pediatric population during the COVID-19 pandemic

Wireko A. Awuah, MBBS^a, Jyi C. Ng, MD^b, Aashna Mehta, MD^c, Helen Huang, MB, BCH, BAO^d, Toufik Abdul-Rahman, MBBS^a, Jacob Kalmanovich, BS, MD^e, Esther P. Nansubuga, MBChB, MSc^g, Katherine Candelario, MD^f, Mohammad M. Hasan, MSc^{h,*}, Arda Isik, FACSⁱ

Abstract

Acute appendicitis is one of the most common causes of abdominal pain in children. During the coronavirus disease 2019 (COVID-19) pandemic, a delay in presentation to the emergency department and a higher rate of complicated appendicitis were observed. Traditionally, operative management (laparoscopic or open appendectomy) was thought to be the best treatment strategy for acute appendicitis. However, nonoperative management with antibiotics has gained popularity in managing pediatric appendicitis during the COVID-19 era. The pandemic has posed significant challenges in the management of acute appendicitis. Cancellation of elective appendectomies, delay in seeking care due to fear of contracting COVID-19 infection, and impact of COVID-19 infection in the pediatric population have resulted in higher rates of complications. Furthermore, multiple studies have reported multisystem inflammatory syndrome in children mimicking acute appendicitis, subjecting patients to unnecessary surgery. Therefore, it is imperative to update the treatment guidelines for the management of acute appendicitis in the pediatric population during and after COVID-19 times.

Keywords: appendicitis, COVID-19, pediatric population

Introduction

Acute appendicitis is a gastrointestinal condition characterized by the inflammation of the vermiform appendix and presents as the most common cause of abdominal pain in all demographics^[1]. Though morbidity is low in children, around half of the pediatric appendicitis cases lack classic symptoms that make it difficult to

HIGHLIGHTS

- Acute appendicitis is one of the most common causes of abdominal pain in children.
- The diagnosis of pediatric appendicitis is difficult due to variations in clinical symptoms.
- Treatment of appendicitis has evolved over time with unique implications for children.
- It is important to consider recent updates in the treatment and management of pediatric appendicitis in the coronavirus disease 2019 era.

^aSummy State University, Sumy, Ukraine, ^bFaculty of Medicine and Health Sciences, University of Putra Malaysia, Serdang, Malaysia, ^cFaculty of Medicine, University of Debrecen, Debrecen, Hungary, ^dRoyal College of Surgeons in Ireland, University of Medicine and Health Sciences, Dublin, Ireland, ^eDrexel University College of Medicine, Philadelphia, Pennsylvania, ^fDivision of Cardiac Surgery, Clinical Outcome Research Group, Yale University, New Haven, Connecticut, USA, ^gLeeds Medical School, University of Leeds, Leeds, UK, ^hDepartment of Biochemistry and Molecular Biology, Faculty of Life Science, Mawlana Bhashani Science and Technology University, Tangail, Bangladesh and ⁱDepartment of General Surgery, Istanbul University, Istanbul, Turkey

Wireko A. Awuah and Jyi C. Ng made equal contributions and are joint first authors. Sponsorships or competing interests that may be relevant to content are disclosed at the end of this article.

*Corresponding author. Address: Mawlana Bhashani Science and Technology University, Tangail, Bangladesh. E-mail address: mehedi.bmb.mbstu@gmail.com (M.M. Hasan).

Copyright © 2023 The Author(s). Published by Wolters Kluwer Health, Inc. This is an open access article distributed under the terms of the Creative Commons Attribution-Non Commercial-No Derivatives License 4.0 (CCBY-NC-ND), where it is permissible to download and share the work provided it is properly cited. The work cannot be changed in any way or used commercially without permission from the journal.

Annals of Medicine & Surgery (2023) 85:868–874

Received 30 August 2022; Accepted 22 December 2022

Published online 16 March 2023

<http://dx.doi.org/10.1097/MS9.000000000000111>

diagnose and can increase the risk of perforation^[2]. The cause of acute appendicitis is commonly due to an obstruction of the lumen as a result of stone blockages or appendiceal tumors such as carcinoid tumors or parasites^[1]. The degree and severity of acute appendicitis depend on the extent of inflammation within the muscularis propria^[3]. The characteristic symptoms of appendicitis are widespread and frequently appear as periumbilical abdominal pain that is localized to the right lower quadrant (RLQ)^[4]. Pediatric appendicitis is extremely rare within the first 24 h after life, with symptoms appearing within 48 h^[4]. Appendicitis is more common in children between the age 10 and 19 years old^[3]. Due to the danger of higher perforations in these populations, it is critical to treat juvenile appendicitis as soon as possible. However, the coronavirus disease 2019 (COVID-19) pandemic may have made rapid treatment of such a disorder problematic.

The impact of COVID-19 on healthcare facilities was disastrous since elective surgery had to be canceled, and the number of patients hospitalized in the critical care unit with severe

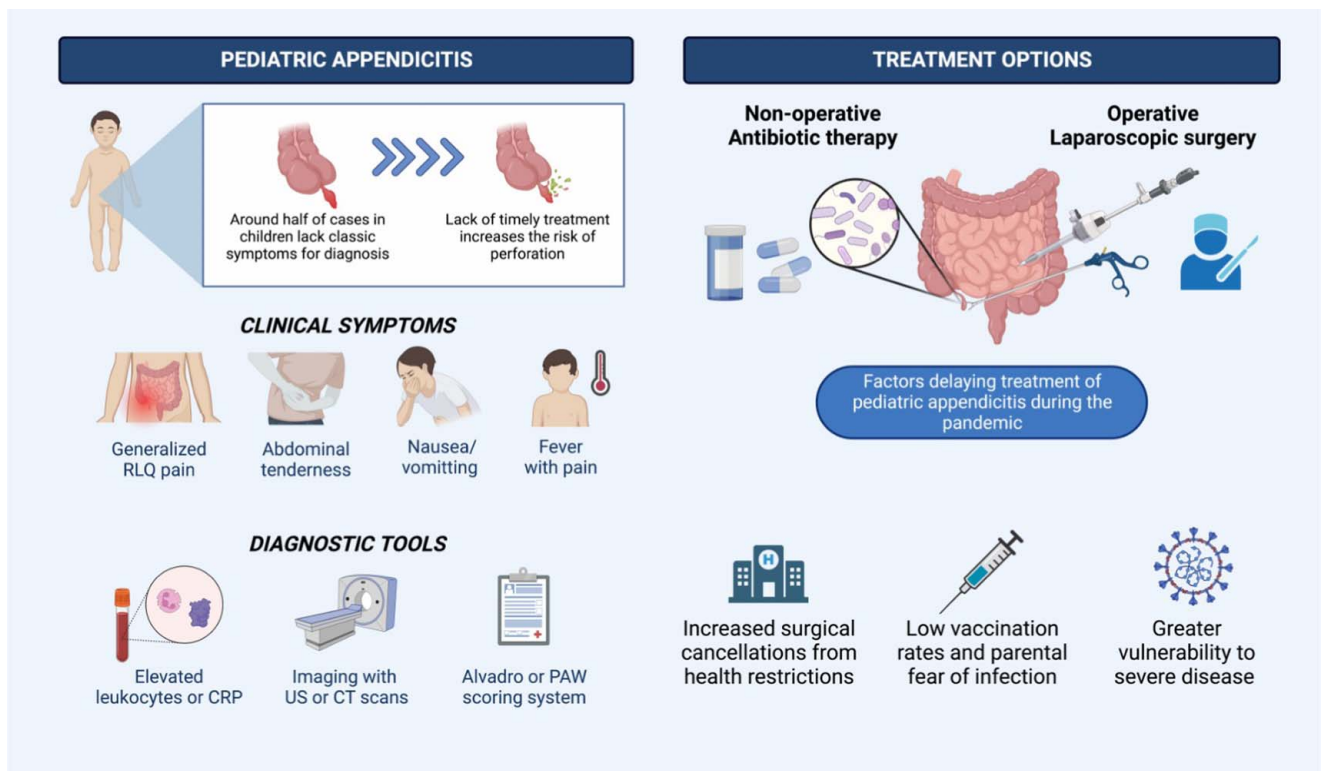


Figure 1. A general overview of clinical presentation and treatment guidelines for pediatric appendicitis.

COVID-19 symptoms increased dramatically^[5]. This could cause a delay in the treatment of all cases, including pediatric appendicitis. The risk of perforation in pediatric appendicitis during the pandemic has become a topic of interest as management strategies to reduce viral transmission and delay in reaching timely care have been reassessed. While existing treatment regimens (Fig. 1) for the pediatric population are well established, there is still a need to discover the appropriate forms of therapy during the pandemic to enhance the rapid treatment of appendicitis while also adhering to public health limitations^[6]. This review highlights the effects of COVID-19 on pediatric appendicitis with recommendations.

Surgical anatomy and physiology of the appendix

The appendix, also known as the vermiform appendix, is a 5–10 cm small pouch on the right side of the abdomen with a narrow lumen. The appendix connects to the cecum at its posteromedial aspect after leaving the large intestine and has a free end in the abdominal space^[7]. The appendix is supported by the mesoappendix, a fold of mesentery that connects the ileum to the appendix and contains the appendicular artery, which is derived from the superior mesenteric artery, and the appendicular vein, which is responsible for the appendix’s venous drainage^[7]. The lymphatic drainage of the vermiform appendix follows the artery route from the lymph nodes in the mesoappendix to the ileocolic and superior mesenteric lymph nodes. The appendix receives its sympathetic and parasympathetic nerve supply from the ileocolic branch of the superior mesenteric plexus^[7].

Many researchers are baffled by the function of the vermiform appendix, which was previously defined as a vestigial organ. However, immunologists at Duke University recently discovered biofilms of beneficial bacteria concentrated in the appendix^[8]. The biofilms would colonize the mammal’s large intestine and help maintain digestive function and pathogenic protection in a symbiotic relationship. In humans, biofilms were found to be most densely concentrated in the vermiform appendix, implying that it serves as a potential reservoir for gut bacteria^[8].

Prevalence and epidemiology of acute appendicitis in vulnerable populations

Acute appendicitis is a common surgical emergency, particularly among the elderly, pregnant women, and children. The elderly have a much lower incidence of acute appendicitis than the younger population. However, the mortality rate among patients over the age of 65 is higher, reaching up to 8%^[9]. One of the most common nonobstetric emergencies is acute appendicitis. One in every 25 women of reproductive age who presented with appendicitis was pregnant, and pregnant women were more likely to have complicated appendicitis^[10]. Also, acute appendicitis accounts for nearly 8% of abdominal pain in children^[11,12], with a high rate of misdiagnosis. Misdiagnosis is nearly 100% in children aged 2 years or younger, 28–57% in children aged 2–12, and less than 15% in adolescents^[11].

A systematic review by Köhler *et al.*^[13] revealed a 13.4% increase in the incidence of appendicitis in children during the COVID-19 era. Pogorelić *et al.*^[14] also reported a significantly higher incidence of complicated appendicitis during the

Downloaded from https://journals.lww.com/annals-of-medicine-and-surgery by BMDjUserPKav12Eoum11QIN44+ on 07/21/2023

appendicitis begins with intravenous fluid resuscitation, broad-spectrum antibiotics, and a NPO (nil per os – nothing by mouth) prescription for patients. Antibiotics should be given post-operatively as well, 24 h for simple appendicitis and a 10-day regimen for complicated cases. This regimen should include ampicillin, gentamicin, and metronidazole or clindamycin, as these are the gold standard^[29].

In pediatric populations, transumbilical laparoscopic-assisted appendectomy and laparoscopic-assisted single-port appendectomy have been performed and found to be safe^[31]. As time passes, laparoscopic surgery has overtaken the use of open surgical techniques for children. This is mainly because it has lower infection rates and quicker recovery times, which is part of the main goals in the surgical treatment of appendicitis^[31]. Minimization of complications and costs, while improving the quality of life is the mainstay of the management of acute appendicitis in children. Currently, many hospitals will perform appendectomies during the first 8 h of clinical presentation and diagnosis. Complication and perforation rates are worsened when the case is an emergency, presenting possible perforation^[30].

Multiple approaches can be used in the laparoscopic management of acute appendicitis. These include three-port or single-port/incision interventions and transumbilical techniques^[30]. Disadvantages to this treatment include increased cost of equipment, extended surgical time, the time needed to learn laparoscopic techniques, and higher rates of intra-abdominal infections. Stump management is something that is completely up to the surgeon's discretion^[30]. Different techniques may be used, including simple ligation, inversion with a purse string, or, finally, pure inversion without ligature. Complication rates are typically lower in this approach; however, until recently, it was believed that intra-abdominal abscess rates are higher with laparoscopy. A meta-analysis found there were no differences in abscess rates after laparoscopic surgery in comparison to an open technique in the case of acute appendicitis^[30]. After surgery, drain usage is always in question. It has been recommended that irrigation of the abdomen not be done in cases of simple appendicitis; however, it may be used in complicated cases. Studies have shown, more recently, that irrigation in the case of perforated appendicitis in patients with peritoneal contamination was not necessary^[31].

In conclusion, the laparoscopic approach is the safest and most effective technique in the treatment of simple pediatric appendicitis. Complicated cases may require other approaches or mixed techniques^[31].

Nonoperative management

Aside from surgical intervention, nonoperative care, such as antibiotic administration, is another treatment option for juvenile appendicitis. Numerous studies have found success with the use of antibiotics in the short term. Minneci *et al.*^[32] conducted a prospective cohort study to compare the efficacy of nonoperative management to appendectomy. The children in their trial ranged in age from 7 to 17, and those in the nonoperative group were given piperacillin and tazobactam, a combination whose effects target penicillin and beta-lactamase inhibitors^[32].

This combination is commonly used to treat appendicitis because it kills germs while also preventing their growth. This therapy had a 95% initial success rate in the Minneci experiment,

but after 21 months, 9 of the children had appendectomy, lowering the success rate to 76%^[32]. In a meta-analysis, Huang *et al.*^[33] discovered similar results. This meta-analysis compared antibiotic treatment to appendectomy in five separate controlled studies. The antibiotic-only group had an initial success rate of 90.5%, but this percentage dropped after 1 year due to a 26.8 recurrence rate that required appendectomy^[33]. These findings show that antibiotics alone can be effective in treating uncomplicated appendicitis, allowing for a shorter hospital stay and full rehabilitation. These outcomes, however, vary depending on the disease's complexity and severity.

Appendicolith, a rocky feces congestion that can cause blockage, is a type of complication that can develop in conjunction with appendicitis. Multiple studies have found that people with appendicitis with an appendicolith experience severe pain, antibiotic perforation, and reduced efficacy of antibiotic-only therapy, necessitating appendectomy in up to 50% of cases for full treatment^[33,34].

Changes to the management of pediatric appendicitis during the COVID-19 era

The management of acute appendicitis in the pediatric population during the COVID-19 pandemic differs across institutions. A systematic review involving studies from seven different countries found that children with acute appendicitis were more likely to receive antibiotic treatment instead of appendectomy^[13]. 17.5% of children with acute appendicitis were treated with antibiotics during the COVID-19 era as compared to the pre-pandemic era, where only 4.7% received antibiotic treatment^[13]. Another meta-analysis by Pogorelič *et al.*^[14] found that a significantly higher proportion of children received nonoperative management during the pandemic as compared to the pre-pandemic era. Another retrospective study in New York City during the peak of the pandemic also revealed significantly more children with acute appendicitis were treated conservatively with antibiotics^[17]. However, the study also revealed that 50% of the patients returned to the emergency department for failed treatment^[17]. The study also revealed significantly longer lengths of stay and symptom resolution following initial treatment during the pandemic^[17]. However, the length of stay and duration until symptom resolution were not related to the type of treatment received^[17]. The worse outcome may be attributed to a delay in presentation to the emergency department with a more severe disease^[17].

In contrast, a few studies have reported operative treatment as the preferred option. Eighty-one percent of patients in the study by Yock-Corrales *et al.*^[35] underwent surgery. Malhotra *et al.*^[36] also reported that 8 out of 10 patients underwent appendectomy. A retrospective study in Australia and New Zealand showed that the management of pediatric acute appendicitis remained the same during the pandemic, when almost all patients underwent laparoscopic appendectomy^[21].

In the midst of the COVID-19 pandemic, the best surgical approach (open vs. laparoscopic appendectomy) is still being debated, as there was no significant evidence to support that the inhalation of surgical smoke associated with laparoscopic surgeries increases the risk of COVID-19 infection^[37]. Studies have suggested the preference for antibiotic treatment is to reduce the risk of COVID-19 infection associated with intubation or the

surgery^[38]. However, antibiotic treatment has been found to result in longer hospital stays which, in turn, increases the risk for nosocomial COVID-19 infections^[39]. Therefore, there is a need to establish guidelines for the management of pediatric appendicitis during and after the COVID-19 pandemic.

Challenges to the treatment of pediatric appendicitis during the COVID-19 pandemic

The COVID-19 pandemic has resulted in historically high rates of acute complicated pediatric appendicitis. The incidence of acute pediatric complicated appendicitis increased during the COVID-19 pandemic, according to multicenter studies, with some studies showing that the time of symptom onset was longer in COVID-19-infected patients and the rate of postoperative complications was higher. On the contrary, some studies have found that pediatric appendicitis did not rise during the pandemic. Given the controversy surrounding the prevalence of this condition during the COVID-19 outbreak, it is critical to look into the factors that make effective treatment difficult.

One of the challenges posed by the COVID-19 pandemic is a general decrease in preformed appendectomies, which could lead to symptom exacerbation. Overall, the pandemic has reduced healthcare visits and elective surgeries. An analysis of surgical data from 193 countries over a 12-week period revealed an overall cancellation rate of 72.3% for all elective procedures, which could include elective appendectomies for acute uncomplicated appendicitis^[40]. National emergency department volumes, for example, were down nearly 50% overall and 60% in pediatric emergency departments^[41]. This could be attributed to people's reluctance to seek health care due to the fear of contracting a disease – COVID-19. When focusing on appendicitis patients in the emergency department, one study examined EMR (electronic medical record) data from 146 different hospitals and discovered a 25.4% drop in overall acute appendicitis patient admissions and a 33.8% drop in the pediatric patient population in April 2020^[42]. The combination of low visitation rates and an increase in surgical cancellations may cause an increase in the severity of previous acute cases due to a lack of treatment.

Children were the last to be immunized against COVID-19, which may have influenced their willingness to seek treatment during the pandemic. The authors discovered in an international cross-sectional study that most caregivers intend to vaccinate their child against COVID-19, with the main reason being to protect their child^[43]. As a result, parents may be hesitant to bring their children to the hospital before they have been vaccinated, increasing the severity of their initial presentation. According to a cohort study conducted at a pediatric hospital, the number of perforated appendicitis cases increased by 20% during the COVID-19 pandemic in 2020 compared to the same period in 2019^[44]. The study also revealed that the parents showed signs of anxiety in the emergency department and openly expressed their reluctance to visit the hospital due to concerns about contracting COVID-19^[41]. This was most noticeable in the pediatric population, where parental concern and fear of COVID-19 infection was a major factor in significant delays in seeking treatment for nonemergent illnesses^[17]. As a result, a low rate of COVID-19 vaccination in children, combined with parental fear, indirectly increases the severity of acute appendicitis presentation in the

pediatric population, resulting in a more complicated course of management.

The study also revealed that the parents showed signs of anxiety in the emergency department and openly expressed reluctance to visit the hospital due to concerns about contracting COVID-19^[41]. This was most noticeable in the pediatric population, where parental concern and fear of COVID-19 infection was a major factor in significant delays in seeking treatment for nonemergent illnesses^[17]. Also, patients in the COVID-19 group had slower symptom development, longer hospital stays, higher rates of complicated appendicitis, and higher incidence rates, according to a similar study^[45]. All of the issues raised highlight the significant burdens that pediatric appendicitis patients face as a result of the pandemic.

Another significant challenge in the management of acute appendicitis during the pandemic is the possible misdiagnosis of acute appendicitis as a multisystem inflammatory syndrome in children (MIS-C) or vice versa^[46–48]. Ninety-two percent of patients with MIS-C reported gastrointestinal involvement^[49]. A systematic review revealed that 18.7% of patients with MIS-C presented with an acute abdomen^[50]. Even though the presentation of both MIS-C and acute appendicitis may be similar^[51], however, the treatment modality is different MIS-C patients usually receive nonoperative management, while patients with acute appendicitis require appendectomy^[35,47,50]. Yock-Corrales *et al.*^[35] found that more than 10% of the children who underwent appendectomy for suspected appendicitis had nonsurgical findings, while another systematic review found that laparotomy was proven unnecessary in more than 50% of the cases^[50]. Patients with MIS-C misdiagnosed as acute appendicitis may be subjected to unnecessary surgery^[35,48,52], and therefore, clinicians should be aware of both diagnoses. In addition, patients may have concurrent MIS-C and acute appendicitis, which lead to a severe course of illness^[47].

Recommendations

The prevalence of appendicitis in children is well documented, and appendectomy has long been the gold standard of treatment. However, during the COVID-19 era, nonoperative management of nonperforated acute appendicitis in the pediatric population has grown in popularity. Conservative antibiotic management has been shown to be safe and effective in treating uncomplicated appendicitis, and it may be beneficial during and after the pandemic. Given the significant surgical backlog associated with COVID-19, choosing conservative management may reduce the surgical burden. Besides, nonoperative management is cost-reducing and may be less traumatizing to children. However, more research is needed to identify the factors influencing the outcome of nonoperative treatment so that inclusion and exclusion criteria can be established when selecting treatment options for children. Large randomized controlled trials are also required to compare the outcomes of nonoperative treatment with appendectomy. Although nonoperative therapy may be favorable, gaps in knowledge must be addressed before reevaluating the method of managing acute appendicitis in children. There are currently no established guidelines for managing pediatric acute appendicitis during and after the COVID-19 era. Due to a delay in the presentation and an increase in the severity of acute appendicitis in children during the pandemic, treatment

guidelines need to be revised. Furthermore, clinicians should also be aware of the similarity in presentation between pediatric COVID-19 infection, MIS-C, and acute appendicitis to prevent misdiagnosis and unnecessary surgery. Further research is needed to better understand the real impact of the COVID-19 pandemic on pediatric appendicitis, including studies that compare the results in these cases encountered during the pandemic to those found before the pandemic. The existing information pool on this is insufficient, and expanding it might allow for better updates to treatment regimens, perhaps leading to improved patient results.

Conclusion

Appendicitis is a major cause of abdominal pain in the pediatric population, considering the interesting range of clinical symptoms as well as the absence of typical symptoms in infants, and toddlers who may not be able to communicate them well. The pandemic has posed significant challenges in the management of acute appendicitis. Cancellation of elective appendectomies, delay in seeking care due to fear of contracting COVID-19 infection, and impact of COVID-19 infection in the pediatric population have led to higher rates of complications. Furthermore, the similarity in the presentation of pediatric appendicitis, COVID-19 infection, and MIS-C have led to misdiagnosis and unnecessary surgeries. Therefore, it is imperative to update the treatment guidelines for the management of acute appendicitis in the pediatric population during the COVID-19 pandemic.

Ethical approval

NA.

Patient consent

NA.

Funding statement

The authors have no funding details to declare.

Author contribution

W.A.A., T.A.-R., A.M., and J.C.N.: conceptualized the topic, coordinated reading, writing, and editing. All authors contributed to reading, writing, editing the original draft, and critical revision. All authors contributed to various aspects of reading, data collection, writing the original draft, and implementing changes for critical revision under the supervision of W.A.A., A.M., J.C.N., and A.I.

Conflicts of interest disclosure

The authors have no conflicts of interest to declare.

Research registration unique identifying number (UIIN)

None

Guarantor

Mohammad Mehedi Hasan, Department of Biochemistry and Molecular Biology, Faculty of Life Science, Mawlana Bhashani Science and Technology University, Tangail, Bangladesh; E-mail: mehedi.bmb.mbstu@gmail.com.

Data availability statement

No data are available.

Provenance and peer review

Not commissioned, externally peer reviewed

Acknowledgments

We acknowledge Icorned Research Collaborative and Toufik's World Medical Association for coming up with this project.

References

- [1] Jones MW, Lopez RA, Deppen JG. Appendicitis. StatPearls Publishing; 2022.
- [2] Lee SL, Ho HS. Acute appendicitis: is there a difference between children and adults? *Am Surg* 2006;72:409–13.
- [3] Gadiparthi R, Waseem M. Pediatric Appendicitis. StatPearls Publishing; 2022.
- [4] Rentea RM, Peter SDS, Snyder CL. Pediatric appendicitis: state of the art review. *Pediatr Surg Int* 2017;33:269–83.
- [5] Vanhems P, Gustin MP, Elias C, *et al.* Factors associated with admission to intensive care units in COVID-19 patients in Lyon-France. *PLoS One* 2021;16:e0243709.
- [6] Percul C, Cruz M, Curiel Meza A, *et al.* Impact of the COVID-19 pandemic on the pediatric population with acute appendicitis: experience at a general, tertiary care hospital. *Impacto de la pandemia por COVID-19 en la población pediátrica con apendicitis aguda: experiencia en un hospital general de tercer nivel. Arch Argent Pediatr* 2021;119:224–9.
- [7] Smith HF. A review of the function and evolution of the cecal appendix. *Anat Rec (Hoboken)* 2022. doi:10.1002/ar.24917
- [8] Smith HF, Fisher RE, Everett ML, *et al.* Comparative anatomy and phylogenetic distribution of the mammalian cecal appendix. *J Evol Biol* 2009;22:1984–99.
- [9] Fugazzola P, Ceresoli M, Agnoletti V, *et al.* The SIFIPAC/WSES/SICG/SIMEU guidelines for diagnosis and treatment of acute appendicitis in the elderly (2019 edition). *World J Emerg Surg* 2020;15:19.
- [10] Vasileiou G, Eid AI, Qian S, *et al.* Appendicitis in pregnancy: a post-hoc analysis of an EAST Multicenter Study. *Surg Infect (Larchmt)* 2020;21:205–11.
- [11] Almaramhy HH. Acute appendicitis in young children less than 5 years: review article. *Ital J Pediatr* 2017;43:15.
- [12] Lee WH, O'Brien S, Skarin D, *et al.* Pediatric abdominal pain in children presenting to the emergency department. *Pediatr Emerg Care* 2021;37:593–8.
- [13] Köhler F, Müller S, Hendricks A, *et al.* Changes in appendicitis treatment during the COVID-19 pandemic – a systematic review and meta-analysis. *Int J Surg* 2021;95:106148.
- [14] Pogorelič Z, Anand S, Žuvela T, *et al.* Incidence of complicated appendicitis during the COVID-19 pandemic versus the pre-pandemic period: a systematic review and meta-analysis of 2782 pediatric appendectomies. *Diagnostics (Basel)* 2022;12:127.
- [15] Motazedian G, Aryanpoor P, Rahmanian E, *et al.* Incidence of pediatric perforated appendicitis during the COVID-19 pandemic; a systematic review and meta-analysis. *Arch Acad Emerg Med* 2021;10:e3.
- [16] Fisher JC, Tomita SS, Ginsburg HB, *et al.* Increase in pediatric perforated appendicitis in the New York City metropolitan region at the epicenter of the COVID-19 outbreak. *Ann Surg* 2021;273:410–5.

- [17] Gerall CD, DeFazio JR, Kahan AM, *et al.* Delayed presentation and sub-optimal outcomes of pediatric patients with acute appendicitis during the COVID-19 pandemic. *J Pediatr Surg* 2021;56:905–10.
- [18] Snapiri O, Rosenberg Danziger C, Krause I, *et al.* Delayed diagnosis of paediatric appendicitis during the COVID-19 pandemic. *Acta Paediatr* 2020;109:1672–6.
- [19] Taşçı A, Gürünlüoğlu K, Yıldız T, *et al.* Impact of COVID-19 pandemic on pediatric appendicitis hospital admission time and length of hospital stay. COVID-19 pandemi sürecinin çocuk apandisitlerinde hastane başvuru süresi ve hastane kalış süresine etkileri. *Ulus Travma Acil Cerrahi Derg* 2022;28:1095–9.
- [20] Nassiri AM, Pruden RD, Holan CA, *et al.* Pediatric appendicitis in the time of the COVID-19 pandemic: a retrospective chart review. *J Am Coll Emerg Physicians Open* 2022;3:e12722.
- [21] ANZSCRAFT Collaborative and Kiera Roberts.. Impact of COVID-19 on appendicitis presentations in children in Australia and New Zealand. *ANZ J Surg* 2022;92:736–41.
- [22] Stringer MD. Acute appendicitis. *J Paediatr Child Health* 2017;53:1071–6.
- [23] Addiss DG, Shaffer N, Fowler BS, *et al.* The epidemiology of appendicitis and appendectomy in the United States. *Am J Epidemiol* 1990;132:910–25.
- [24] Fraser N, Gannon C, Stringer MD. Appendicular colic and the non-inflamed appendix: fact or fiction? *Eur J Pediatr Surg* 2004;14:21–4.
- [25] Paulson EK, Kalady MF, Pappas TN. Clinical practice. Suspected appendicitis. *N Engl J Med* 2003;348:236–42.
- [26] Peña BM, Taylor GA, Fishman SJ, *et al.* Costs and effectiveness of ultrasonography and limited computed tomography for diagnosing appendicitis in children. *Pediatrics* 2000;106:672–6.
- [27] Doria AS, Moineddin R, Kellenberger CJ, *et al.* US or CT for diagnosis of appendicitis in children and adults? A meta-analysis. *Radiology* 2006;241:83–94.
- [28] Hansen LW, Dolgin SE. Trends in the diagnosis and management of pediatric appendicitis. *Pediatr Rev* 2016;37:52–8.
- [29] Zavras N, Vaos G. Management of complicated acute appendicitis in children: still an existing controversy. *World J Gastrointest Surg* 2020;12:129–37.
- [30] Snyder MJ, Guthrie M, Cagle S. Acute appendicitis: efficient diagnosis and management. *Am Fam Physician* 2018;98:25–33.
- [31] Erikci VS. Management of pediatric appendicitis. In: Garbuzenko DV, editor. *Current Issues in the Diagnostics and Treatment of Acute Appendicitis*. IntechOpen; 2018.
- [32] Minneci PC, Mahida JB, Lodwick DL, *et al.* Effectiveness of patient choice in nonoperative vs surgical management of pediatric uncomplicated acute appendicitis. *JAMA Surg* 2016;151:408–15.
- [33] Huang L, Yin Y, Yang L, *et al.* Comparison of antibiotic therapy and appendectomy for acute uncomplicated appendicitis in children: a meta-analysis. *JAMA Pediatr* 2017;171:426–34.
- [34] Yoon HM, Kim JH, Lee JS, *et al.* Pediatric appendicitis with appendicolith often presents with prolonged abdominal pain and a high risk of perforation. *World J Pediatr* 2018;14:184–90.
- [35] Yock-Corrales A, Lenzi J, Ulloa-Gutiérrez R, *et al.* Acute abdomen and appendicitis in 1010 pediatric patients with COVID-19 or MIS-C: a multinational experience from Latin America. *Pediatr Infect Dis J* 2021;40:e364–9.
- [36] Malhotra A, Sturgill M, Whitley-Williams P, *et al.* Pediatric COVID-19 and appendicitis: a gut reaction to SARS-CoV-2? *Pediatr Infect Dis J* 2021;40:e49–55.
- [37] Antunes D, Lami M, Chukwudi A, *et al.* COVID-19 infection risk by open and laparoscopic surgical smoke: a systematic review of the literature. *Surgeon* 2021;19:e452–61.
- [38] Ielpo B, Podda M, Pellino G, *et al.* Global attitudes in the management of acute appendicitis during COVID-19 pandemic: ACIE Appy Study. *Br J Surg* 2021;108:717–26.
- [39] Pata F, Podda M, Di Saverio S. A randomized trial comparing antibiotics with appendectomy for appendicitis. *N Engl J Med* 2021;384:880.
- [40] COVIDSurg Collaborative.. Global guidance for surgical care during the COVID-19 pandemic. *Br J Surg* 2020;107:1097–103.
- [41] Westgard BC, Morgan MW, Vazquez-Benitez G, *et al.* An analysis of changes in emergency department visits after a state declaration during the time of COVID-19. *Ann Emerg Med* 2020;76:595–601.
- [42] Rosenthal MG, Fakhry SM, Morse JL, *et al.* Where did all the appendicitis go? Impact of the COVID-19 pandemic on volume, management, and outcomes of acute appendicitis in a nationwide, multicenter analysis. *Ann Surg* 2021;2:e048.
- [43] Goldman RD, Yan TD, Seiler M, *et al.* Caregiver willingness to vaccinate their children against COVID-19: cross sectional survey. *Vaccine* 2020;38:7668–73.
- [44] Place R, Lee J, Howell J. Rate of pediatric appendiceal perforation at a children's hospital during the COVID-19 pandemic compared with the previous year. *JAMA Netw Open* 2020;3:e2027948.
- [45] Delgado-Miguel C, Muñoz-Serrano AJ, Miguel-Ferrero M, *et al.* Complicated acute appendicitis during COVID-19 pandemic: the hidden epidemic in children. *Eur J Pediatr Surg* 2022;32:268–73.
- [46] Jackson RJ, Chavarria HD, Hacking SM. A case of multisystem inflammatory syndrome in children mimicking acute appendicitis in a COVID-19 pandemic area. *Cureus* 2020;12:e10722.
- [47] Anderson JE, Campbell JA, Durowoju L, *et al.* COVID-19-associated multisystem inflammatory syndrome in children (MIS-C) presenting as appendicitis with shock. *J Pediatr Surg Case Rep* 2021;71:101913.
- [48] Shahbaznejad L, Navaeifar MR, Abbaskhanian A, *et al.* Clinical characteristics of 10 children with a pediatric inflammatory multi-system syndrome associated with COVID-19 in Iran. *BMC Pediatr* 2020;20:513.
- [49] Feldstein LR, Rose EB, Horwitz SM, *et al.* Multisystem inflammatory syndrome in U.S. children and adolescents. *N Engl J Med* 2020;383:334–46.
- [50] Rouva G, Vergadi E, Galanakis E. Acute abdomen in multisystem inflammatory syndrome in children: a systematic review. *Acta Paediatr* 2022;111:467–72.
- [51] Nurnaningsih DGI, Rusmawatingtyas D, Kumara IF, *et al.* Acute appendicitis in pediatric patients with coronavirus disease 2019 (COVID-19): a case series from a developing country's tertiary hospital. *Ann Med Surg (Lond)* 2022;74:103315.
- [52] Webb K, Abraham DR, Faleye A, *et al.* Multisystem inflammatory syndrome in children in South Africa. *Lancet Child Adolesc Health* 2020;4:e38.