



# Comparative use of ultrasound and radiography for the detection of fractures: a systematic review and narrative synthesis

Jesús Endara-Mina<sup>a</sup>, Harendra Kumar<sup>b</sup>, Bikona Ghosh<sup>e,\*</sup>, Aashna Mehta<sup>f</sup>, Rohit Chandra Dey<sup>g</sup>, Pramod Singh<sup>c</sup>, Niraj Rai<sup>d</sup>, Manosri Mandadi<sup>h</sup>, Olivia Opara<sup>i</sup>, Jonathan Quinonez<sup>j</sup>

**Background:** Traditionally, X-rays have remained the standard modality for bone fracture diagnosis. However, other diagnostic modalities most notably ultrasound have emerged as a simple, radiation-safe, effective imaging tool to diagnose bone fractures. Despite the advantages, there is a prevalent scarcity of literature recognizing its significance in bone trauma management. This review investigates the effectiveness of ultrasound in the diagnosis of various bone fractures when compared to conventional radiography such as X-rays.

**Methodology:** Electronic databases such as PubMed/Medline, SCOPUS, and Web of Science (WOS) were reviewed for observational studies and review articles from the years 2017–2022 utilizing MESH terminology in a broad term search strategy. The search returned a total of 248 articles. After removal of duplicates, abstract, and full-text screening this systematic review ultimately utilized data from 31 articles. All searches were performed and analyzed according to the Preferred Reporting Items for Systematic Reviews and Meta-Analysis (PRISMA) methodology and were conducted during August 2022. In accordance with the guidelines for assessing the quality of included systematic reviews, we used the AMSTAR 2020, Supplemental Digital Content 2, <http://links.lww.com/MS9/A241> (A Measurement Tool to Assess Systematic Reviews) tool to evaluate the methodological quality of the included studies. A data extraction form based on the Cochrane Consumers and Communication Review group's extraction template for quality assessment and evidence synthesis was used for data extraction. The information extracted included details such as author information, database, journal details, type of study, etc. Studies included will be classified into long bones, short bones, pneumatic bones, irregular bones, ankle and knee, stress fractures, hip fractures, POCUS, and others. All included studies considered bias and ethical criteria and provided valuable evidence to answer the research question.

**Results:** The search returned a total of 248 articles, with 192 articles remaining after the removal of duplicates. Primary screening of the title and abstract articles from the database search and additional sources identified 68 relevant articles for full-text screening. This systematic review ultimately used data from 33 articles of the remaining articles we included all of them because they had more than 70% certainty, using the STROBE tool for observational articles, narrative reviews with the ENTREQ guide, and systematic reviews and meta-analyses with the PRISMA guide; however, two articles were excluded at the eligibility stage because of risk of bias.

**Conclusion:** This systematic review provides insightful evidence on safety and effectiveness of ultrasound in diagnosing fractures when compared to the conventional imaging modalities such as X-rays. This shall promote further large-scale, multi-centre research that can eventually guide clinic practice in diagnosing and managing various bone fractures.

**Keywords:** Comparison, detection of fractures, fracture, radiography, ultrasound

## Introduction

Bone fractures, due to various causes such as stress, occur frequently and account up to 20% injuries in clinics<sup>[1]</sup>. Similarly, ankle trauma amounts to 300 000 new cases every year in the United Kingdom<sup>[2]</sup>. Whilst clinical symptoms such as pain,

immobility, and visible deformity can give cues to diagnosis, imaging modalities such as X-ray (XR) and ultrasound (US) are widely used for detection of various types of fractures. Over time, US has emerged as an effective diagnostic tool for bone fractures, especially in healthcare settings with a relative lack of resources<sup>[3]</sup>. While XRs are most frequently employed for bone

<sup>a</sup>Faculty of Medicine, Central University of Ecuador, Quito, Ecuador, <sup>b</sup>Medicine, Dow University of Health Sciences, Karachi, <sup>c</sup>Department of Nephrology, <sup>d</sup>Department of Psychiatry, Punjab Medical College, Faisalabad Medical University, Faisalabad, Pakistan, <sup>e</sup>Medicine and Surgery, Dhaka Medical College, Dhaka, Bangladesh, <sup>f</sup>University of Debrecen, Faculty of Medicine, Debrecen, Hungary, <sup>g</sup>General Medicine, Altai State Medical University, Barnaul, Russia, <sup>h</sup>Internal Medicine, Chalmeda Anand Rao Institute of Medical Sciences, Telangana, India, <sup>i</sup>School of Medicine, Ross University School of Medicine, Bridgetown, Barbados and <sup>j</sup>Neurology/Osteopathic Neuromuscular Medicine, Larkin Community Hospital, Miami, FL

Sponsorships or competing interests that may be relevant to content are disclosed at the end of this article.

\*Corresponding author. Address: Dhaka Medical College and Hospital, Dhaka, Bangladesh. Tel.: +193 426 311 15. E-mail address: [bikonaghosh.01@gmail.com](mailto:bikonaghosh.01@gmail.com) (B. Ghosh).

Copyright © 2023 The Author(s). Published by Wolters Kluwer Health, Inc. This is an open access article distributed under the terms of the Creative Commons Attribution-Non Commercial-No Derivatives License 4.0 (CCBY-NC-ND), where it is permissible to download and share the work provided it is properly cited. The work cannot be changed in any way or used commercially without permission from the journal.

Annals of Medicine & Surgery (2023) 85:5085–5095

Received 24 November 2022; Accepted 16 August 2023

Published online 5 September 2023

<http://dx.doi.org/10.1097/MS9.0000000000001229>

fractures, they cannot effectively determine certain type of fractures such as scaphoid, and metatarsal fractures and are generally avoided in pregnant women and paediatric patients due to radiation exposure concerns<sup>[3]</sup>. As a noninvasive and radiation-safe modality, US can be applied in wide-ranging conditions. Other possible advantages include portability, inexpensiveness and utility in remote settings. In addition, recent advances such as Fracture Risk Assessment Tool and the calcaneal quantitative ultrasonography (USG) are recent have proven effective for fracture prediction<sup>[4,5]</sup>. Traditionally, US is utilized in the setting of cellulitis and to evaluate other causes of swelling and erythema such as superficial thrombophlebitis and venous thrombosis. It can also be used to guide and percutaneous drainage of focal abscesses<sup>[6]</sup>. US is also beneficial in the exclusion or diagnosis of deep infection of soft tissues including infectious myositis, osteomyelitis, necrotizing fasciitis and soft-tissue abscess<sup>[7]</sup>. In fact, a study describing the effectiveness of combining USG and radiography in detecting nasal fractures revealed high specificity and sensitivity (93% and 84.8%, respectively) while the negative predictive value (NPV) and positive predictive value (PPV) was 88.3% and 90.7%, respectively<sup>[8]</sup>.

Champagne *et al.*<sup>[3]</sup> reported similarly findings with values such as 93% sensitivity and 92% specificity for upper limb fractures and 82% sensitivity and 93% specificity for lower limb fractures in adults. Despite the promising results, operator availability and experience are major limiting factor to US utility. Another aspect is a scarcity of data on its applications, accuracy, and patient outcomes when compared to other conventional modalities such as XR. Larger sample size, specifying utility in different anatomical regions, and stratifying for operator expertise, lack of comparison with other popular tools such as XR are significant factors that if considered in future research can provide valuable evidence of the effectiveness of US as well as guide technical improvements. This review aims to investigate the effectiveness of the US compared to XR in diagnosing bone fractures, and determine its utility beyond its role as a screening tool.

## Methodology

### Research aim

The researcher applied the “PICO, Supplemental Digital Content 3, <http://links.lww.com/MS9/A242>” 8 models: Population as patients with a fracture; Interventions as US imaging for fracture diagnosis; Comparisons as radiography findings for fracture diagnosis; Results of US imaging findings for successful fracture diagnosis.

### Search strategy

A broad search strategy was used to ensure that all relevant articles were recorded. The search filter was used for MEDLINE, Scopus, and Web of Science databases with the time filter from 2017 to 2022. The combinations of search terms for the study were descriptors in health sciences (MESH), words in the text, and synonyms of the search terms, Supplemental Digital Content 4, <http://links.lww.com/MS9/A243>. These were combined in a manner relevant to the study. All references were extracted and duplicates were removed by hand. All searches were performed and analyzed according to the Preferred Reporting Items for

## HIGHLIGHTS

- Ultrasound is radiation-safe, effective imaging tool to diagnose bone fractures. Despite its advantages, there is a prevalent scarcity of literature recognizing its significance in bone trauma management.
- However, other diagnostic modalities most notably ultrasound have emerged as a simple, radiation-safe, effective imaging tool to diagnose bone fractures.
- Despite the advantages, there is a prevalent scarcity of literature recognizing its significance in bone trauma management.
- This systematic review investigates the effectiveness of ultrasound in the diagnosis of various bone fractures when compared to conventional radiography such as X-rays.

Systematic Reviews and Meta-Analysis (PRISMA) methodology (Fig. 1) and were conducted during August 2022<sup>[9]</sup>.

### Selection criteria

Table 1 shows the inclusion and exclusion criteria used for study selection. The types of studies to be considered include observational studies (case-control, cohort, and cross-sectional) and review articles. Original articles with abstracts available in English were included. Studies outside the study period, case reports, case series, letters to the editor, studies in children under 18 years of age, animal studies, and articles without full text available were excluded.

Two independent investigators (J.E., H.K.) performed the selection of studies in the different databases, based on previously defined search strategies and eligibility criteria. In the first instance, the investigators reviewed all references focusing on the abstract, only articles related to fracture diagnosis by imaging method were retained. The two investigators met to compare the number of references they selected. For any disagreement between the two investigators regarding the inclusion and/or exclusion of any article, a third investigator (B.G.) was consulted to resolve the discrepancy by mutual consensus ((Tables 2 - 4)).

### Data extraction and management

A data extraction form based on the Cochrane Consumers and Communication Review group's extraction template for quality assessment and evidence synthesis was used for data extraction. The information extracted in the data list included: authors, database, journal, date of publication, the place where the study was conducted, type of article, DOI, original title, full article abstracts, the methodology that was applied, and results. Two reviewers (R.C., N.R.) independently extracted data, discrepancies were identified and resolved by discussion with the third author (J.E.) when necessary.

### Analysis and synthesis of data

A narrative synthesis of the studies included in the study will be presented, the information will be classified into long bones, short bones, pneumatic bones, irregular bones, ankle and knee, stress fractures, hip fractures, and Point of Care Ultrasound (POCUS). Studies containing information other than the groups presented will be described in the OTHER category.

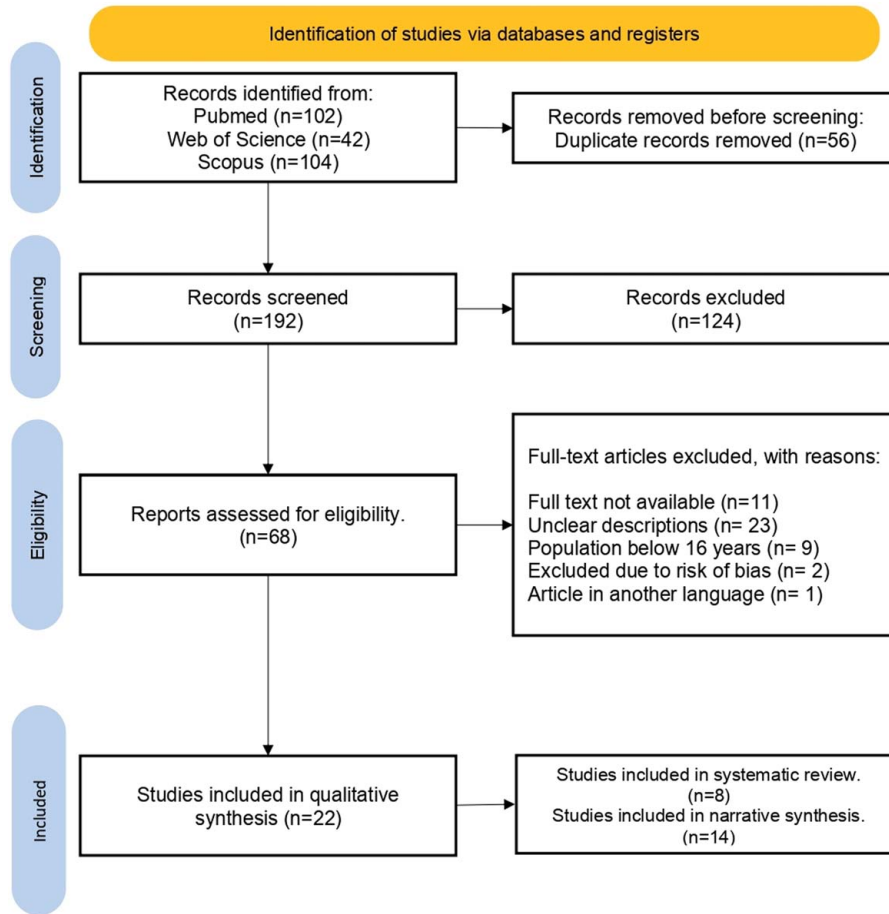


Figure 1. Schematic diagram of study selection.

**Quality assessment**

Two authors (J.E., M.A.) used The Strengthening the Reporting of Observational Studies in Epidemiology (STROBE) Statement: guidelines for reporting observational studies to assess the quality of most studies. The STROBE checklist was used for all observational studies, and systematic reviews and meta-analyses were assessed using the PRISMA guideline, Supplemental Digital Content 1, <http://links.lww.com/MS9/A240> and narrative reviews with the ENTREQ

guideline. All included studies considered bias and ethical criteria and provided valuable evidence to answer the research question.

**Evaluation of the study**

For this study a checklist will be made where the percentage of quality of the review presented will be qualified through the Preferred Reporting Items for Systematic Reviews and Meta-Analysis, likewise, the evidence used will be chosen based on two parameters; more than 70% of qualification through the use of the STROBE, PRISMA, Supplemental Digital Content 1, <http://links.lww.com/MS9/A240>, ENTREQ guides, and a certainty of evidence according to the GRADE guide between High and moderate.

**Results**

The search returned a total of 248 articles, with 192 articles remaining after the removal of duplicates. Primary screening of the title and abstract articles from the database search and additional sources identified 68 relevant articles for full-text screening. This systematic review ultimately used data from 33 articles, of the remaining articles we included all of them because they had more than 70% certainty, using the STROBE tool for observational articles, narrative reviews with the ENTREQ

**Table 1**  
Inclusion and exclusion criteria for study selection.

	Included	Excluded
Population	(A) Patients with fractures above 18 years or more	(A) Animal studies (B) Full text unavailable (C) Studies published in a language other than english (D) Inadequate or unclear descriptions
Intervention	Fractures diagnosed with ultrasound	
Comparators	Fractures diagnosed with radiographs	
Study design	Systematic reviews, meta-analysis, narrative reviews, observational studies	Case series, case reports, editorials, letter to the editor, commentary

Downloaded from <http://journals.lww.com/annals-of-medicine-and-surgery> by BihMifepHkav1Zecum1QIN4e+KJLHEZgbsIHodXM0hCwCX1AWnyQPjIQHrID3i3D00dRy7TVSF14C13VC1y0abggQZXd9Gj2MwZLeI= on 05/31/2024

**Table 2**  
**Characteristics of the studies included in the systematic review.**

Author	Year	Study type	Country	Age (Mean ± SD)	Size	Female (%)
Caglar <i>et al.</i> <sup>a</sup>	2017	Prospective	Turkey	ND	103	46.6
Pishbin <i>et al.</i> <sup>[17]</sup>	2017	Cross-sectional	Iran	44.3 ± 19.7 years	61	29.5
Ebrahimi <i>et al.</i> <sup>[12]</sup>	<sup>15</sup> 2019	Cross-sectional	Iran	35.1 ± 14.3 years	102	43.2
Mohammadifard <i>et al.</i> <sup>[18]</sup>	2019	Prospective	Iran	31.3 ± 10.1 years	331	31.1
Ozturk <i>et al.</i> <sup>[24]</sup>	2018	Prospective	Turkey	40.8 ± 19.3 years	120	52.5
Oguz <i>et al.</i> <sup>[21]</sup>	2017	Prospective	Turkey	46.3 ± 18.4 years	122	30.0
Crombach <i>et al.</i> <sup>[31]b</sup>	2020	Prospective	Netherlands	ND	180	61.0
Avci <i>et al.</i> <sup>[33]</sup>	2019	Cross-sectional	Turkey	33 ± 22 years	205	52.0

<sup>a</sup>Study population was ≥ 16 years.

<sup>b</sup>Study population was ≥ 17 years.

ND, non-describe.

guide, and systematic reviews and meta-analyses with the PRISMA guide, Supplemental Digital Content 1, <http://links.lww.com/MS9/A240>; however, 2 articles were excluded at the eligibility stage because of risk of bias.

### Diagnosis of fractures

There were two studies that discussed the use of USG in fracture diagnosis. In a review article, Nicholson and colleagues concluded unequivocally that USG has experienced a significant increase in use in musculoskeletal medicine during the past 20 years. Moreover, USG might one day replace radiography as a viable approach for diagnosing common paediatric fractures, detecting hidden damage in adults, and quickly discovering long bone fractures during resuscitation. With the improvement of three-dimensional image processing, USG has also shown its usefulness in the early identification of poor fracture healing, indicating that its usage may become more common. To help in the identification of implant-related illnesses, US may be utilized to sonicate microbiological samples. The use of therapeutic USG to facilitate union in the treatment of acute fractures is becoming contentious. Significant *in vitro* investigation reveals that USG has clinical value with potential therapeutic use in established nonunion, emphasizing the necessity for more research<sup>[10]</sup>.

Meanwhile, in the study of Schmid and colleagues, which was a cross-sectional study, a group of general practitioners in Germany completed a self-designed questionnaire on the usefulness of USG in detecting bone fractures. The majority of responders (71.9%,

$n = 192/267$ ) stated that the US was less successful than traditional XRs in diagnosing bone injuries. Despite the fact that 39.3% ( $n = 110/280$ ) of clinicians were aware of this imaging technology, only 19.1% ( $n = 54/283$ ) considered it important to their own practice, and only 7.8% ( $n = 22/282$ ) had any practical e41%) experience using US to detect fractures<sup>[11]</sup>.

### Short bones

In total three studies were found, the detection of short bones with USG can be evidenced in the study of Ebrahimi *et al.*<sup>[12]</sup>, where USG was used in the diagnosis of metatarsal bone fracture in 102 patients where the sensitivity, specificity, PPV, and NPV were 96.7% (CI 95%: 0.83–0.99), 84.5% (95% CI: 0.73–0.92), 73.1% (95% CI: 0.57–0.85), and 98.3% (95% CI: 0.91–0.99), respectively, with an accuracy of 0.906 (95% CI: 0.844–0.969). The use of US has also been seen in the detection of micro lesions that are not seen by XR such as the use of the sesamoid index, the study by Glorioso *et al.*<sup>[13]</sup> in 15 patients with trauma due to hyperextension of the first finger showed US alterations of the sesamoid index above the reference values (18 ± 5.1 mm for the radial sesamoid and 15.7 + 5 mm for the ulnar sesamoid); the abnormal values observed were 35.8 mm for the radial sesamoid and 32 mm for the ulnar sesamoid, with statistical significance ( $P < 0.05$ ).

Detection of occult fractures was reported in the study by Kwee and Kwee, where the sensitivity and specificity of USG in the diagnosis of radiographically occult scaphoid fractures ranged from 77.8 to 100% and 71.4 to 100%, respectively, with pooled

**Table 3**  
**Diagnostic performance of each method.**

Author	Fractures (%)	Location	US (%)				XR (%)			
			SN	SP	PPV	NPV	SN	SP	PPV	NPV
Caglar <i>et al.</i>	41.7	Nasal bones	84.8	93.0	90.7	88.3	91.0	88.0	85.0	93.0
Pishbin <i>et al.</i> <sup>[17]</sup>	54.1	Ribs	98.3	100	100	95.8	40.6	100	100	39.6
Ebrahimi <i>et al.</i> <sup>[12]a</sup>	40.1	Metatarsal bones	96.7	84.5	73.1	98.3	ND	ND	ND	ND
Mohammadifard <i>et al.</i> <sup>[18]</sup>	92.2	Nasal bones	97.7	96.6	97.2	97.3	81.2	86.6	88.0	79.2
Ozturk <i>et al.</i> <sup>[24]</sup>	39.2	Ankle	100	93.0	89.0	100	92.8	100	100	96.2
Oguz <i>et al.</i> <sup>[21]b</sup>	92.1	Wrist	95.3	93.7	98.3	83.3	100	83.3	88.8	100
Crombach <i>et al.</i> <sup>[31]a</sup>	22.0	Ankle and metatarsal bones	80.0	90.3	70.0	94.1	ND	ND	ND	ND
Avci <i>et al.</i> <sup>[33]a</sup>	51.2	Long bones	99.0	93.0	93.0	99.0	ND	ND	ND	ND

<sup>a</sup>Study compares ultrasound and radiography but only reports the diagnostic performance of ultrasound.

<sup>b</sup>Study compares ultrasound and tomography.

ND, non-describe; NPV, negative predictive value; PPV, positive predictive value; SN, sensitivity; SP specificity; US, ultrasound; XR, X-ray.

**Table 4**  
**Characteristics of the studies included in the narrative synthesis.**

Author	Year	Study type	Reports
Bencardino <i>et al.</i> <sup>[1]</sup>	2017	Narrative review	Trabecular stress fractures may go undetected by ultrasound because it cannot assess the subcortical bone. Despite being praised for being quick and inexpensive to execute, it has drawbacks to its operator dependence
Champagne <i>et al.</i> <sup>[3]</sup>	2019	Systematic review and meta-analysis	US presents a reasonable alternative to radiography in the diagnosis of scaphoid and metatarsal stress fractures, and Hill-Sachs lesions. Fractures at these anatomical sites are often radiographically occult at the time of injury, and a more accurate diagnostic test might facilitate the initial screening of patients. While other imaging modalities such as CT and MRI have been shown to accurately diagnose these injuries, these have significant limitations. Therefore, as US shows relatively high SN for these types of fracture across the included trials
Akimoto <i>et al.</i> <sup>[16]</sup>	2020	Prospective	Negative pocket-sized US findings of cortical discontinuity and joint fluid retention in the hip are useful for ruling out femoral proximal fractures and acute hip arthritis. pocket-sized US and XR have comparable diagnostic accuracies, and pocket-sized US could aid in the initial assessment of acute hip pain among the elderly in primary care settings.
Kwee <i>et al.</i> <sup>[14]</sup>	2018	Systematic review	The SN and SP of ultrasound in diagnosing radiographically occult scaphoid fracture ranged from 77.8 to 100% and from 71.4 to 100%, respectively, with pooled estimates of 85.6% (95% CI: 73.9%, 92.6%) and 83.3% (95% CI: 72.0%, 90.6%), respectively.
Hwang <i>et al.</i> <sup>[19]</sup>	2018	Systematic review	The accuracy of US was significantly higher ( $P < 0.001$ ) than that of plain film ( $67.7\% \pm 4.7\%$ ).
Glorioso <i>et al.</i> <sup>[13]</sup>	2022	Cross-sectional	US enabled diagnosis of micro-injuries which were invisible to XR and allowed to detect possible damages to the sesamoid complex, providing a qualitative and quantitative evaluations of the post-traumatic alteration of the metacarpophalangeal joint of the first finger
Wu <i>et al.</i> <sup>[23]</sup>	2021	Systematic review and meta-analysis	The pooled SN, SP, positive likelihood ratio, negative likelihood ratio, and diagnostic odds ratio for the diagnosis of foot and ankle fractures by US were 0.96 (95% CI, 0.90–0.99), 0.94 (95% CI, 0.88–0.97), 15.0 (95% CI, 7.9–28.6), 0.04 (95% CI, 0.02–0.11), and 367 (95% CI, 101–1338), respectively.
De Krom <i>et al.</i> <sup>[25]</sup>	2022	Systematic review and meta-analysis	The present study found SN and SP ranges of 0.20–0.90 and 0.38–0.97 for clinical features, MRI 0.57–0.85 and 0.81–1.00, ultrasonography 1.00 and 0.89–1.00, Malleolar Medial Fleck Sign 0.25 and 0.99, Ankle Mortise X-ray conventional 0.33–0.57 and 0.60–0.94, gravity stress radiography 0.71–1.00 and 0.72–0.88, and manual stress ankle radiography 0.65–1.00 and 0.00–0.77. The largest AUC was found for ultrasound.
Su <i>et al.</i> <sup>[29]</sup>	2018	Prospective	All of the screening strategies, including the universal screening with dual-energy X-ray absorptiometry and the pre-screening with the Fracture Risk Assessment Tool or Quantitative Ultrasonography before dual-energy X-ray absorptiometry, were consistently more cost-effective than no screening for people aged 65 years old or over.
Nicholson <i>et al.</i> <sup>[10]</sup>	2019	Narrative review	Early studies have shown the potential of ultrasound as a valid alternative to XR to detect occult injuries in adults, and for rapid detection of long bone fractures in the resuscitation setting.
Schmid <i>et al.</i> <sup>[11]</sup>	2020	Cross-sectional	On average, General Practitioners diagnosed six patients with suspected fractures per month, yet only 39.3% knew about the possibility of ultrasonographic fracture diagnosis, and only 4.3% of General Practitioners using US applied it for this purpose.
Gottlieb <i>et al.</i> <sup>[30]</sup>	2019	Systematic review and meta-analysis	POCUS was also 97.9% (95% CI 10.5–100%) SN and 99.8% (95% CI 28.0–100%) SP for the diagnosis of associated fractures.
Lalande <i>et al.</i> <sup>[32]</sup>	2017	Cross-sectional	A majority (65%) of emergency physicians concluded that the POCUS technique to diagnose rib fracture was feasible (VAS score > 50). Median score for feasibility was 63. Median score was 31 (Interquartile range 5–57) for patients' pain related to the POCUS
Schaper <i>et al.</i> <sup>[22]</sup>	2021	Systematic review and narrative synthesis	A clear outline of common stress fracture appearances using US were identified in a combined total of 119 participants. Each finding was ranked according to its popularity. Periosteal thickening (78/119) and cortical disruption/irregularity (83/119) were noted in all eight studies. Hypervascularity of the periosteum visualised by colour Doppler imaging (66/119) was reported in six of the eight studies. Soft-tissue hypervascularity (13/119), bony callus formation (5/119) and cortical break (22/119) were seen in three studies.

AUC, area under the curve; CT, computed tomography; POCUS, point of care ultrasound; SN, sensitivity; SP, specificity; US, ultrasound; VAS, Visual Analogue Scale; XR, X-ray.

estimates of 85.6% (95% CI: 73.9%, 92.6%) and 83.3% (95% CI: 72.0%, 90.6%), respectively<sup>[14]</sup>.

### Long bones

In total 4 studies were found, the meta-analysis by Champagne *et al.*<sup>[3]</sup> reported a pooled sensitivity and specificity of 0.93 and 0.92 for upper limb fractures (I<sub>2</sub> = 54.7%; 66.3%) and 0.83 and 0.93 for lower limb fractures (I<sub>2</sub> = 90.1%; 83.5%). In the study by Pishbin and colleagues USG detected 58 (98.3%) rib fractures out of 59 participants, while PA chest radiography showed 24 (40.7%) rib fractures. This same study mentioned an average duration of USG of 12 ± 3 min (range 7–17 min), while the duration of radiography was 27 ± 6 min (range 15–37 min)<sup>[15]</sup>.

Akimoto *et al.*<sup>[16]</sup> reported a sensitivity and specificity for identifying cortical discontinuity in proximal femoral fractures of 0.96 and 0.92, respectively, the sensitivity for identifying cortical discontinuity or joint fluid retention in proximal femoral fractures or acute hip arthritis was 0.97. The use of US during the treatment of distal humerus transphyseal fracture is part of the study by Zhou *et al.*<sup>[17]</sup> where the recorded success rate was 84% (27/32 participants).

### Pneumatic bones

In a study by Caglar and colleagues involving 103 patients, USG was found to have a specificity of 93.0% (95% CI 83.00–98.05%) for detecting the presence of a nasal fracture, sensitivity of 84.8% (95% CI 71.13–93.66%), a NPV of 88.3%

(95% CI 77.43–95%), and a PPV of 90.7% (95% CI 77.86–97.41%)<sup>[18]</sup>.

In a study by Mohammadifard and colleagues, the specificity and sensitivity of USG were 97.66% and 97.79%, respectively, in the assessment of nasal fractures, whereas these two variables were 86.66% and 81.21%, respectively, for radiography. The  $\chi^2$  test revealed that, in terms of identifying nasal fractures, USG was significantly superior to radiography ( $P < 0.001$ ). In conclusion, USG appeared to be a sufficient approach for the detection of nasal fractures and had a greater sensitivity and specificity in identifying them than radiography did<sup>[18]</sup>.

In their study, Hwang and colleagues reported that for the diagnosis of nasal bone fractures, USG was substantially more accurate ( $P < 0.001$ ) than radiography (67.7%  $\pm$  4.7%). In comparison to radiographs, the specificity of USG was significantly greater ( $P < 0.001$ , 67.8%  $\pm$  4.7%). Amongst radiography methods, the combination of Waters view and lateral view (71.8%  $\pm$  4.5%) showed considerably greater accuracy than the Water's view (62.4%  $\pm$  4.8%) or lateral view (61.0%  $\pm$  4.9%) alone. In USG, there was no significant difference in accuracy between dorsal and lateral views (95.8%  $\pm$  2.0%), a dorsal view alone (84.2%  $\pm$  3.6%), or a lateral view alone (84.2%  $\pm$  3.7%)<sup>[19]</sup>.

### Irregular bones

The use of USG in irregular bone fractures was discussed in two studies that met the screening criteria. In a study linking serum sclerostin levels with vertebral fractures, Atteritano and colleagues employed USG to detect fractures. While 10 patients (10%) in the control group had a vertebral fracture, 38 (41%) of the haemodialysis patients had one or multiple vertebral fractures. Subjects with vertebral fractures had significantly higher serum sclerostin values among those receiving haemodialysis (95% CI 10.2–357,  $p = 0.0001$ )<sup>[20]</sup>.

In a different study, 80 patients with wrist injuries were examined to determine the specificity, sensitivity, NPV, and PPV of USG in diagnosing fractures. The study found that the wrist fracture specificity was 93.75% (95% CI: 71.67–98.89) and the wrist fracture sensitivity was 95.31% (95% confidence interval [CI]: 87.1–98.39). Similarly, for the detection of wrist fractures, the NPV was 83.33% (95% CI: 72.98–90.41) and the PPV was 98.39% (95% CI: 91.72–99.85)<sup>[21]</sup>.

### Stress fractures

In a review paper, Bencardino and colleagues observe that periosteal thickness, subcutaneous oedema, local hyperaemia, periosteal callus, and cortical bone irregularity are sonographic findings of stress fractures. Overall, US seems to be more sensitive than specific, and osteomyelitis and neoplasm might both show identical US results. Trabecular stress fractures may also go undetected by US because it cannot assess the subcortical bone. Despite being praised for being quick and inexpensive to execute, it has drawbacks to its operator dependence<sup>[1]</sup>.

Schaper and Madeleine conducted a comprehensive evaluation to determine the most typical images when identifying lower limb stress fractures using ultrasonic imaging. The review involved 119 participants in a total of eight studies. All eight studies noted cortical irregularity (83/119) and periosteal thickening (78/119). Six out of the eight investigations indicated periosteal hypervascularity as seen by colour Doppler (66/119). Three studies revealed bone callus development (5/119), soft-tissue

hypervascularity (13/119), and break in cortex (22/119). The review also concludes that future work on separating stress fractures from pathological involvement might help to lessen the need for plain film radiography<sup>[22]</sup>.

### Ankle and knee

A total of five studies were found, in the systematic review and meta-analyses of Wu and colleagues of which ten papers with a total of 1065 patients were included. The trials examined varied significantly from one another. The combined sensitivity, specificity, positive likelihood ratio, negative likelihood ratio, and diagnostic odds ratio for the diagnosis of foot and ankle fractures in the United States were 0.96 (95% CI, 0.90–0.99), 0.94 (95% CI, 0.88–0.97), 15.0 (95% CI, 7.9–28.6), 0.04 (95% CI, 0.02–0.11), and 367 (95% CI, 101–1338), respectively. The main and radiation-free scanning modality for the diagnosis of foot and ankle fractures should be US due to its outstanding diagnostic performance for injuries of the foot and ankle<sup>[23]</sup>.

There were 120 patients altogether in the study of Oztuek and colleagues where Lateral malleolus fractures were found in 47 patients. In contrast to the US examination, which had a sensitivity of 100% (95% CI, 94.1–100) and a specificity of 93% (95% CI, 85–97.6), the XR had a sensitivity of 92.8% (95% CI, 79.4–98.1) and a specificity of 100% (95% CI, 89.5–100). In three cases, XRs produced false negative results, and in five cases, US produced falsely positive results. Emergency room doctors may more accurately diagnose lateral malleolar fractures in patients who arrive at the ED with lateral malleolus pain with US than they do with XR<sup>[24]</sup>.

A total of 12 studies that looked at methods for diagnosing deltoid ligament rupture in patients with SER-type ankle fractures were examined in a systematic review and meta-analyses by Krom and colleagues. The current study found that conventional ankle mortise radiography had clinical feature sensitivity (and specificity) ranges of 0.33–0.57 (and 0.60–0.94), gravity stress radiography had clinical feature sensitivity (and specificity) ranges of 0.71–1.00 (and 0.72–0.88), and manual stress had clinical feature sensitivity (and specificity) ranges of 0.71–1.00 (and 0.72–0.88). (And 0.00–0.77). (And 0.00–0.77). The greatest area under the curve was found in US, which was followed by MRI, MMFS, and gravity stress radiography. USG and gravity stress radiography seem to be the most effective diagnostic procedures for determining the deltoid ligament's integrity<sup>[25]</sup>.

In a study by Avci & Kozaci, it was found that when it comes to detecting knee bone fractures, XR imaging has low sensitivity. Additionally, it is insufficient to identify the type of fracture and could result in misunderstandings. The sensitivity of XR imaging is drastically decreased when two or three fractures happen at once. Additionally, the kappa value shows a moderate agreement between computed tomography (CT) scanning and XR imaging in the detection of growth plate fractures. Therefore, patients whose fracture type and fracture features cannot be accurately determined by XR imaging in knee injuries should undergo CT scanning. But a more thorough investigation is needed<sup>[26]</sup>.

In the study of Palanisamy and colleagues, a research group consisted of 59 lesions, of which bone lesions made up 77.97% (46/59) and soft-tissue lesions 22.03% (13/59). Cortical thinning/break/fracture, soft-tissue component, neurovascular bundle involvement, cystic component with fluid-fluid level, and joint effusion are all totally detectable by USG. USG is superior to CT

for evaluating the osteochondroma's cartilage cap, whereas USG is equivalent to CT and superior to MRI for identifying calcifications. Despite only 61% of lesions (36/59) showing vascularity, Doppler USG demonstrated 89.5% sensitivity and 80% specificity in discriminating benign and malignant lesions; Doppler, when used in conjunction with grey scale parameters (such as peritumoral oedema, necrosis, absent fat rim, size and heterogeneity of soft-tissue components in bone lesions, invasion of adjacent joints, muscles, neurovascular bundle, and lymph node involvement), was helpful in USG. However, it is less helpful in intraosseous and sclerotic lesions. It is helpful in separating benign from malignant tumours. It is more illuminating than any other approach in cases of recurring cancers and implants that produce artefacts<sup>[27]</sup>.

### Hip fractures

There was a total of two studies that discussed imaging techniques for hip fractures. In a comparative study by Pandey and colleagues, they found that monitored US volumes were effectively matched to the preoperative CT model in all trials using specificity segmentation paired with the suggested NCC registration, as opposed to the other methods. With respect to imaging all three anterior pelvic structures, specificity with NCC had a mean runtime of 27.3 s, a median target registration error (TRE) of 2.44 mm, and a maximum TRE of 4.06 mm. With a median TRE of 3.19 mm and a much shorter time of 4.2 s, specificity segmentation with CPD registration was the second most accurate combination (maximum 6.07 mm)<sup>[28]</sup>.

In another study by Su and colleagues, they concluded that screening techniques, including universal DXA screening and pre-screening with Fracture Risk Assessment Tool or quantitative USG prior to DXA, were consistently more economical than no screening for patients 65 years of age and older. DXA-based osteoporosis screening methods with or without pre-screening are more cost-effective than not screening for Chinese people in Hong Kong who are 65 and older<sup>[29]</sup>.

### Point of Care Ultrasound

A total of four studies were found on POCUS. The inclusion criteria of the study by Gottlieb and colleagues, were satisfied by seven studies, producing a total of 739 evaluations and 306 dislocations. With an LR+ of 796.2 (95% CI 8.0–79 086.0) and an LR- of 0.01 (95% CI 0–0.17), POCUS was 99.1% (95% CI 84.9–100%) sensitive and 99.9% (95% CI 88.9–100%) specific for the diagnosis of shoulder dislocation. The variations in methods weren't statistically significant. Additionally, POCUS was 99.8% specific (28.0–100%) and 97.9% sensitive (95% CI 10.5–100%) for detecting related fractures. POCUS is a great technique for identifying concurrent fractures, shoulder dislocations, and reductions. POCUS may be employed as an alternative diagnostic method for the management of shoulder dislocations<sup>[30]</sup>.

In the research of Crombach and colleagues, there were 242 participants in all, and radiographs of 35 (22% of them) revealed clinically significant (non-avulsion) fractures. PoCUS had a sensitivity of 80.0% (95% CI 63.0–91.6%), a specificity of 90.3% (95% CI 83.7–94.9%), a PPV of 70.0% (95% CI 57.0–80.3%), and a NPV of 94.1% (95% CI 89.1–96.9%) for identifying clinically severe fractures. Expert sensitivity was 82.8% (95% CI 66.3–93.4%), specificity was 99.2% (95% CI 95.5–99.9%), PPV was 96.7% (95% CI 80.3–99.5%), and NPV was 95.3% (95%

CI 91.0–98.2%). In comparison to radiographic imaging, PoCUS in conjunction with the OAR offers a fair level of diagnostic value in the identification of suspected ankle and fifth metatarsal bone fractures. Pocus' diagnostic usefulness will increase with further use<sup>[31]</sup>.

In all, 96 patients were seen in the study by Lalande and colleagues. The majority of EPs (65%) believed the PoCUS method of rib fracture detection was practicable (VAS score > 50). The feasibility score ranged from 0 to 63. The median score for patients' pains as measured by the PoCUS was 31. (5–57, IQR). Pain during patient assessment was the PoCUS technique's most important (15%) flaw. In the emergency room, PoCUS examination seems to be a reliable method for rib fracture diagnosis<sup>[32]</sup>.

A total of 205 participants with suspected LB fractures were included in the research by Avciand colleagues, Kozaci and colleagues. Both the 99 patients with XR and the 105 patients with POCUS had LB fractures. POCUS's sensitivity, specificity, PPV, and NPV for identifying fractures were all higher than those of XR in comparison: 99%, 93%, 93%, and 99%, respectively. When compared to XR, POCUS was able to identify 100% of fissure type fractures, 83% of linear fractures, 92% of fragmented fractures, 67% of spiral fractures, 75% of avulsion type fractures, and 100% of complete separation type fractures (kappa () value: 0.765). This research demonstrated that POCUS has good sensitivity for LB fracture detection. When it comes to determining fracture features, POCUS has high sensitivity. For the diagnosis of LB fractures and the determination of fracture features, POCUS may be employed in addition to XR<sup>[33]</sup>.

### Others

Nine individuals were found to have significant fractures out of the 100 patients enrolled, while 42 patients had mild avulsion fractures. Seven patients with USG and 19 individuals with CT had severe fractures that radiography had missed. There were no US false positives since all fractures that were discovered by USG were later verified by CT. The number of minor avulsion fractures was 40 by US evaluation and 43 by CT inspection. Four small avulsion fractures seen by USG were not verified by CT<sup>[2]</sup>.

For deep deltoid ligament injuries, USG has a specificity and sensitivity of 94.74% and 66.67%, respectively. Specificity and sensitivity for complete tears of the ligament were both 100%. The study also concludes that USG is significantly more accurate than radiography for detection of deltoid ligament injury<sup>[34]</sup>.

Soliman *et al.*<sup>[35]</sup> in their study describing sonographic and radiological findings of posterior tendon dysfunction report that the diagnosis of posterior tibial tendon dysfunction including its postoperative alterations via these methods can guide early detection and treatment, avoiding the need for more invasive and difficult operations.

In research by Oc and colleagues comparing USG and radiography for the identification of dorsal screw penetration following the placement of a volar locking plate, penetration was found in 12 of the 47 patients undergoing the procedure. Three out of five patients had dorsal screw penetration that was undetectable on four-plane radiography, although were shown to have less than 2 mm of penetration by USG. The research advises using perioperative USG to assess dorsal cortical screw penetration<sup>[36]</sup>.

In research by Klos and colleagues, 87/138 (63%) of all the studied knees identified on USG had an anterior cruciate ligament

injury. Dynamic USG evaluation of 87 patients revealed that 44 (51%) had a partial ACL tear and that 43/87 (49%) had a total ACL rupture. In 25/87 (29%) reported instances with an ACL injury, a Segond fracture (typically 6-9 mm) was noted<sup>[37]</sup>.

In a study enrolling 65 patients, Michael and Lindsay utilize point of care USG for detecting dislocations. POCUS had 100% (95% CI, 87–100%) specificity and 100% (95% CI, 87–100%) sensitivity for detecting dislocations, respectively. USG was 100% specific (95% CI, 92–100%) and 92% sensitive (95% CI, 60–99.6%) for detecting non-Hill-Sachs/fractures of Bankart's of the humerus. When identifying dislocations, USG was quicker than traditional radiography from triage (median difference 43 min; interquartile range 23–60 min)<sup>[38]</sup>.

## Discussion

For many decades, XR has remained as the most accepted diagnostic modality for bone fractures. Over time, other imaging studies such as US have proven to be quite effective in detecting fractures and other bone lesions, especially in cases where XR was found to be inconclusive. In fact, US has emerged as an effective tool for diagnosing different types of fractures in all age groups. However, the role of US has been largely underestimated despite its utility as a promising and cost-effective imaging study. A study revealed only 39.3% of clinical practitioners in Germany were aware of the applications of US in fracture diagnosis and 71.9% believed US to be less efficient than XR. However, users of US were found to be well informed<sup>[11]</sup>.

Another study on assessing the efficacy of US in fracture management found promising role of US in detection of impaired fracture healing in early stages which can redirect further management plan. US has also enabled rapid fracture detection in resuscitative setting, as well as aided in diagnosis of common paediatric fractures and occult injuries in adults<sup>[10]</sup>. Considering short bone fracture diagnosis, Robert and colleagues in their study demonstrated high sensitivity (77.8–100%) and specificity (71.4–100%) in detecting radiographically occult scaphoid fracture. US is also viewed as a cost-effective tool when compared to empiric cast immobilization due to lower costs with higher sensitivity<sup>[14]</sup>.

Micro-injuries and possible sesamoid complex injuries could also be detected by US where XRs remained inconclusive. This can enable more efficient evaluation of sesamoiditis by qualitative detection of post-traumatic alteration of metacarpophalangeal joint of the first finger<sup>[13]</sup>. In fact, a cross-sectional study by Ebrahimi *et al.*<sup>[12]</sup> concluded that US is an effective tool in metatarsal bone fracture diagnosis owing to its high sensitivity, specificity and excellent diagnostic accuracy of 96.7%, 84.5%, and 0.906, respectively.

When compared to conventional radiography, a study on 61 patients with rib fracture has shown US to detect more fractures than routine radiographs. In addition, US required considerably less reduction in the management of displaced transphyseal fracture of the distal humerus demonstrated, an effective radiation wise safe method with simple utilization. Other applications include percutaneous pinning fixation with satisfactory clinical and radiographic outcomes and low incidence of cubitus varus<sup>[17]</sup>. Similarly in detection of upper and lower limb bone fractures, US established qualitative diagnostic

accuracy, mainly in fractures of foot and ankle which is also supported by pooled analysis of upper and lower subgroups<sup>[3]</sup>.

Role of US in long bone fracture is further supported by another study on initial assessment of femoral proximal fracture and acute hip arthritis. Ruling out based on cortical discontinuity and joint fluid retention were facilitated by negative findings on pocket-sized US. Furthermore, it is useful for primary evaluation of acute hip pain in elderly<sup>[16]</sup>.

Similarly, US also proven its efficacy in pneumatic bone injury diagnosis. One hundred three patients with nasal bone fracture evaluated by US revealed high specificity and sensitivity compared to routine radiography<sup>[8]</sup>. This finding is further supported by another study which concluded on a superior role of US in detection of nasal bone fracture compared to routine radiograph due to its relatively better diagnostic ability and no radiation requirement<sup>[39]</sup>. Similar findings were reported by Mohammadifard *et al.*<sup>[18]</sup> where US had revealed superior sensitivity and specificity than radiograph in nasal fracture detection among 331 patients. Hwang *et al.*<sup>[19]</sup> also proved US having higher sensitivity (87.2%), specificity (87.4%), and diagnostic accuracy (85%) than plain film in nasal bone fracture detection.

In case of wrist injuries, Ahmet and colleagues in an investigation conducted on 80 patients with wrist injury showed US to have higher sensitivity (95.3%) and specificity (93.75%) in detection of distal forearm and carpal bone fractures. However, studies have not yet shown superiority of US in soft-tissue injury diagnosis<sup>[21]</sup>.

In stress fractures, US have demonstrated more sensitivity than specificity except in trabecular stress fracture where it cannot evaluate subcortical bone<sup>[1]</sup>. US findings can also reveal different stress fractures findings along the lower limb which are otherwise invisible in plain radiographs but this requires further evaluation performed using larger multi-centre investigations on stress fractures diagnosis<sup>[22]</sup>.

US has proven to be an excellent diagnostic tool in ankle and foot fractures due to its higher sensitivity (96%) and specificity (94%) that further promotes it's to be the primary, radiation-free imaging modality<sup>[23]</sup>. Another study revealed higher sensitivity but lower specificity of US than plain XR in lateral malleolar fracture detection<sup>[24]</sup>. In evaluation of soft-tissue injury, particularly deltoid ligament rupture in ankle fracture, US along with gravity stress radiography proved to be the most accurate diagnostic tool with highest sensitivity<sup>[25]</sup>. US has also been established as a diagnostic tool for all soft-tissue tumours including differentiating between benign and malignant along with evaluating local invasion<sup>[27]</sup>. While routine radiographs miss significant fractures of foot and ankle, US could provide for a useful supplemental imaging technique. Yet, cone beam CT has found to be most effective diagnostic tool in this regard. US is still more useful in ligamentous injury detection<sup>[2]</sup>. For hip fractures, US is yielded as a better imaging modality for bone imaging compared to XRs<sup>[28]</sup>.

Moreover, POCUS had shown 99.1% sensitivity and 99.9% specificity in detecting shoulder dislocation and reduction whereas 97.9% sensitivity and 99.8% specificity for associated fracture detection<sup>[30]</sup>. Similar findings were revealed in another study along with ability of US to detect humerus fractures more accurately and effectively reduce diagnostic time during triage compared to XRs<sup>[38]</sup>. Furthermore, POCUS can be combined with the Ottawa Ankle Rule which are considered as efficient diagnostic tool for assessing ankle and fifth metatarsal bone

fractures among 242 patients compared to the plain radiograph<sup>[31]</sup>. A study evaluating role of POCUS in rib fracture detection among patient with minor thoracic trauma in emergency department revealed higher feasibility along with pain being the primary limiting aspect<sup>[32]</sup>. POCUS is not only emerging as a promising diagnostic tool in long bone fractures, but also in evaluation of wide variety of fracture characteristics. POCUS has been found to effectively detect 100% fissure fracture, 83% linear fractures, 67% spiral fractures, 75% avulsion fractures and 100% full separation type fractures along with high sensitivity and specificity compared to plain XRs<sup>[33]</sup>.

Generally, US has shown to superior diagnostic value in detecting isolated lateral malleolar fractures owing to its high sensitivity and specificity compared to that of conventional radiographs<sup>[34]</sup>. US has also been proposed to combined with perioperative lateral radiography in detection of complications after distal radius fractures, particularly in revealing dorsal cortex screw penetration and soft-tissue problems<sup>[36]</sup>. Another study found US to be more effective in detecting second avulsions compared to MRI or radiography<sup>[37]</sup>.

Our review study found that US is similar to radiography in terms of identifying fractures, demonstrating diagnostic accuracy comparable to traditional XR imaging. The non-ionizing nature of US was a notable advantage, as it reduces the detrimental effects of ionizing radiation exposure, making it a safer choice for fracture diagnosis, especially in vulnerable populations such as paediatric patients and pregnant women. However, it is crucial to recognize that the United States has limitations in its ability to provide thorough imaging of bone segments and fragments, which is required for correct fracture categorization. Complex fractures may not be properly examined with US alone because they need precise categorization for appropriate treatment planning. As a result, in orthopaedic and traumatology practice, a mix of imaging modalities, such as XRs or CT scans, is required to offer a complete fracture evaluation. Furthermore, the ability of orthopaedic and traumatology doctors to interpret US images may vary. This exemplifies the potential challenges associated with incorporating US into routine clinical practice, since a lack of understanding may lead to reliance on radiologists' opinions and introduce subjectivity into the diagnosing process. To maximize the benefit of US in fracture diagnosis, concentrated efforts are needed to increase clinician education and training. Improving their ability to interpret US images and recognizing the limitations of US in fracture diagnosis would reduce their reliance on other opinions and increase doctors' confidence in using US for accurate fracture assessments. Finally, our findings imply that US may be a useful diagnostic tool for diagnosing fractures, with sensitivity and specificity comparable to XR imaging. The non-ionizing property of US makes it a safer alternative when radiation exposure must be limited. However, its inability to provide particular anatomical information for difficult fractures necessitates the use of other imaging modalities such as XRs or CT scans for comprehensive fracture evaluation. Clinicians should exercise caution and be aware of the potential limits of US when using it as the only diagnostic tool for fractures. Ongoing research and technological advancements may alleviate some of these limits, perhaps expanding the scope of the US in the future. Recognizing the particular strengths and limitations of the US in fracture diagnosis allows healthcare practitioners to make informed decisions and give the best patient care. The results of this study contribute to the ongoing debate over fracture diagnosis

techniques and lay the groundwork for future research to enhance the usefulness of US in orthopaedic and traumatology practice.

Overall, the significance of US in diagnosing wide-range of bone fractures and anatomical conditions, with considerably high specificity and sensitivity, has enabled its utility as a safe yet efficient diagnostic tool. Further multi-centre cohort studies, can provide a larger body of evidence supporting its application as well as utility when compared to conventional radiography. With increased operator training, US with its simple, less expensive equipment can be readily available at various parts of the world and augment early and accurate fracture diagnosis to guide further management and improve orthopaedic care.

### Limitations

While the study has its strengths, it is not free from limitations. The data collected for this study were secondary and recruited by selected investigators. Moreover, there is limited evidence on the accuracy and patient outcomes when using US to diagnose fractures as compared to XRs. Lack of time, staff, and funding to translate works written in other languages entailed that the search was restricted to papers solely available in English. This may have reduced the generalizability of this review. Additionally, observational studies made up the majority of the research papers that were included in this evaluation. The number of articles included in this review article as well as the exclusion criteria which includes animal studies, paediatric cases, case series, case reports, and investigational studies could all serve as a limitation to this review.

### Conclusion

This systematic review shows that US has become a useful technique for identifying various bone fractures. It also provides its benefits which includes affordability, portability, access to remote areas, limited radiation exposure and non-invasiveness. However, while the use of an US may have its benefits, it also has its limitations which includes limited access to data demonstrating accuracy and patient outcomes as compared to radiographs. After a meticulous selection criterion, 36 of the 248 articles selected were included with 2 articles excluded due to risk of bias. This review paper has demonstrated that US offers great reliability, specificity, and sensitivity for diagnosing short bone, long bone, nasal, vertebral, hip, knee, and ankle fractures. Additionally, the use of POCUS has been proven to be a great technique in identifying shoulder dislocations and reductions with a 97.9% sensitivity and 99.8% specificity. Despite its value as a prospective and economical imaging investigation, the utility of US has been significantly underestimated, especially in the setting of POCUS.

### Ethical approval

Ethical approval was not required for this study.

### Consent

Consent was not required for this study.

## Sources of funding

Authors have no funding to declare.

## Author contribution

J.Q. and J.E.M. conceptualized the topic, coordinated reading, writing and editing. All authors contributed to various aspects of reading, data collection and synthesis, analysis, writing, editing the original draft and critical revision and implementing changes for critical revision under the supervision of J.Q., J.E.M.

## Conflicts of interest disclosure

Authors have no conflicts of interest to declare.

## Research registration unique identifying number (UIN)

1. Name of the registry: PROSPERO
2. Unique Identifying number or registration ID: CRD4 2023409258.
3. Hyperlink to your specific registration (must be publicly accessible and will be checked): [https://www.crd.york.ac.uk/prospero/display\\_record.php?ID=CRD420\\_23409258](https://www.crd.york.ac.uk/prospero/display_record.php?ID=CRD420_23409258)

## Guarantor

Bikona Ghosh.

## Data availability statement

No data are available.

## Provenance and peer review

Not commissioned, externally peer-reviewed.

## Acknowledgements

The authors thank Katherine Simbaña-Rivera.

## References

- [1] Expert Panel on Musculoskeletal Imaging: Bencardino JT, Stone TJ, *et al.* ACR Appropriateness Criteria® Stress (Fatigue/Insufficiency) Fracture, Including Sacrum, Excluding Other Vertebrae. *J Am Coll Radiol* 2017;14(5S):S293–306.
- [2] Allen GM, Wilson DJ, Bullock SA, *et al.* Extremity CT and ultrasound in the assessment of ankle injuries: occult fractures and ligament injuries. *Br J Radiol* 2020;93:20180989.
- [3] Champagne N, Eadie L, Regan L, *et al.* The effectiveness of ultrasound in the detection of fractures in adults with suspected upper or lower limb injury: a systematic review and subgroup meta-analysis. *BMC Emerg Med* 2019;19:17.
- [4] McCloskey EV, Kanis JA, Odén A, *et al.* Predictive ability of heel quantitative ultrasound for incident fractures: an individual-level meta-analysis. *Osteoporos Int* 2015;26:1979–87.
- [5] Kanis JA, Hans D, Cooper C, *et al.* Interpretation and use of FRAX in clinical practice. *Osteoporos Int* 2011;22:2395–411.
- [6] Tayal VS, Hasan N, Norton HJ, *et al.* The effect of soft-tissue ultrasound on the management of cellulitis in the emergency department. *Acad Emerg Med* 2006;13:384–8.
- [7] Chao HC, Lin SJ, Huang YC, *et al.* Sonographic evaluation of cellulitis in children. *J Ultrasound Med* 2000;19:743–9.
- [8] Ashley H, Tina O, John SM, Musculoskeletal system, Small Animal Diagnostic Ultrasound,(544-565), 2021. doi:10.1016/B978-0-323-53337-9.00023-X.
- [9] Page MJ, McKenzie JE, Bossuyt PM, *et al.* The PRISMA 2020 statement: an updated guideline for reporting systematic reviews. *Int J Surg* 2021;88:105906.
- [10] Nicholson JA, Tsang STJ, MacGillivray TJ, *et al.* What is the role of ultrasound in fracture management?: diagnosis and therapeutic potential for fractures, delayed unions, and fracture-related infection. *Bone Joint Res* 2019;8:304–12. Published 2019 Aug 2.
- [11] Schmid GL, Kühnast B, Heise M, *et al.* Ultrasonography in assessing suspected bone fractures: a cross-sectional survey amongst German general practitioners. *BMC Fam Pract* 2020;21:9. Published 2020 Jan 13.
- [12] Ebrahimi M, Habibzadeh SR, Ahmadi SR, *et al.* Diagnostic accuracy of ultrasonography in diagnosis of metatarsal bone fracture; a cross sectional study. *Arch Acad Emerg Med* 2019;7:e49. Published 2019 Aug 17.
- [13] Glorioso M, Perri S, Lombardo V, *et al.* Ultrasound evaluation of the first finger's sesamoid bones: diagnostic value of sesamoid and subsesamoid indices. *J Ultrasound* 2022;25:67–71.
- [14] Kwee RM, Kwee TC. Ultrasound for diagnosing radiographically occult scaphoid fracture. *Skeletal Radiol* 2018;47:1205–12.
- [15] Pishbin E, Ahmadi K, Foogardi M, *et al.* Comparison of ultrasonography and radiography in diagnosis of rib fractures. *Chin J Traumatol* 2017;20:226–8.
- [16] Akimoto T, Kobayashi T, Maita H, *et al.* Initial assessment of femoral proximal fracture and acute hip arthritis using pocket-sized ultrasound: a prospective observational study in a primary care setting in Japan. *BMC Musculoskelet Disord* 2020;21:291.
- [17] Zhou H, Zhang G, Li M, *et al.* Ultrasonography-guided closed reduction in the treatment of displaced transphyseal fracture of the distal humerus. *J Orthop Surg Res* 2020;15:575. Published 2020 Dec 1.
- [18] Mohammadifard M, Karimi G, Eslamirad A, *et al.* Comparing the Ultrasonography Diagnostic Value with Standard Radiography in Detecting Nasal Fractures. *Int J Ayurved Med* 2019;10:323–5.
- [19] Hwang K, Jung JS, Kim H. Diagnostic performance of plain film, ultrasonography, and computed tomography in nasal bone fractures: a systematic review. *Plast Surg (Oakv)* 2018;26:286–92.
- [20] Atteritano M, Di Mauro E, Canale V, *et al.* Higher serum sclerostin levels and insufficiency of vitamin D are strongly associated with vertebral fractures in hemodialysis patients: a case control study. *Osteoporos Int* 2017;28:577–84.
- [21] Oguz AB, Polat O, Eneyli MG, *et al.* The efficiency of bedside ultrasonography in patients with wrist injury and comparison with other radiological imaging methods: a prospective study. *Am J Emerg Med* 2017;35:855–9.
- [22] Schaper M, Marcus J. Preliminary image findings of lower limb stress fractures to aid ultrasonographic diagnoses: a systematic review and narrative synthesis. *Ultrasound* 2021;29:208–17.
- [23] Wu J, Wang Y, Wang Z. The diagnostic accuracy of ultrasound in the detection of foot and ankle fractures: a systematic review and meta-analysis. *Med Ultrason* 2021;23:203–12.
- [24] Ozturk P, Aksay E, Oray NC, *et al.* Emergency physician accuracy using ultrasonography to diagnose lateral malleolar fracture. *Am J Emerg Med* 2018;36:362–5.
- [25] de Krom MA, Kalmet PH, Jagtenberg EM, *et al.* Diagnostic tools to evaluate ankle instability caused by a deltoid ligament rupture in patients with supination-external rotation ankle fractures: a systematic review and meta-analysis. *Injury* 2022;53:724–31.
- [26] Avci M, Kozaci N. Comparison of X-ray imaging and computed tomography scan in the evaluation of knee trauma. *Medicina (Kaunas)* 2019;55:623. Published 2019 Sep 23.
- [27] Palanisamy P, Patnaik S, Arora A, *et al.* Role of ultrasonography in imaging of tumours around knee joint. *JCDR* 2018;12:TC01–6. Published online 2018. doi:10.7860/JCDR/2018/35566.11633
- [28] Pandey P, Guy P, Hodgson AJ, *et al.* Fast and automatic bone segmentation and registration of 3D ultrasound to CT for the full pelvic anatomy: a comparative study. *Int J Comput Assist Radiol Surg* 2018;13:1515–24.
- [29] Su Y, Lai FTT, Yip BHK, *et al.* Cost-effectiveness of osteoporosis screening strategies for hip fracture prevention in older Chinese people: a decision tree modeling study in the Mr. OS and Ms. OS cohort in Hong Kong. *Osteoporos Int* 2018;29:1793–805.

- [30] Gottlieb M, Holladay D, Peksa GD. Point-of-care ultrasound for the diagnosis of shoulder dislocation: a systematic review and meta-analysis. *Am J Emerg Med* 2019;37:757–61.
- [31] Crombach A, Azizi N, Lameijer H, *et al.* Point-of-care bedside ultrasound examination for the exclusion of clinically significant ankle and fifth metatarsal bone fractures; a single blinded prospective diagnostic cohort study. *J Foot Ankle Res* 2020;13:19. Published 2020 May 7.
- [32] Lalande É, Guimont C, Émond M, *et al.* Feasibility of emergency department point-of-care ultrasound for rib fracture diagnosis in minor thoracic injury. *CJEM* 2017;19:213–9.
- [33] Avci M, Kozaci N, Tulubas G, *et al.* Comparison of point-of-care ultrasonography and radiography in the diagnosis of long-bone fractures. *Medicina (Kaunas)* 2019;55:355. Published 2019 Jul 9.
- [34] Kim HN, Jeong S, Park YU. Value of ultrasound for stability assessment of isolated lateral malleolar fractures compared to stress radiography and arthroscopy. *Clin Orthop Surg* 2020;12:535–41.
- [35] Soliman SB, Spicer PJ, van Holsbeeck MT. Sonographic and radiographic findings of posterior tibial tendon dysfunction: a practical step forward. *Skeletal Radiol* 2019;48:11–27.
- [36] Oc Y, Kilinc BE, Gulcu A, *et al.* Ultrasonography or direct radiography? A comparison of two techniques to detect dorsal screw penetration after volar plate fixation. *J Orthop Surg Res* 2018;13:70.
- [37] Klos B, Scholtes M, Konijnenberg S. High prevalence of all complex Segond avulsion using ultrasound imaging. *Knee Surg Sports Traumatol Arthrosc* 2017;25:1331–8.
- [38] Secko MA, Reardon L, Gottlieb M, *et al.* Musculoskeletal ultrasonography to diagnose dislocated shoulders: a prospective cohort. *Ann Emerg Med* 2020;76:119–28.
- [39] Dogan S, Kalafat UM, Yüksel B, *et al.* Use of radiography and ultrasonography for nasal fracture identification in children under 18 years of age presenting to the ED. *Am J Emerg Med* 2017;35:465–8.