

Clinical experience with an anti-dysphotopic intraocular lens

Zsófia Rupnik, Ágnes Elekes, Péter Vámosi

Access this article online
Quick Response Code:

Website: www.saudijophthalmol.org
DOI: 10.4103/sjopt.sjopt_191_21

Abstract:

PURPOSE: Report experience regarding an anterior capsulotomy fixated intraocular lens (IOL) designed to prevent negative dysphotopsia (ND).

METHODS: A prospective, nonrandomized clinical study was done at Péterfy Sándor Street Hospital-Clinic, and Jenő Manninger National Trauma Institute, Budapest, Hungary. The Morcher (Masket) 90S IOL has a circumferential groove on the optic that captures the anterior capsulotomy. Thus, part of the optic projects over and anterior to the capsule edge, while the bulk of the IOL is fixated within the capsular bag. We implanted the first version of the 90S IOL into the 40 eyes of 38 patients. These 40 eyes made up the primary investigational cohort. An additional 22 eyes received a modified version of the 90S IOL. The main outcome measure was the presence of ND. There was also a control group of 40 patients who received a single-piece monofocal aspheric hydrophobic acrylic IOL (877 FAB, Medicontur, Budapest, Hungary).

RESULTS: None of our 66 test patients experienced ND during the follow-up period. After specific questioning, six patients reported nondebilitating PD that improved or disappeared completely in 5 cases. For the 40 eyes of the control group, there were 10 cases of ND on the first postoperative day and in 2 cases ND persisted for more than 1 year postoperatively.

CONCLUSION: The 90S IOL can be used successfully to prevent ND. Since it is fixated by the anterior capsulotomy, additional advantages such as prevention of anterior capsule contraction, limited tilt, stable toric axis, perfect centration on the visual axis, and a more predictable lens position, among others, may be expected, and are under investigation.

Keywords:

Cataract, intraocular lens, negative dysphotopsia

INTRODUCTION

Pseudophakic dysphotopsia is an unwelcome complication of otherwise uncomplicated phacoemulsification. Negative dysphotopsia (ND) was first reported by Davison in 2000 as a dark shadow in the temporal visual field (VF).^[1] ND is usually described as a temporal arc or crescent similar to wearing horse blinders.^[2] The shadow typically disappears after a few months in most cases; however, some patients have chronic complaints that may be debilitating; secondary surgery may be inevitable in those cases.^[3] The epidemiology of ND has not been widely studied; however, in a prospective investigation of 250 patients, Osher reported a 15% incidence on the first

postoperative day.^[4] However, most likely due to neuroadaptation, in that study, the incidence was reduced to 3% at 1 year, and 2% at 2 years. The incidence of ND is significantly higher when specifically inquired, as reported by Makhotkina, *et al.* who indicated a nearly 20% incidence early after surgery.^[5] Davison and Vámosi *et al.* reported lower incidences in larger series of cases; however, they did not solicit specific patient complaints regarding dysphotopsia.^[1,3] Nevertheless, given the annual cataract volume in the developed world, ND is a meaningful complication that requires attention. On the other hand, Masket, *et al.* first described what is now known as positive dysphotopsia (PD). They reported “undesired light imagery” after truncated edge, ovoid posterior chamber lens implantation.^[6] Patients describe PD as streaks, halos, or glare, that are induced by oblique external light sources.^[1]

This is an open access journal, and articles are distributed under the terms of the Creative Commons Attribution-NonCommercial-ShareAlike 4.0 License, which allows others to remix, tweak, and build upon the work non-commercially, as long as appropriate credit is given and the new creations are licensed under the identical terms.

For reprints contact: WKHLRPMedknow_reprints@wolterskluwer.com

How to cite this article: Rupnik Z, Elekes Á, Vámosi P. Clinical experience with an anti-dysphotopic intraocular lens. Saudi J Ophthalmol 2022;36:183-8.

Péterfy Sándor Street
Hospital-Clinic, Jenő
Manninger National Trauma
Institute, Budapest, Hungary

Address for correspondence:

Dr. Zsófia Rupnik,
Department of Ophthalmology,
Péterfy Sándor Street
Hospital-Clinic, Péterfy
S. u. 8-20, Budapest 1076,
Hungary.
E-mail: zsofia.rupnik@gmail.
com

Submitted: 09-Aug-2021

Revised: 06-Feb-2022

Accepted: 07-Mar-2022

Published: 29-Aug-2022

Although with regard to ND, there are demonstrable far peripheral VF changes on Goldmann kinetic VF testing, there are no specific objective tests to establish the diagnosis; the clinician relies primarily on patient-reported outcomes.^[7,8] The etiology of ND seems to be somewhat obscure as there appears to be a discrepancy between optical laboratory modeling by ray tracing and clinical findings. As an example, initial ray-tracing studies from Holladay, *et al.* implicated square edged, high index of refraction (I/R) PCIOLs as likely causal of ND.^[9] However, in a clinical analysis of patients requiring secondary surgery for chronic ND (persisting beyond 6 months), it was reported that 13% of cases had low I/R, silicone intraocular lens (IOLs) with round edges.^[10] In that report, virtually all types of IOLs on the US market were noted to be associated with ND if they were positioned in the capsule bag with an overlapping anterior capsulorhexis. In that investigation, ND was improved, eliminated, or prevented if the IOL optic was elevated anterior to capsulotomy in “reverse optic capture” with the haptics remaining in the capsule bag, suggesting that the anterior capsulotomy/optic interface may play a role in the etiology of ND.^[10] Additionally, a report from Burke and Benjamin indicated that high I/R, square-edged IOLs could “cure” ND if the lenses were placed in the ciliary sulcus, rather than the capsule bag.^[11] That report, in combination with the Vámosi, *et al.* study suggests that the final common clinical pathway for ND is any “in-the-bag” IOL, and that material or design of the PCIOL is irrelevant.^[3,11] Therefore, in clinical terms, ND may occur if the anterior capsule overlies the optic, but if the optic overlies the capsule, ND will be obviated or ameliorated. This phenomenon has not been well investigated in the optical laboratory setting; however, it is furthered by the observation that by removing the nasal capsule edge with the Nd: YAG laser, ND will be improved in the majority of cases.^[12,13] Additionally, in one case report, the nasal portion of the optic was truncated surgically, successfully eliminating ND and furthering the concept that ND is, in part, dependent on the capsule overlap of the optic, particularly on the nasal side.^[14] Given that both laser capsulotomy and truncating the nasal edge of the optic reduce ND, there is support for the concept that the capsulotomy-optic interface is one source of ND, as suggested by Masket *et al.*^[10]

From the above, it appears that ND is more likely associated with the position of the IOL, rather than the material and design of the IOL optic.^[2,10] In keeping with that concept, the Morcher 90S IOL was designed to simulate reverse optic capture in an attempt to prevent ND while avoiding potential problems of sulcus fixated IOLs.^[15] In the present investigation, we report our surgical and postoperative experiences regarding that device.

METHODS

Morcher (Masket) 90S anti-dysphotopic intraocular lens

The Morcher (Masket) 90S IOL (Morcher GmbH, Stuttgart, Germany; CE marked in Europe) is a hydrophilic acrylic

IOL that has a circumferential groove anterior to the optic equator that captures the anterior continuous curvilinear capsulotomy (ACCC) [Figures 1 and 2]. In this fashion, part of the optic overlies the capsule and the IOL is fixated by the anterior capsulotomy yet the bulk of the IOL sits within the capsule bag. The IOL has fenestrations that are designed to prevent capsule block (capsule-bag hyperdistension) and also serve as fixation holes for manipulation during the implantation process [Figure 2].

The IOLs for this study were supplied by Morcher, and no other source of funding was obtained.

Study design and patients

We performed a prospective, nonrandomized clinical study in which version 1 of the 90S IOL (6.0 mm optic) was implanted in 40 eyes of 38 patients (30 females, 8 males) between July 2016 and April 2017. Patients were selected based on their willingness to participate in the study of an investigational IOL and to return for postoperative checkups. Although the original study design was to only implant one eye of each patient, based on their satisfaction with postoperative outcomes, two patients strongly desired to have the same IOL in the fellow eye.

Patients were informed in detail about the aim of the study and were properly consented. The study was performed in accordance with the Helsinki Declaration, and approval was obtained from the responsible Department of our institution. The 40 eyes made up the primary investigational cohort. Three patients had a history of ND affecting the fellow eye. An additional 22 eyes were subsequently studied in less detail. This group was implanted with version 2 of the 90S IOL in which the anterior leaf of the optic was enlarged to 6.4 mm; no other changes were made to the IOL [Figure 3].

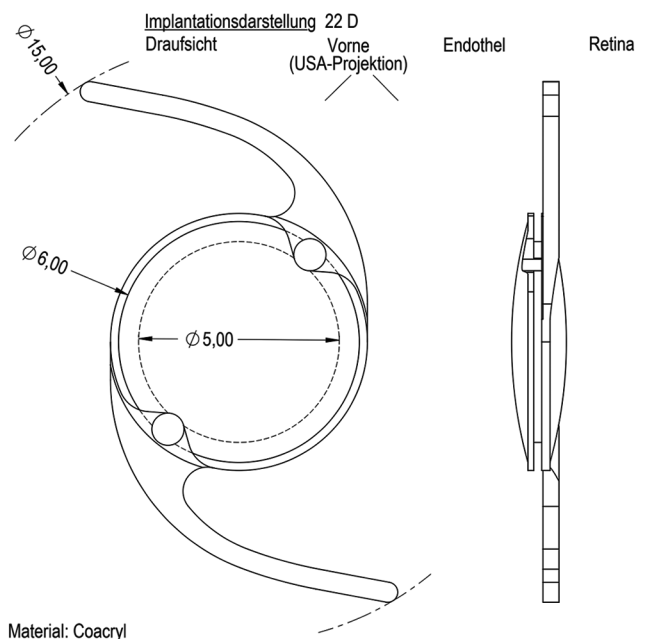


Figure 1: Design of the Morcher (Masket) 90S intraocular lens

Patients were not age or sex matched. The control group consisted of 40 patients (18 females, 22 males, average age 72.2 years) who received a single-piece monofocal aspheric hydrophobic acrylic IOL (877 FAB, Medicontur, Budapest, Hungary).

Exclusion criteria were pupil diameter smaller than 5 mm (after pharmacologic dilation), severe dry eye, cornea guttata, and other corneal pathologies that could reduce visual acuity, prior keratorefractive surgery, pseudoexfoliation syndrome, poorly controlled glaucoma, primary angle closure, posterior segment disorders (macular pathology, diabetic retinopathy, retinal detachment, etc.), and prior intraocular surgery. Preoperative data collected from each patient included age, sex, medical history, and complete ophthalmological examination: uncorrected distance visual acuity (UDVA), corrected distance visual acuity (CDVA), slit-lamp examination, tonometry, and macular optical coherence tomography (OCT) (Heidelberg Spectralis OCT, Heidelberg Engineering GmbH, Germany). Postoperatively, patients were examined by the operating surgeon (PV) and interviewed and examined by another ophthalmologist (ZR) at specific postsurgical appointments (1 day, 1 week, 1 month, 3 months, 6 months). A complete ophthalmological exam (UDVA, CDVA, slit-lamp examination, tonometry) was performed during all of the postoperative appointments. The patients were specifically asked about the presence of PD and ND, and about their satisfaction at every visit employing a novel questionnaire [Table 1]. At month 1, macular OCT was performed. At month 3, mesopic and photopic contrast sensitivity test with added glare (CSV-1000 Contrast Chart, VectorVision, Inc), and low contrast visual acuity was measured. At 6 months, corrected near vision was checked. There were modest deviations from the follow-up schedule due to patient compliance.

UDVA and CDVA were measured using ETDRS charts, and near visual acuity was measured with the Hungarian version of the Radner test (Radner-Coimbra Reading Charts).

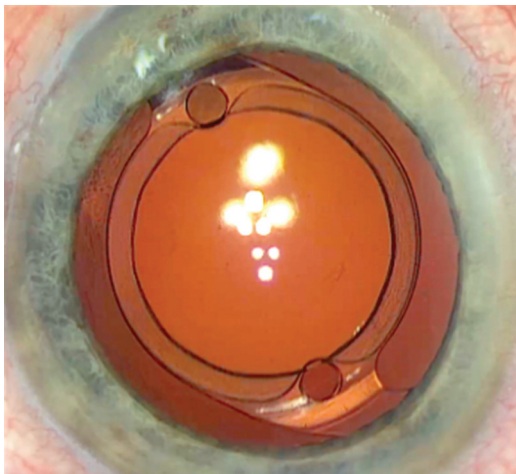


Figure 2: Design of the Morcher (Masket) 90S intraocular lens demonstrating the fenestrations that prevent capsule block

The main outcome measure was the presence of ND; additional outcome measures included the presence of PD, uncorrected (UCVA), and best-corrected (BCVA) visual acuities.

Surgical technique

As this is a new generation of IOLs, the A-constant was unclear in the beginning, and after a few cases, an A-constant of 118.1 was established based on initial postoperative refraction.

All patients underwent standard phacoemulsification under topical or retrobulbar anesthesia by the same surgeon (PV). 2.7 mm near clear corneal incisions were centered on the steep keratometric axis. Sutures were used when appropriate. As the size and position of the anterior curvilinear capsulorhexis (ACCC) are crucial to successful implantation of the capsulotomy supported 90S IOL, the directed ACCC (4.5–5.5 mm) was made after capsular dyeing with 0.06% trypan blue under viscoelastic material using a capsulorhexis forceps. The size of the rhexis was facilitated by silicon ring or caliper marking. The ACCC must be central, symmetric, and fully continuous for best results with a capsulotomy fixated IOL. After completion of phacoemulsification and polishing of the posterior capsule, the IOL was injected into the capsular bag using a Viscoject/Viscoglide 2.4 mm injector (Medicel AG, Switzerland). The viscoelastic material from behind the IOL was removed and the edge of the capsulorhexis was captured in the optic with the help of two Sinsky hooks, employing the fixation holes located at the base of the haptics. The orientation of the haptics varied in each case. At the end of the surgery, each patient was given intracameral acetylcholine and cefazoline. After experiencing two cases with iris-optic capture [Figure 4] among the early cases, patients received topical pilocarpine

Table 1: Patient questionnaire

- 1 - Since surgery have you noted a blockage of vision or shadow off to the side, similar to "horse blinders"?
- 2 - Since surgery have you noted streaks of lights, halos, or light flashes?
- 3 - Would you have the same lens implanted in the other eye?

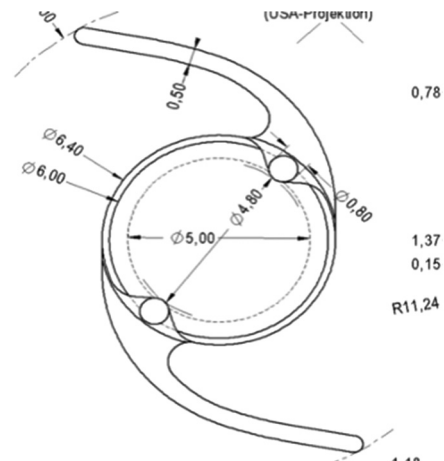


Figure 3: Version 2 of the 90S intraocular lens

2% at the end of the surgery and repeated at 2 h after surgery. Routine postoperative treatment included topical levofloxacin (Oftaquix, Santen Pharmaceutical, Hungary) five times daily for 1 week, and dexamethasone (Maxidex, Alcon Laboratories, Inc., Hungary) five times daily for 3 weeks, then dexamethasone three times daily for an additional 4 weeks.

RESULTS

For the prospective study cohort of 40 eyes of 38 patients, the average age was 70.4 years. One patient was discovered to have Fuchs dystrophy that was missed preoperatively; this case we excluded from visual acuity and contrast sensitivity testing. For the primary cohort, mean UCVA was logMar 0.33 (median: 0.2, standard deviation [SD]: 0.32, $n = 39$) after one day, 0.19 (median: 0.1, SD: 0.29, $n = 38$) after 1 week, 0.09 (median: 0.1 SD: 0.16, $n = 29$) after 1 month, 0.07 (median 0.0, SD: 0.16, $n = 29$) after 3 months, and 0.02 (median: 0.0 SD: 0.18, $n = 23$) after 6 months. Mean BCVA was logMar 0.23 (median: 0.1, SD: 0.27, $n = 39$) after 1 day, 0.01 (median: 0.00 SD: 0.06, $n = 38$) after 1 week, -0.01 (median: 0.00, SD: 0.05, $n = 29$) after 1 month, -0.05 (median: 0.00, SD: 0.07, $n = 29$), and -0.04 (median: 0.00, SD: 0.05, $n = 23$) after 6 months.

The average low contrast visual acuity was logMar 0.28 (SD: 0.11, $n = 31$). The average corrected near vision was logRad 0.51 (median: 0.5, SD: 0.11, $n = 23$) at 25 cm, and 0.36 (median: 0.3, SD: 0.1, $n = 23$) at 40 cm. Photopic, mesopic, and added glare contrast sensitivity curves were consistent with a normal population [Graph 1].^[16]

Employing a simple 3 specific item questionnaire regarding dysphotopsia [Table 1], no patient experienced any ND symptom during the follow-up period at any time after surgery. Six patients reported PD symptoms after 1–8 months, however; all of them mentioned it only after specific questions and none of them found it debilitating. In 5 cases PD either improved or completely disappeared. Two patients developed posterior capsule opacification (PCO) adequate

to require laser capsulotomy during the follow-up period; Nd: YAG capsulotomy was carried out routinely and without complication.

Four patients had iris capture on the first postoperative day and all 4 required re-operation at that time; all were successfully managed. For one additional case, iris capture occurred during the week 1 postoperative visit after pupil dilation; it resolved spontaneously as the pharmacologic dilation reversed over a short time.

Nine cases experienced elevated IOP on the first postoperative day (average IOP: 34.7 mmHg, SD: 4.62). IOP reverted to normal in all cases with oral acetazolamide 250 mg and did not recur in the follow-up period.

An additional 22 patients were implanted with Version 2 of the 90S IOL; however, for this group of patients we were only concerned about the presence or absence of ND and iris-optic capture; neither condition was noted for any eye in this group.

For the 62 eyes of both groups, there were no cases of capsular block syndrome, iris chafing, inflammation, or anterior segment hemorrhage.

For the 40 eyes of the control group, there were 10 cases of ND on the first postoperative day and in 2 cases ND persisted for more than 1 year postoperatively. The purpose of this group was strictly with respect to the primary outcome measure (presence or absence of ND), thus no further data were collected in this group.

DISCUSSION

ND may be a very disturbing complication of otherwise uneventful phacoemulsification and, as mentioned above, attempts to determine the cause has been somewhat hampered by the fact that there is a discrepancy between optical laboratory modeling by ray tracing and clinical investigations. However, from the Masket and Fram, study we recognize that 42 of 43 eyes were improved, cured, or prevented from ND by placing the optic anterior to the anterior capsulotomy in reverse optic capture fashion. Given that the Morcher (Masket) 90S IOL was designed to mimic reverse

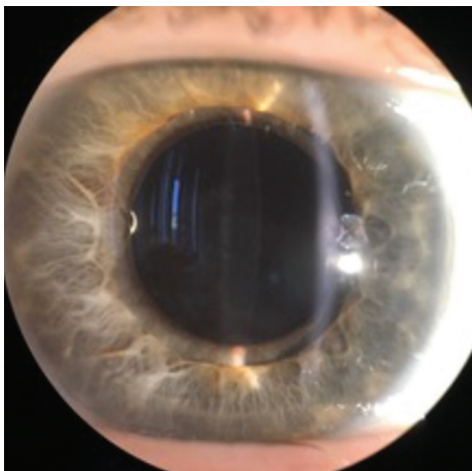
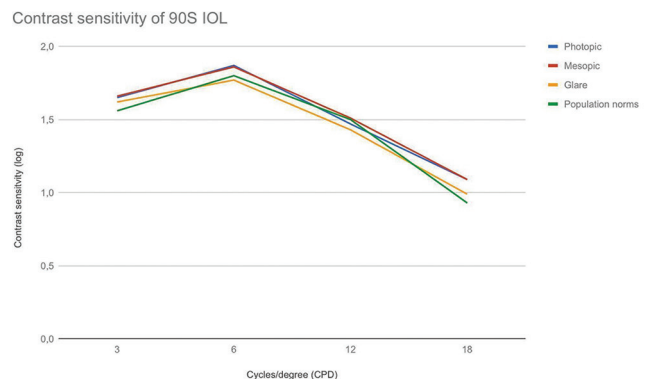


Figure 4: Iris-optic capture



Graph 1: Contrast sensitivity

optic capture, we elected to evaluate its clinical performance in the current study.

The main outcome measure of the study was the presence of ND at any time after surgery. None of the patients in the primary cohort of 40 eyes or the secondary group of 22 eyes experienced ND, under careful questioning at any visit, lending credence to the design concept of the 90 S IOL. Additionally, other IOLs in European use that have capsulotomy fixation of the IOL have not been associated with ND in any patient (personal communications Tassignon, Auffarth), furthering the “proof of concept.” Moreover, anterior capsulotomy optic fixation has potential theoretical advantages in addition to the elimination of ND and are under investigation: They include the absence of capsule contraction, better predictability of effective lens position, improved IOL centration and tilt, stability of toric IOL axis positioning, and reduced induction of higher-order optical aberrations if the capsulotomy is centered on the visual axis. Favorable outcomes with some of these designs have been recently reported.^[17-19]

Size and position of the continuous circular anterior capsulotomy is essential to the use of the 90S IOL and an automated capsulotomy device, such as a femtosecond laser to create a centered 4.8–4.9 mm capsulotomy, is advised by the IOL manufacturer. Nevertheless, a guided capsulotomy can also suffice, employing either an optical system (Callisto, Zeiss) or sizing rings (Morcher) placed on the anterior capsule. Although inserting the capsulorhexis into the groove of the lens was somewhat difficult in the surgeon’s early cases, it was facilitated subsequently with the use of two Sinskey hooks placed in the fixation holes and aided by an ophthalmic viscosurgical device for maintenance of space.

Four patients in the primary 40 eye cohort were noted to have iris-optic capture on the first postoperative day, and the use of intracameral or topical miotics did not prevent this occurrence. Potential causes for iris-optic capture include wound leak with shallowing of the chamber, pupil block, or the fact that the 90S IOL is somewhat thicker than standard single-piece acrylic IOLs. Owing to the problem of iris-optic capture Morcher enlarged the anterior leaf of the optic by 0.4 mms in version 2; that device was placed in the second group of 22 eyes. None of the latter group experienced iris-optic capture. As mentioned above, there were no cases of capsule bock, iris chafing, undue inflammation, or anterior chamber hemorrhage during the follow-up period. With respect to PCO, 2 cases of the study cohort required capsulotomy within the 6 months study period. This is consistent with our experience with other IOLs. Although PD was reported in 6 cases, it improved or disappeared in five cases, and no patient found it debilitating.

CONCLUSION

In summary, ND is an unwelcome complication of uneventful posterior chamber lens implantation. While the etiology

remains under debate, it is extremely hard to predict which patients will be affected, making prevention even harder. Based on the current study, the 90S IOL, as do other anterior capsulotomy fixated IOLs, successfully prevents ND, affording additional” proof of concept” that having optic over capsule precludes ND postoperatively. Moreover, in the present investigation 3 of the study eyes had ND in the previously operated eye, which did not occur in the second eye with the 90S IOL. Given anterior capsulotomy fixation, there are additional potential advantages that are under investigation. We recognize certain shortcomings of the current investigation that include small numbers of cases, we look forward to reports of other clinical investigators regarding this innovative IOL concept.

Financial support and sponsorship

Nil.

Conflicts of interest

There are no conflicts of interest.

REFERENCES

1. Davison JA. Positive and negative dysphotopsia in patients with acrylic intraocular lenses. *J Cataract Refract Surg* 2000;26:1346-55.
2. Masket S, Fram NR. Pseudophakic negative dysphotopsia: Surgical management and new theory of etiology. *J Cataract Refract Surg* 2011;37:1199-207.
3. Vámosi P, Csákány B, Németh J. Intraocular lens exchange in patients with negative dysphotopsia symptoms. *J Cataract Refract Surg* 2010;36:418-24.
4. Osher RH. Negative dysphotopsia: Long-term study and possible explanation for transient symptoms. *J Cataract Refract Surg* 2008;34:1699-707.
5. Makhotkina NY, Nijkamp MD, Berendschot TT, van den Borne B, Nuijts RM. Effect of active evaluation on the detection of negative dysphotopsia after sequential cataract surgery: Discrepancy between incidences of unsolicited and solicited complaints. *Acta Ophthalmol* 2018;96:81-7.
6. Masket S, Geraghty E, Crandall AS, Davison JA, Johnson SH, Koch DD, *et al.* Undesired light images associated with ovoid intraocular lenses. *J Cataract Refract Surg* 1993;19:690-4.
7. Makhotkina NY, Berendschot TT, Nuijts RM. Objective evaluation of negative dysphotopsia with Goldmann kinetic perimetry. *J Cataract Refract Surg* 2016;42:1626-33.
8. Masket S, Rupnik Z, Fram NR. Neuroadaptive changes in negative dysphotopsia during contralateral eye occlusion. *J Cataract Refract Surg* 2019;45:242-3.
9. Holladay JT, Zhao H, Reisin CR. Negative dysphotopsia: The enigmatic penumbra. *J Cataract Refract Surg* 2012;38:1251-65.
10. Masket S, Fram NR, Cho A, Park I, Pham D. Surgical management of negative dysphotopsia. *J Cataract Refract Surg* 2018;44:6-16.
11. Burke TR, Benjamin L. Sulcus-fixated intraocular lens implantation for the management of negative dysphotopsia. *J Cataract Refract Surg* 2014;40:1469-72.
12. Cooke DL, Kasko S, Platt LO. Resolution of negative dysphotopsia after laser anterior capsulotomy. *J Cataract Refract Surg* 2013;39:1107-9.
13. Folden DV. Neodymium: YAG laser anterior capsulectomy: Surgical option in the management of negative dysphotopsia. *J Cataract Refract Surg* 2013;39:1110-5.
14. Alapati NM, Harocopos GJ, Sheybani A. In-the-bag nasal intraocular lens optic truncation for treatment of negative dysphotopsia. *J Cataract Refract Surg* 2016;42:1702-6.
15. Masket S. Development of an anti-dysphotopic IOL, Expert Review of Ophthalmology 2019;14:1-3.
16. Pomerance GN, Evans DW. Test-retest reliability of the CSV-1000

- contrast test and its relationship to glaucoma therapy. *Invest Ophthalmol Vis Sci* 1994;35:3357-61.
17. Darian-Smith E, Versace P. Visual performance and positional stability of a capsulorhexis-fixated extended depth-of-focus intraocular lens. *J Cataract Refract Surg* 2020;46:179-87.
 18. Holland D, Rüfer F. New intraocular lens designs for femtosecond laser-assisted cataract operations: Chances and benefits. *Ophthalmologie* 2020;117:424-30.
 19. Ganesh S, Brar S. Swivel haptics anterior capsule-fixated intraocular lens. *Indian J Ophthalmol* 2018;66:1307-9.