

SHORT THESIS FOR THE DEGREE OF DOCTOR OF PHILOSOPHY (PhD)

**CLINICAL SIGNIFICANCE OF THREE-DIMENSIONAL TRANSESOPHAGEAL
ECHOCARDIOGRAPHIC PULMONARY VEIN IMAGING PRIOR TO CRYOBALLOON
ABLATION OF ATRIAL FIBRILLATION**

by László Tibor Nagy, MD

Supervisor: Zoltán Csanádi, PhD, DSc



UNIVERSITY OF DEBRECEN
DOCTORAL SCHOOL OF LAKI KÁLMÁN

DEBRECEN, 2023

Clinical significance of three-dimensional transesophageal echocardiographic pulmonary vein imaging prior to cryoballoon ablation of atrial fibrillation

By László Tibor Nagy, MD

Supervisor: Zoltán Csanádi, PhD, DSc

Doctoral School of Laki Kálmán., University of Debrecen

Head of the **Defense Committee:** György Balla, PhD, DSc, MHAS
Reviewers: Attila Nemes, PhD, DSc
Attila Kardos, PhD

Members of the Defense Committee: Attila Nemes, PhD, DSc
Attila Kardos, PhD
Anikó Ilona Nagy, PhD
István Lőrincz, PhD

The PhD Defense takes place at the Augusztia Lecture Hall of the Institute of Cardiology, Faculty of Medicine, University of Debrecen, on 2023.12.08 at 13:00 p.m.

Table of contents

1. LIST OF ABBREVIATIONS	6
2. INTRODUCTION AND LITERATURE REVIEW	8
2.1 The importance and dilemmas of "gold standard" preablation pulmonary vein imaging	8
2.2 Controversial pulmonary vein anatomical predictors	8
2.3 Potential echocardiographic alternatives to "gold standard" pulmonary vein imaging....	9
2.3.1 Intraprocedural intracardiac echocardiography	9
2.3.2 Preprocedural 3D transesophageal echocardiography	9
3. OBJECTIVES	10
3.1 Validation of 3D transesophageal echocardiography pulmonary vein measurements with cardiac CT.....	10
3.2 Investigation of the predictive role of validated 3D transesophageal echocardiography pulmonary vein parameters	10
4. PATIENTS AND METHODS	11
4.1 Validation of 3D transesophageal echocardiography pulmonary vein measurements... 11	
4.1.1 Patients.....	11
4.1.2 Cardiac CT imaging	11
4.1.3 3D transesophageal echocardiography examination and its evaluation.....	11
4.1.3.1 Technical aspects	11
4.1.3.2 Multiplanar reconstruction analysis of 3D images	12
4.1.3.3 Measured parameters of left atrial structures and detection of pulmonary vein anatomical variants	12
4.1.4 Statistical analysis.....	13
4.2 The predictive role of validated 3D transesophageal echocardiography pulmonary vein parameters.....	13
4.2.1 Patients.....	13
4.2.2 3D transesophageal echocardiography pulmonary vein imaging and multiplanar reconstruction analysis of 3D images (see sections 4.1.3.1 and 4.1.3.2).....	14
4.2.3 Cryoablation procedure.....	14
4.2.4 Follow-up of patients	14
4.2.5 Point-by-point redo ablation procedure	15
4.2.6 Statistical analysis	15
5. RESULTS.....	16
5.1 Results of cardiac CT validation of 3D transesophageal echocardiography pulmonary vein measurements	16
5.1.1 Baseline patient characteristics	16
5.1.2 Quality of 3D transesophageal echocardiography pulmonary vein imaging.....	16

5.1.3. Determination of inter-observer agreement between 3D transesophageal echocardiography and cardiac CT pulmonary vein measurements	16
5.1.4 Evaluation of the agreement between the two imaging techniques	17
5.1.4.1 Pearson’s linear regression	17
5.1.4.2 Bland–Altman analysis	17
5.1.5 3D transesophageal echocardiography imaging of anatomical variants of the pulmonary veins	17
5.2 Determining the predictive role of validated 3D transesophageal echocardiography pulmonary vein parameters	18
5.2.1 Patient characteristics.....	18
5.2.2 Atrial fibrillation recurrence during follow-up	18
5.2.3 Prognostic significance of clinical characteristics and 3D transesophageal echocardiography pulmonary vein parameters	18
5.2.4 Predictive value of biophysical parameters and the minor axis diameter of the right superior pulmonary vein ostium	19
5.2.5 Incidence of reconnected pulmonary veins.....	19
6. DISCUSSION	20
6.1 Clinical applicability and limitations of 3D transesophageal echocardiography pulmonary vein imaging	20
6.1.1 Main findings	20
6.1.2 Methodological considerations for preprocedural transesophageal echocardiography pulmonary vein imaging	20
6.1.3 Difficulties of 3D transesophageal echocardiography pulmonary vein imaging and possible solutions	21
6.1.4 Intraprocedural 3D intracardiac echocardiography.....	21
6.1.5 Potential clinical applications of 3D transoesophageal echocardiography pulmonary vein imaging.....	22
6.2 The prognostic role of validated 3D transoesophageal echocardiography pulmonary vein parameters.....	22
6.2.1 Main findings	22
6.2.2 Potential pulmonary vein anatomical predictors of outcome after cryoballoon ablation.....	22
6.2.3 Investigation of the relationship between validated 3D transoesophageal echocardiography pulmonary vein anatomical parameters and outcome of second-generation cryoballoon ablation.....	24
6.2.3.1 New methodological approach	24
6.2.3.2 Right superior pulmonary vein parameters	24
6.2.3.3 Left lateral ridge width.....	25

6.2.4 Significance of the prognostic role of the minor axis diameter of the right superior pulmonary vein ostium in clinical practice	25
6.3 New findings of the thesis	25
7. SUMMARY	27
8. LIST OF OWN PUBLICATIONS	29
9. ACKNOWLEDGEMENTS	32

1. LIST OF ABBREVIATIONS

2D (two-dimensional)

3D (three-dimensional)

3DTOE (three-dimensional transesophageal echocardiography)

a (major axis diameter of the pulmonary vein ostium)

AAD (antiarrhythmic drug)

AF (atrial fibrillation)

AR (arrhythmia recurrence)

b (minor axis diameter of the pulmonary vein ostium)

CB (cryoballoon)

CBG1 (first generation cryoballoon)

CBG2 (second generation cryoballoon)

CCT (cardiac computed tomography)

CHA₂DS₂-VASc score (C- congestive heart failure, H- hypertension >140/90 mmHg, A- age ≥75 years, D- diabetes mellitus, S- stroke, V- vascular disease, A- age 65-74 years, Sc- sex category)

CI (confidence interval)

CMR (cardiac magnetic resonance)

HR (hazard ratio)

ICC (intraclass correlation coefficient)

ICE (intracardiac echocardiography)

IQR (interquartile range)

LA (left atrial)

LAA (left atrial appendage)

LAd (left atrial antero-posterior diameter)

LC (left carina)

LCPV (left common pulmonary vein)

LIPV (left inferior pulmonary vein)

LLR (left lateral ridge)

LSPV (left superior pulmonary vein)

MPR (multiplanar review)

OA (ostium area)

OvI (ovality index)

PCC (Pearson correlation coefficient)

PV (pulmonary vein)

PVI (pulmonary vein isolation)

RF (radiofrequency)

RIPV (right inferior pulmonary vein)

R_s (Spearman's correlation coefficient)

RSPV (right superior pulmonary vein)

SD (standard deviation)

TOE (transesophageal echocardiography)

2. INTRODUCTION AND LITERATURE REVIEW

2.1 The importance and dilemmas of "gold standard" preablation pulmonary vein imaging

PVI is a cornerstone of transcatheter ablation procedures for AF. CCT or CMR imaging is routinely used in many centres to evaluate patients prior to ablation, arguing that detailed knowledge of PVs and LA anatomy helps to select the most appropriate ablation technology. Preprocedural assessment of PVs might provide especially useful information when PVI is planned with the CB, as the spherical balloon has potential limitations to accommodate to PV structures of different size and shape which may lead to isolation gaps along the PV perimeter. However, based on the results of the multicenter prospective FREEZE cohort study, nearly 98% of PVs can be isolated with the CBG2 even in the presence of difficult PV anatomy. Although these 3D imaging modalities are very useful for preablation evaluation, obvious drawbacks have to be considered related to their cost, and the radiation exposure in case of a CCT exam.

2.2 Controversial pulmonary vein anatomical predictors

In recent years, several PV anatomical features have been investigated as a potential predictor of the short- and long-term effectiveness of cryoablation. These included PV ostium parameters, intervenous carina and the width of the LLR between the LSPV and the LAA and the presence of PV anatomical variants. The varying, sometimes contradictory results in these studies might partly be explained with the use of different CB technologies.

2.3 Potential echocardiographic alternatives to "gold standard" pulmonary vein imaging

2.3.1 Intraprocedural intracardiac echocardiography

A potential alternative to preprocedural CCT imaging could be the use of intraprocedural ICE. In this case the ablation technique could be selected based on the results of ICE used as the initial step of the invasive procedure. This approach could help to avoid the unfavorable outcome due to the anatomical features of the PVs.

2.3.2 Preprocedural 3D transesophageal echocardiography

PVs could also be visualised with TOE in 90-100% of the cases in different studies. The intraprocedural use of TOE has been marginalized mainly due to safety issues related to esophageal injury, but remains a potential option for preprocedural evaluation of PVs and related anatomy especially with recent progress in 3D reconstruction of TOE images. TOE is still routinely used by many centers to exclude the presence of an LAA thrombus prior to ablation, thereby it could be a reasonable substitute for CCT/CMR with no additional time and cost required.

3. OBJECTIVES

3.1 Validation of 3D transesophageal echocardiography pulmonary vein measurements with cardiac CT

To date, no direct comparison between the results obtained with 3DTOE versus with another 3D imaging modalities has been reported. We therefore set out to prospectively evaluate the feasibility and the accuracy of 3DTOE for the assessment of the relevant LA and PV structures prior to PVI with the CBG2. In addition, CCT, considered the gold standard of cardiac imaging was also used in these patients in order to validate the measurements obtained with 3DTOE.

3.2 Investigation of the predictive role of validated 3D transesophageal echocardiography pulmonary vein parameters

We investigated whether the validated 3DTOE PV parameters have prognostic significance for the outcome of PVI performed with 28 mm CBG2.

4. PATIENTS AND METHODS

4.1 Validation of 3D transesophageal echocardiography pulmonary vein measurements

4.1.1 Patients

67 patients undergoing PVI with the CBG2 for paroxysmal or persistent AF were included in the study. All patients had a CCT exam within 14 days and a 3DTOE exam within 24 hours before the ablation procedure. All patients gave a written informed consent to the study, to both imaging methods and to CB ablation.

4.1.2 Cardiac CT imaging

CCT was performed with GE Lightspeed VCT (GE Healthcare, USA, HU1008CT03) Single Source 64-detector computed tomography device. Retrospective electrocardiogram-triggered mode was applied at acquisition. Reconstruction and postprocessing were performed with 0.625 mm slice thickness using standard filter at the end of the T-wave, and the measurements were executed offline in multiplanar reconstruction mode with 3D viewer program (Volume Viewer™ 15.0 Ext.2). Data collection was performed when the best „en face” view was reached.

4.1.3 3D transesophageal echocardiography examination and its evaluation

4.1.3.1 Technical aspects

Previously, our group has developed a novel method for the "en face" display of the PVs and the surrounding LA structures using 3DTOE and multiplanar reconstruction analysis of the 3D images. Philips EPIQ 7C echo scanner (Philips Healthcare, Andover, MA 01810 USA) was used with X7-2t or X8-2t 3DTOE transducers. All studies were performed by two cardiologists (CsJ, LTN).

Slight changes in the patient's left lateral decubitus position were allowed together with the rotation and the flexion of the probe during the examination if needed to improve the visibility of the PVs.

4.1.3.2 Multiplanar reconstruction analysis of 3D images

The recorded 3D images were analyzed with QLab software (Philips Medical Systems) offline. The software was suitable for 3D multiplanar reconstruction (multiplanar review - MPR). All measurements were done using an „en-face” view of the structure selecting a frame at the end of T wave. Recorded images were then evaluated and graded as to their suitability for further analysis as follows:

Grade I: The whole cross-sectional "en face" view of the PV could be visualized on the reconstructed 3D image.

Grade II: One third of the PV was missing on the reconstructed 3D cross-section image.

Grade III: At least the half of the PV could not be displayed on the reconstructed 3D cross-section image.

Only grade I images were considered suitable for detailed PV measurements.

4.1.3.3 Measured parameters of left atrial structures and detection of pulmonary vein anatomical variants

1. PV ostium parameters:

-the major axis diameter of the PV ostium (*a*)

-the minor axis diameter of the PV ostium perpendicular to „*a*” (*b*)

-ostium area (OA) measured with planimetry

2. Width of the LLR and the carina.

In addition, effort was made to detect the following anatomical variants: 1, common trunks including on the left (LCPV) and on the right side; 2, more than two (supernumerary) veins on either the left or on the right side.

4.1.4 Statistical analysis

For statistical analysis, we used IBM SPSS Statistics 26 program and MedCalc software version 13.3.3.0. All categorical variables were summarised as proportions and continuous variables as mean \pm SD. We selected randomly 17 patients in which 2 different operators (LTN, RU) performed separately and in blind manner a set of PV measurements both for 3DTOE and CCT. Interobserver reproducibility at 95% CI was determined from the ICC together with its corresponding p-value.

Inter-technique agreement between the two imaging methods was evaluated using linear regression with Pearson's correlation. The following rule of thumb for interpreting the size of the PCC was used: 0.90 to 1.00- very high positive correlation, 0.70 to 0.90 - high positive correlation, 0.50 to 0.70 - moderate positive correlation, 0.30 to 0.50 - low positive correlation, 0.00 to 0.30- negligible correlation.

PV anatomical parameters with a value of $PCC > 0.5$ were further tested to determine the biases and limits of agreement using Bland–Altman plot.

4.2 The predictive role of validated 3D transesophageal echocardiography pulmonary vein parameters

4.2.1 Patients

Consecutive patients who had successful PVI for paroxysmal AF using CBG2 between 20/11/2017 and 22/11/2020 were enrolled. Further criteria of enrollment included left atrial

antero-posterior diameter (LAd) \leq 45 mm and no structural cardiac abnormality on 2D echocardiography.

4.2.2 3D transesophageal echocardiography pulmonary vein imaging and multiplanar reconstruction analysis of 3D images (see sections 4.1.3.1 and 4.1.3.2).

4.2.3 Cryoablation procedure

All procedures were performed with a 28 mm CBG2 (Arctic Front Advance™, Medtronic, Minneapolis, MN, USA). At the end of the intervention, bidirectional block was confirmed in all PVs. The biophysical parameters of cryoapplications were recorded in each PV.

4.2.4 Follow-up of patients

All AADs were discontinued immediately after cryoablation. Oral anticoagulants were prescribed for 2 months postablation in all patients, while long-term management was based on the CHA₂DS₂-VASc score. All patients had follow-up visits at 6 weeks, 3, 6, 12 months after the intervention, and every 6 months thereafter. Patients were encouraged to seek for immediate medical help including ECG documentation in case of arrhythmia symptoms. Arrhythmia detection was facilitated with the use of a transtelephonic ECG system or with repeated Holter monitoring for 24-72 hours. AR was defined as the recurrence of AF lasting longer than 30 seconds regardless the timing after the ablation. Previously ineffective ADD was restarted in case of AR, and point by point redo intervention was offered to the patient in case of symptomatic AF episodes more than 3-month after the procedure despite AAD.

4.2.5 Point-by-point redo ablation procedure

A reconstructed anatomy of the left atrium was created using the CARTO3 system (Biosense Webster, Diamond Bar, CA, USA). During redo interventions RF ablation was performed in the segments demonstrating reconnection until isolation of the PVs was validated by bidirectional block. Ablation lines were created antrally approximately 0.5 to 1 cm from the PV ostia. The sites of reconnection were carefully recorded for statistical analysis.

4.2.6 Statistical analysis

The Kolmogorov–Smirnov test was used to determine the distribution of the data. The vast majority of parameters were non-normally distributed, therefore non-parametric tests were used. All categorical variables were summarised as proportions and continuous variables were displayed as median and IQR. The Mann-Whitney test was used to compare different groups of patients. Categorical variables were analyzed with the Chi-square and Fisher's exact test. Cox regression analyses were performed to determine variables independently associated with AR. Spearman's correlation coefficient (R_s) was used to measure the strength and direction of association between two ranked variables. A value of $p < 0.05$ was considered statistically significant. For statistical analysis, we used IBM SPSS Statistics 26 program.

5. RESULTS

5.1 Results of cardiac CT validation of 3D transesophageal echocardiography pulmonary vein measurements

5.1.1 Baseline patient characteristics

67 patients (age: 58.5 ± 10.5 years; 59.7 % man) undergoing AF ablation were enrolled. The majority of patients (97 %) had paroxysmal AF. The most common comorbidities included hypertension (53.7 %), diabetes mellitus (16.4 %) and peripheral vascular disease (10.4 %). The mean CHA₂DS₂-VASc score was 1.8 ± 1.2 .

5.1.2 Quality of 3D transesophageal echocardiography pulmonary vein imaging

56 out of 67 patients (83.6 %) were in sinus rhythm during 3DTOE exam. The highest ratio of the optimal image quality (grade I) was obtained for RSPV (100 %), while the lowest (83.6 %) for LIPV.

5.1.3. Determination of inter-observer agreement between 3D transesophageal echocardiography and cardiac CT pulmonary vein measurements

For all PV measurements, the ICC ranges of the interobserver evaluations were 0.87–0.99 with $p=0.001$. For 3DTOE measurements the highest ICC was calculated for RSPV OA (ICC=0.99, 95% CI: 0.97-0.99, $p=0.001$), while the lowest ICCs were obtained for LIPV OA (ICC=0.88, 95% CI:0.69-0.96, $p=0.001$) and for LC (ICC=0.88, 95% CI:0.71-0.95, $p=0.001$). For CCT measurements the highest ICCs were demonstrated for LSPV *b* (ICC=0.98, 95% CI: 0.94-0.99, $p=0.001$), for RSPV OA (ICC=0.98, 95% CI: 0.95-0.99, $p=0.001$) and for RSPV *b* (ICC=0.98, 95% CI: 0.95-0.99, $p=0.001$). The lowest ICC value was found for LIPV *a* (ICC=0.87, 95% CI:0.68-0.95, $p=0.001$).

5.1.4 Evaluation of the agreement between the two imaging techniques

Our definition of a clinically acceptable inter-technique agreement between the two imaging methods was a $PCC > 0.5$ together with limits of agreement $< 50\%$ and no significant biases.

5.1.4.1 Pearson's linear regression

A high positive correlation (PCC 0.7-0.9) was demonstrated in the absence of anatomical variants for the width of both carinas. A moderate positive correlation (PCC 0.5-0.7) was found for OA, a and b values of both superior PVs and for the LLR width. However RIPV OA, RIPV b and all LIPV parameters showed a low positive (PCC 0.3-0.5), while RIPV a a negligible (PCC 0.0-0.3) correlation.

5.1.4.2 Bland–Altman analysis

PV anatomical parameters with a value of $PCC > 0.5$ were further tested by Bland-Altman analysis. Bland-Altman plots demonstrated limits of agreement $< 50\%$ and no significant biases for the following PV parameters: RSPV OA, RSPV *a*, RSPV *b*, LSPV *b* and LLR.

5.1.5 3D transesophageal echocardiography imaging of anatomical variants of the pulmonary veins

Anatomical variants of the PVs were detected with the CCT, which is considered the gold standard. With echocardiography, right supernumerary PVs were correctly identified in 37.5 %, while LCPVs were identified in only 8.3 % of the cases.

5.2 Determining the predictive role of validated 3D transesophageal echocardiography pulmonary vein parameters

5.2.1 Patient characteristics

111 patients (mean age 58.06 ± 10.58 years; 60.4% male) were enrolled. Hypertension (66.7%), diabetes mellitus (16.4%), and vascular disease without coronary heart disease (12.6%) were the most common comorbidities associated with paroxysmal AF. Patients had a mean CHA₂DS₂-VASc score of 1.84 ± 1.19 .

All patients had preprocedural 3DTOE PV imaging of sufficient quality, complete isolation of all PVs at the end of the procedure. No complication including phrenic nerve injury was encountered in any patient.

5.2.2 Atrial fibrillation recurrence during follow-up

All patients were followed for at least 6 months. 65 patients (58.6%) remained free of arrhythmia during a mean FU of 617.00 ± 258.86 days, while AR was detected in 46 patients (41.4%) 112.39 ± 112.39 days after cryoablation. No significant differences were detected between the AR and AR-free patient groups.

5.2.3 Prognostic significance of clinical characteristics and 3D transesophageal echocardiography pulmonary vein parameters

The predictive role of clinical characteristics and 3DTOE PV parameters was examined by Cox regression analysis. Based on this, longer RSPV *b* was found to be the only significant prognostic factor for AR (HR 1.059; 95% CI 1.000-1.121; $p=0.048$). Out of 111 patients, RSPV $b \geq 28$ mm was found in 9, and 6 of them had AR. This anatomical feature increased the risk of AR almost threefold (HR 3.010; 95% CI 1.270-7.134, $p=0.012$). In addition, in all patients with

RSPV $b \geq 28$ mm, AR occurred within 21 days after the ablation. Neither the other 3DTOE PV parameters nor the clinical characteristics of the patients had predictive role for AR.

5.2.4 Predictive value of biophysical parameters and the minor axis diameter of the right superior pulmonary vein ostium

Cumulative duration of applications and number of applications demonstrated significant differences in AR versus AR-free patients, however, the biophysical parameters indicated statistical relationship with neither RSPV b nor AR-free time duration. Spearman's correlation between RSPV b and AR-free time duration in patients with AR demonstrated a significant negative correlation ($R_s = -0.368$, $p=0.012$).

5.2.5 Incidence of reconnected pulmonary veins

25 patients (13 males, mean age: 58.80 ± 11.38 years) underwent point-by-point redo intervention during FU. At least one PV reconnection was confirmed in all redo patients. Reconnection occurred 38 times in LSPV, 31 times in LIPV, 50 times in RSPV and 40 times in RIPV. Reconnections were 1.75 times more likely (Chi-square test, Odds ratio=1.752; 95% CI 1.109-2.768; $p=0.0214$) in the RSPV as compared to the other 3 PVs altogether.

6. DISCUSSION

6.1 Clinical applicability and limitations of 3D transesophageal echocardiography pulmonary vein imaging

6.1.1 Main findings

This is the first prospective direct comparison of preprocedural 3DTOE and CCT for visualisation and numerical characterisation of PV anatomy by measuring multiple parameters potentially relevant to the success of PVI with CB. We also tested the TOE acquisition technique developed by our group specifically for the optimal 3DTOE image acquisition and visualisation of the PV structures. Based on the fact that clinically acceptable inter-technique agreement was demonstrated for all RSPV, LSPV b and LLR parameters, 3DTOE provides reliable data on anatomical features of superior PVs that may be important for CB ablation. However the accuracy of 3DTOE in the presence of anatomical variants and for the assessment of both inferior PVs was not acceptable.

6.1.2 Methodological considerations for preprocedural transesophageal echocardiography pulmonary vein imaging

The ROTEA study prospectively compared different PV measurements obtained with 2DTOE versus with CCT before and after AF ablation. In this study, 2DTOE consistently underestimated the maximum ostial dimensions compared with CCT, especially for the inferior PVs, likely due to the limited field of view resulting from the close proximity of the TOE probe to these cardiac structures. Further, LCPVs revealed by CCT were identified with TOE in only 54 % of the cases.

In our research, 3D reconstruction obtained in the left lateral decubitus position yielded excellent (grade I) image quality in 100 %, 95.5 %, 92.5 % and 83.6 % for RSPV, LSPV, RIPV

and LIPV, respectively. Anatomical variants on the right side could be visualised at a low, but still significantly higher rate (37.5 %) than on the left (7.7 %). These observations are in line with the findings of Faletra et al, who considered the distance between the esophagus and the ipsilateral PVs as a major limiting factor of proper visualisation.

6.1.3 Difficulties of 3D transesophageal echocardiography pulmonary vein imaging and possible solutions

Our own observations also suggest the importance of the patient's position in the acquisition of TOE images: in the left lateral decubitus position used as the base position, only the RSPV could be visualized with 100% class I quality. Theoretically, this suggests that the altered position of the patient could potentially improve the image quality of the other PVs during TOE examination. These considerations argue for further modification of the TOE examination technique in special cases where the evaluation of PVs and associated structures is important. Hypothetically, the design of a novel TOE examination table capable of axial rotation could allow safe and easy right or left rotation of the patient and thus allow for adequate quality imaging of all PVs. Such a technical development could open new opportunities for the clinical application of 3D TOE.

6.1.4 Intraprocedural 3D intracardiac echocardiography

In recent years, advances in electronic and transducer technology have allowed the development and successful implementation of real-time 3D ICE. This tool could overcome the limitations mentioned above by displaying PV structures more precisely even in the case of complex anatomy.

6.1.5 Potential clinical applications of 3D transoesophageal echocardiography pulmonary vein imaging

3DTOE PV assessment with the technique described in this study can be performed as part of the routine preablation TOE exam to exclude LAA thrombus. Incorporation of 3DTOE data in 3D electroanatomical mapping systems would further expand the use of this approach as a cheaper and simpler method for preablation evaluation of patients.

6.2 The prognostic role of validated 3D transoesophageal echocardiography pulmonary vein parameters

6.2.1 Main findings

In our prospective study, we demonstrated that the minor axis diameter of RSPV determined preprocedurally with 3DTOE might be a significant predictor for the development of AR after CB ablation with the CBG2: an almost 3-fold relative risk was associated with a diameter exceeding 28 mm. This anatomical feature was demonstrated in 9 out of the 111 patients. The association of RSPV *b* with AR was independent of the biophysical parameters of cryoapplication. Based on our findings during „redo” procedures, PV reconnections were found 1.75 times more likely in the RSPV than in the other PVs altogether. This result might be consistent with the predictive role of RSPV *b*: the preponderance of reconnections in the RSPV might suggest that this vein might be a more common predilection site.

6.2.2 Potential pulmonary vein anatomical predictors of outcome after cryoballoon ablation

The shape and the size of the PV ostia has been considered as a potential predictor of success with balloon based procedures. Earlier CCT studies demonstrated, that the OA of the right PVs is greater than that of the left PVs. Güler et al. reported that larger RSPV sizes were

associated with more frequent recurrences, and the maximum diameter of the RSPV ostium was an independent predictor of AR after CB ablation with the 28 mm CBG2.

To characterize the shape of PV ostia, the PV ovality (eccentricity) index (OvI) was introduced based on the longest (a') and the shortest (b') PV ostium diameters using the formula of $2x(a'-b')/(a'+b')$, while others used the ratio of a'/b' to characterize the degree of PV ovality. Investigations on the predictive value of the ovality of PVs with the use of the CBG1 demonstrated conflicting results. Baran et al. demonstrated no relationship between the ovality of the PV ostium and AR. Sorgente et al. described an inverse relationship between the OvI of the left PVs and the degree of PV occlusion, but no correlation between the OvI and the degree of occlusion for the right sided PVs. Further, high values of OvI in the left PVs but not for the right ones were found to be a significant predictor of AR by some authors. However, no such relationship was reported between the OvI and the acute or medium-term success after CBG1 ablation in other reports.

Results from newer CCT studies on the efficacy of CBG2 suggest that the CCT-based PV composite scoring system is useful for identifying "unfavourable" anatomy. Moreover, other authors argue that assessing PV anatomy with CCT prior to the PVI may help to individualise the optimal ablation technology.

Based on the recently published CCT-based assessment of PV anatomical characteristics, a revision of the current 28 mm CBG2 design is recommended for the future of CB technology. Compared to clinical and procedural factors, certain PV variations (more oval LSPV, sharper LC for both LSPV and LIPV, more inferior RIPV orientation, and more anterior RSPV orientation) appear to have the greatest impact on PVI durability. Increasing the balloon size up to 30/32 mm, and using a more compliant balloon, could possibly increase the efficacy of PVI even in case of challenging anatomy. If adverse PV anatomy is revealed on CCT, operator may prefer to use a cryoablation balloon system with a larger balloon.

6.2.3 Investigation of the relationship between validated 3D transoesophageal echocardiography pulmonary vein anatomical parameters and outcome of second-generation cryoballoon ablation

6.2.3.1 New methodological approach

The methodology used in our study differs significantly from the methods described so far in the literature. First of all, we enrolled patients with paroxysmal AF only, who had no significantly enlarged LAd or other cardiac abnormality on 2D echocardiography. We selected this homogenous cohort not only because these patients are considered suitable for AF ablation using a PVI only approach by many centers, but also because AR can be considered a reasonable surrogate of PV reconnection in the majority of these individuals. This was confirmed by our findings during redo interventions.

CBG2 was used for PVI in all patients. In addition, we modified the previously described methodology to characterize the shape of the ostium: instead of the shortest (*b'*) diameter used in OvI, we defined the minor axis (*b*) diameter in a plane perpendicular to the major axis diameter (*a*) of the PV ostium.

6.2.3.2 Right superior pulmonary vein parameters

We focused on the morphological features of the RSPV because we found good inter-technique agreement for this vein. The higher incidences of reconnection detected in the RSPV in our redo cases also suggest that this vein might be a more frequent predilection site. We demonstrated, that the minor axis diameter of RSPV determined preprocedurally with 3D TOE might be a significant predictor for the development of AR after ablation: an almost 3-fold relative risk was associated with a diameter exceeding 28 mm. The explanation we would like to propose for this finding is that the larger the minor axis diameter of RSPV, the more distal the level of isolation, a situation might not be realized on fluoroscopy without electroanatomical

mapping. Isolation not including the antrum is a recognized cause of reduced long-term success after PVI with any technique. In patients with RSPV $b \geq 28$ mm, AR occurred in a strikingly short period of time after the procedure, a phenomenon we can not provide an explanation for based on our data.

6.2.3.3 Left lateral ridge width

Although a long and wide LLR was found to be a significant predictor of AR in other studies with use of the 28 mm CBG1, our results with the 28 mm CBG2 could not confirm this finding.

6.2.4 Significance of the prognostic role of the minor axis diameter of the right superior pulmonary vein ostium in clinical practice

Our results suggest that the long-term results of PVI with CBG2 might be less favourable when RSPV $b \geq 28$ mm is detected with 3DTOE. This finding was demonstrated in 8.1 % of our patients with paroxysmal AF, no significantly enlarged LAd and no structural cardiac disease. These patients, representing a relative minority can be identified during preablation 3DTOE, an exam routinely performed before the ablation at most centers. Alternative techniques of PVI (point-by-point RF ablation, Pulsed Field Ablation) or the use of larger balloons might be considered in this preselected group of patients.

6.3 New findings of the thesis

1. This is the first prospective direct comparison between preprocedural 3DTOE and CCT imaging to visualize and numerically characterize PV anatomy by measuring several PV parameters potentially relevant to the success of PVI with CBG2.
2. We demonstrated clinically acceptable inter-technique agreement for RSPV OA, a , b and LSPV b and LLR parameters, suggesting that 3DTOE provides reliable preprocedural data on

most of the anatomical features of superior PVs in clinical practice. On this basis, 3DTOE evaluation of superior PVs can be performed as part of a routine preprocedural TOE examination to exclude LAA thrombus.

3. The 3D reconstruction of the RSPV in the left lateral decubitus position was 100% feasible with excellent (grade I) image quality. However, the accuracy of the 3DTOE performed in this body position in the presence of PV anatomical variants as well as for the assessment of both inferior PVs was not acceptable.

4. In our prospective study, we demonstrated that the minor axis diameter (b) of the RSPV ostium preprocedurally determined by 3DTOE might be a significant predictor of AR development after CB ablation with CBG2. The correlation between RSPV b and AR was independent of the biophysical parameters of cryoapplication.

5. In a preselected group of patients with RSPV $b \geq 28$ mm, alternative non balloon-based techniques of PVI (point by point RF ablation, Pulsed Field Ablation) or the use of a larger balloon might be considered.

6. The predictive role of RSPV b might be consistent with the fact that in our homogeneous patient cohort, PV reconnections during redo interventions were 1.75 times more likely in RSPV than in the other 3 PVs altogether.

7. In case of RSPV $b \geq 28$ mm, the relative risk of developing AR was nearly 3-fold.

This anatomical feature was detected in 8.1% of our patients with paroxysmal AF, non-significantly enlarged LAd and no structural heart disease.

7. SUMMARY

Background: Anatomical characteristics of the left atrium and the pulmonary veins (PVs) may be relevant to the success rate of 28 mm second generation cryoballoon (CBG2)-ablation for atrial fibrillation (AF). Cardiac computed tomography (CCT) is considered as the gold standard for preablation imaging. Recently, three-dimensional transesophageal echocardiography (3DTOE) has been proposed for preprocedural assessment of cardiac structures relevant to CB-ablation. The accuracy of 3DTOE has not been validated by other imaging modalities.

Objective 1: We prospectively evaluated the feasibility and the accuracy of 3DTOE imaging for the assessment of PV structures prior to pulmonary vein isolation (PVI). In addition, CCT was used to validate the measurements obtained with 3DTOE. **Methods 1:** PV anatomy of 67 patients (59.7 % men, mean age 58.5 ± 10.5 years) was assessed using both 3DTOE and CCT scan prior to PVI with the CBG2. The following parameters were measured: PV ostium area (OA), the major and minor axis diameters of the ostium, the width of the carina and the width of the left lateral ridge (LLR). Evaluation of inter-technique agreement was based on linear regression with Pearson correlation coefficient and Bland-Altman analysis.

Results 1: A direct comparison of 3DTOE and CCT imaging, has demonstrated clinically acceptable inter-technique agreement for the OA of the right superior PV (RSPV) and its major (*a*) and minor axis (*b*) diameters, the LLR and the *b* diameter of the left superior PV.

Objective 2: We investigated the predictive value of these parameters for arrhythmia recurrence (AR) after PVI with the 28 mm CBG2. **Methods 2:** 111 patients (67 men, mean age 58.06 ± 10.58 years) undergoing 3DTOE before PVI with the CBG2 for paroxysmal AF were followed. “Point by point” redo intervention was offered in case of AR and reconnected PVs were defined. **Results 2:** During a mean follow-up of 617 ± 258.86 days, 65 patients (58.9%) remained free of AR. Longer RSPV *b* was found to be the only significant predictor for AR (HR 1.059; 95% CI 1.000-1.121; $p=0.048$). RSPV *b* ≥ 28 mm resulted in a threefold (HR 3.010;

95% CI 1.270-7.134, $p=0.012$) increase in the risk of AR. The association of RSPV b with AR was independent of the biophysical parameters of cryoapplications. In 25 “redo” patients, reconnections were found 1.75 times more likely in the RSPV than in the other 3 PVs altogether.

Conclusions: Detailed assessment of the RSPV parameters, LLR and LSPV b is feasible with 3DTOE prior to AF ablation. RSPV b measured with 3DTOE might be a significant predictor of AR after PVI with the CBG2. In case of RSPV b exceeding 28 mm, alternative PVI techniques or use of larger balloon might be considered.

8. LIST OF OWN PUBLICATIONS



**UNIVERSITY of
DEBRECEN**

**UNIVERSITY AND NATIONAL LIBRARY
UNIVERSITY OF DEBRECEN**

H-4002 Egyetem tér 1, Debrecen

Phone: +3652/410-443, email: publikaciok@lib.unideb.hu

Registry number: DEENK/453/2023.PL
Subject: PhD Publication List

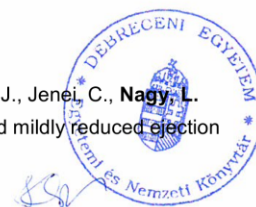
Candidate: László Tibor Nagy
Doctoral School: Kálmán Laki Doctoral School
MTMT ID: 10036993

List of publications related to the dissertation

1. **Nagy, L. T.**, Papp, T. B., Urbancsek, R., Jenei, C., Csanádi, Z.: Right Superior Pulmonary Vein Parameter Determined by Three-Dimensional Transesophageal Echocardiography is an Independent Predictor of the Outcome After Cryoballoon Isolation of The Pulmonary Veins. *Cardiol. J. "Accepted by Publisher"*, 2023.
IF: 2.9 (2022)
2. **Nagy, L. T.**, Jenei, C., Papp, T. B., Urbancsek, R., Kolozsvári, R., Rácz, Á., Ráduly, A. P., Veisz, R., Csanádi, Z.: Three-dimensional transesophageal echocardiographic evaluation of pulmonary vein anatomy prior to cryoablation: validation with cardiac CT scan. *Cardiovasc Ultrasound. 21* (1), 1-11, 2023.
DOI: <http://dx.doi.org/10.1186/s12947-023-00305-9>
IF: 1.9 (2022)

List of other publications

3. Urbancsek, R., Csanádi, Z., Forgács, I. N., Papp, T. B., Boczán, J., Barta, J., Jenei, C., **Nagy, L. T.**, Rudas, L.: The Feasibility of Baroreflex Sensitivity Measurements in Heart Failure Subjects: the Role of Slow-patterned Breathing. *Clin. Physiol. Funct. Imaging. 42* (2), 260-268, 2022.
DOI: <http://dx.doi.org/10.1111/cpf.12755>
IF: 1.8
4. Urbancsek, R., Csanádi, Z., Forgács, I. N., Papp, T. B., Boczán, J., Barta, J., Jenei, C., **Nagy, L. T.**, Rudas, L.: Sympathetic activation in heart failure with reduced and mildly reduced ejection fraction: the role of aetiology. *ESC Heart Failure. 8* (6), 5112-5120, 2021.
DOI: <http://dx.doi.org/10.1002/ehf2.13580>
IF: 3.612





5. Hajas, O., Bagoly, Z., Tóth, N. K., Urbancsek, R., Kiss, A., Kovács, K. B., Sarkady, F., Nagy, A. C., Oláh, A., **Nagy, L. T.**, Clemens, M., Csiba, L., Csanádi, Z.: Intracardiac Fibrinolysis and Endothelium Activation Related to Atrial Fibrillation Ablation with Different Techniques. *Cardiol Res Pract.* 2020, 1-8, 2020.
DOI: <http://dx.doi.org/10.1155/2020/1570483>
IF: 1.866
6. Jenei, C., **Nagy, L. T.**, Urbancsek, R., Czuriga, D., Csanádi, Z.: Three-Dimensional Echocardiographic Method for the Visualization and Assessment of Specific Parameters of the Pulmonary Veins. *J. Vis. Exp.* 164, 1-13, 2020.
DOI: <http://dx.doi.org/10.3791/61215>
IF: 1.355
7. Bagoly, Z., Hajas, O., Urbancsek, R., Kiss, A., Fiak, E., Sarkady, F., Tóth, N. K., Orbán-Kálmándi, R. A., Kovács, K. B., **Nagy, L. T.**, Nagy, A. C., Kappelmayer, J., Csiba, L., Csanádi, Z.: Uninterrupted Dabigatran Administration Provides Greater Inhibition against Intracardiac Activation of Hemostasis as Compared to Vitamin K Antagonists during Cryoballoon Catheter Ablation of Atrial Fibrillation. *J Clin Med.* 9 (9), 1-13, 2020.
DOI: <http://dx.doi.org/10.3390/jcm9093050>
IF: 4.241
8. **Nagy, L. T.**, Jenei, C., Csanádi, Z.: Pulmonalis vénaizoláció előtt elvégzett echokardiográfia speciális szempontjai. *Cardiol. Hung.* 48 (4), 252-262, 2018.
DOI: <http://dx.doi.org/10.26430/CHUNGARICA.2018.48.4.252>
9. **Nagy, L. T.**, Kertész, A. B., Szegedi, A., Pethő, Á., Balla, J., Édes, I., Csanádi, Z.: Reszinkronizációra non-reszponder szívelégtelen beteg kezelése peritoneális dialízissel és elektróda repozícióval. *Cardiol. Hung.* 46, 14-17, 2016.
10. **Nagy, L. T.**: Covercard a nők védelmében. *Háziorv. Továbbk. Szle.* 17 (9), 582-583, 2012.





**UNIVERSITY of
DEBRECEN**

**UNIVERSITY AND NATIONAL LIBRARY
UNIVERSITY OF DEBRECEN**

H-4002 Egyetem tér 1, Debrecen

Phone: +3652/410-443, email: publikaciok@lib.unideb.hu

11. **Nagy, L. T.**, Rozsnyai, E., Vincze, K., Misz, M., Tóth, C.: Kardiális manifesztációk echokardiográfiás vizsgálata dializált krónikus vesebetegeken.
É-K-mo. Orv. Szle. 6 (1-2), 12-17, 2005.

Total IF of journals (all publications): 17,674

Total IF of journals (publications related to the dissertation): 4,8

The Candidate's publication data submitted to the iDEa Tudóstér have been validated by DEENK on the basis of the Journal Citation Report (Impact Factor) database.

03 October, 2023



9. ACKNOWLEDGEMENTS

I would like to express my gratitude to my supervisor, Professor Dr. Zoltán Csanádi, who supported my PhD work with his high level and precise professional knowledge and shaped my thinking with his constructive advice. In addition, as the Head of the Cardiology Clinic, he provided practical and theoretical advice both during the research and the writing of the publications, and created the conditions for carrying out the research.

I am also grateful to Katalin Hodosi, who provided me with a lot of useful advice during the statistical calculations.

I thank Dr. Csaba Jenei for his professional help and constructive professional advice during the 3D TOE studies.

I would also like to express my gratitude to Dr. Réka Urbancsek, who provided invaluable help with the pulmonary vein measurements and also assisted me tirelessly in the preparation and editing of the publications.

I thank Dr. Tímea Papp for her help in recording clinical data and editing the publications.

Last but not least, I would like to express my gratitude to my wife Dr. Katalin Vincze and my sons Vendel and Zsombor for their patience and encouragement to persevere.