


# Terminology for describing normally sited and ectopic pregnancies on ultrasound: ESHRE recommendations for good practice

The ESHRE working group on Ectopic Pregnancy, Emma Kirk<sup>1</sup>, Pim Ankum<sup>2</sup>, Attila Jakab<sup>3</sup>, Nathalie Le Clef<sup>4</sup>, Artur Ludwin<sup>5</sup>, Rachel Small<sup>6</sup>, Tina Tellum<sup>7</sup>, Mira Töyli<sup>8</sup>, Thierry Van den Bosch<sup>9,10</sup>, and Davor Jurkovic<sup>11,\*</sup>

<sup>1</sup>Early Pregnancy and Emergency Gynaecology Unit, Royal Free Hospital London, London, UK <sup>2</sup>Amsterdam Medical Centre, Amsterdam, the Netherlands <sup>3</sup>Department of Obstetrics and Gynecology, University of Debrecen, Debrecen, Hungary <sup>4</sup>European Society of Human Reproduction and Embryology, Belgium <sup>5</sup>Department of Gynecology and Oncology, Jagiellonian University Medical College, Krakow, Poland <sup>6</sup>Heart of England NHS Foundation Trust, Birmingham, UK <sup>7</sup>Department of Gynecology, Oslo University Hospital, Ullevål, Oslo, Norway <sup>8</sup>Fertinova Clinics, Helsinki, Finland <sup>9</sup>Department of Obstetrics and Gynaecology, University Hospital Leuven, Belgium <sup>10</sup>Laboratory for Tumor Immunology and Immunotherapy, Leuven, KU, Belgium <sup>11</sup>Department of OB/GYN, University College Hospital, London, UK

\*Correspondence address. Department of OB/GYN, University College Hospital, 235 Euston Road, London NW1 2BU, UK. E-mail: davor.jurkovic@nhs.net; guidelines@eshre.eu  <https://orcid.org/0000-0001-6487-5736>

Submitted on October 6, 2020; resubmitted on October 9, 2020; editorial decision on October 15, 2020

**STUDY QUESTION:** What recommendations can be provided to improve terminology for normal and ectopic pregnancy description on ultrasound?

**SUMMARY ANSWER:** The present ESHRE document provides 17 consensus recommendations on how to describe normally sited and different types of ectopic pregnancies on ultrasound.

**WHAT IS KNOWN ALREADY:** Current diagnostic criteria stipulate that each type of ectopic pregnancy can be defined by clear anatomical landmarks which facilitates reaching a correct diagnosis. However, a clear definition of normally sited pregnancies and a comprehensive classification of ectopic pregnancies are still lacking.

**STUDY DESIGN, SIZE, DURATION:** A working group of members of the ESHRE Special Interest Group in Implantation and Early Pregnancy (SIG-IEP) and selected experts in ultrasound was formed in order to write recommendations on the classification of ectopic pregnancies.

**PARTICIPANTS/MATERIALS, SETTING, METHODS:** The working group included nine members of different nationalities with internationally recognised experience in ultrasound and diagnosis of ectopic pregnancies on ultrasound. This document is developed according to the manual for development of ESHRE recommendations for good practice. The recommendations were discussed until consensus by the working group, supported by a survey among the members of the ESHRE SIG-IEP.

**MAIN RESULTS AND THE ROLE OF CHANCE:** A clear definition of normally sited pregnancy on ultrasound scan is important to avoid misdiagnosis of uterine ectopic pregnancies. A comprehensive classification of ectopic pregnancy must include definitions and descriptions of each type of ectopic pregnancy. Only a classification which provides descriptions and diagnostic criteria for all possible locations of ectopic pregnancy would be fit for use in routine clinical practice. The working group formulated 17 recommendations on the diagnosis of the different types of ectopic pregnancies on ultrasound. In addition, for each of the types of ectopic pregnancy, a schematic representation and examples on 2D and 3D ultrasound are provided.

**LIMITATIONS, REASONS FOR CAUTION:** Owing to the limited evidence available, recommendations are mostly based on clinical and technical expertise.

**WIDER IMPLICATIONS OF THE FINDINGS:** This document is expected to have a significant impact on clinical practice in ultrasound for early pregnancy. The development of this terminology will help to reduce the risk of misdiagnosis and inappropriate treatment.

**STUDY FUNDING/COMPETING INTEREST(S):** The meetings of the working group were funded by ESHRE. T.T. declares speakers' fees from GE Healthcare. The other authors declare that they have no conflict of interest.

**TRIAL REGISTRATION NUMBER:** N/A

**DISCLAIMER:** This Good Practice Recommendations (GPR) document represents the views of ESHRE, which are the result of consensus between the relevant ESHRE stakeholders and where relevant based on the scientific evidence available at the time of preparation. ESHRE's GPRs should be used for informational and educational purposes. They should not be interpreted as setting a standard of care or be deemed inclusive of all proper methods of care nor exclusive of other methods of care reasonably directed to obtaining the same results. They do not replace the need for application of clinical judgement to each individual presentation, nor variations based on locality and facility type. Furthermore, ESHRE's GPRs do not constitute or imply the endorsement, recommendation or favouring of any of the included technologies by ESHRE.

**Key words:** ectopic pregnancy / terminology / ultrasound / early pregnancy / ESHRE / guideline

## WHAT DOES THIS MEAN FOR PATIENTS?

This paper describes good practice recommendations for terminology to describe normally sited and ectopic pregnancies on ultrasound. By describing the exact locations of the ectopic pregnancies, this terminology should help to reduce the risk of misdiagnosis and inappropriate treatment. These technical recommendations are not directly relevant to patients, but they should ensure that patients encountering an ectopic pregnancy receive the best care possible.

## Introduction

Ultrasound is the most commonly used imaging modality for assessing women with suspected early pregnancy complications. An early pregnancy ultrasound examination has three main objectives: (i) to confirm the location and number of pregnancies, (ii) to establish whether a normally implanted pregnancy has the potential to develop further beyond the first trimester and (iii) to assess the risk to maternal health posed by ectopic pregnancy.

Most ultrasound examinations undertaken in early pregnancy are performed using a transvaginal route. This facilitates detailed studies of pelvic organs and earlier and more accurate detection of various developmental markers in early pregnancy than a transabdominal scan (Cacciatori *et al.*, 1989). There are, however, cases when a transabdominal scan is also indicated, such as in those with a large fibroid uterus or adhesions fixing the uterus to the anterior abdominal wall.

Although progress has been made in reaching a consensus on criteria for differentiating between potentially ongoing (live) and failing first-trimester pregnancies (miscarriages) (Doubilet *et al.*, 2013), there has been little work on refining the criteria for the diagnosis of pregnancy location and differentiating between normally and abnormally sited pregnancies. The first step towards improving ultrasound diagnosis of ectopic pregnancy is a clear agreement on the definition of a pregnancy which is implanted in the correct physiological place. Following that, there should also be a consensus regarding diagnostic criteria to differentiate between various types of ectopic pregnancies. Current diagnostic criteria stipulate that each type of ectopic pregnancy can be defined by clear anatomical landmarks which facilitates reaching a correct diagnosis (Elson *et al.*, 2016). However, there are no defined

anatomical barriers between the uterine cavity, Fallopian tubes and abdominal cavity. In fact, pregnancies can potentially implant anywhere along this passage from the ovary to the cervical canal, with some pregnancies being partially implanted within and partially outside the uterine cavity (Jurkovic *et al.*, 2003). A comprehensive classification of ectopic pregnancy must allow for these possibilities. Only a classification which provides descriptions and diagnostic criteria for all possible locations of ectopic pregnancy would be fit for use in routine clinical practice. Development of uniform terminology will also help to reduce the risk of misdiagnosis and inappropriate treatment. A good example of this problem has been inconsistent use of the term 'cornual' pregnancy which has been used to describe a wide range of pregnancy locations from normal pregnancies implanted in the lateral aspect of the uterine cavity through to interstitial pregnancies and pregnancies in the rudimentary cornu of unicornuate uterus (Baltarowich, 2017). Treatment of ectopic pregnancies was beyond the scope of our recommendations and has not been addressed in this manuscript.

## Materials and methods

ESHRE recommendations for good practice are developed based on the Manual for development of recommendations for good practice, which can be consulted at the ESHRE website ([www.eshre.eu/guidelines](http://www.eshre.eu/guidelines)). The manual describes a nine-step procedure for writing recommendation documents.

This current paper was initiated by the ESHRE Special Interest Group in Implantation and Early Pregnancy (SIG-IEP). In the first phase, information on commonly used terminology in ectopic pregnancy and

the acceptability of changes was collected through an online survey (utilising Survey Monkey). The survey, developed by E.K. and D.J., consisted of 4 demographic questions and 13 questions on ectopic pregnancy terminology (Supplementary data S1). Members of the SIG-IEP and of the committee of national representatives were invited by email to complete the survey. The survey was open for 4 weeks (from 21 January to 17 February 2019).

The results of the survey were discussed in a working group (WG) of the initial members and experts selected from the survey responders. Two in-person meetings were organised in which the results of the survey were further considered, and decisions were made on the terminology to be used for ectopic pregnancy. As per the manual for development of recommendation papers, a stakeholder review was organised, ESHRE members and representatives of national and international organisations were invited to review the draft of the paper. We received a total of 213 comments and suggestions from four organisations and 27 individuals. The manuscript was modified taking into account this feedback. The responses to the received comments and the revised paper were approved at the third WG meeting which was held on-line.

## Results

There were 362 people that started the survey and 204 that completed the entire survey. The latter consisted of gynaecologists and obstetricians (91%), nurses and midwives (3%) and other professions (6%). Although nurses and midwives play an important role in delivering early pregnancy care worldwide, they accounted only for a small proportion of respondents which reflects the membership of ESHRE. Most European countries were represented in the survey by at least one respondent. Ten or more replies were received from Greece, the Netherlands, Spain and the UK. There were also 57 replies from outside Europe; 5 from Australia, 29 from Asia, 20 from America and 3 from Africa. Respondents represented a mixed group regarding expertise in ultrasound; 49% stated that they had a diploma in ultrasound. Also, the numbers of early pregnancy scans performed annually varied widely; 15% reported <50 scans, 27% between 50 and 100 scans, 18% between 100 and 200 scans and 40% reported performing over 200 scans per year.

For questions where respondents were asked whether they agreed (either yes/no or in a five-point Likert scale), results are presented in Table 1. There was high level of agreement on the notion that ectopic pregnancies could be classified as intrauterine and extrauterine. The respondents also agreed that ectopic pregnancies could be described as partial or complete and that term 'chronic ectopic pregnancy' should not be used in clinical practice. However, there was significant heterogeneity on the description of a normal (live) pregnancy in the correct position within the uterine cavity (question 5), how to describe a pregnancy which breaches the endometrial/myometrial junction and invades the myometrium of the uterine corpus (question 8) and how to describe an ectopic pregnancy with no embryo or cardiac activity (question 11).

The results of the discussion within the WG are presented below as recommendations.

## Recommendations

All pregnancies can be described as either normally sited, ectopic or of unknown location. Further terminology for normally sited and ectopic pregnancy is outlined in the sections below. Regarding pregnancy of unknown location (PUL), this term is reserved for when no pregnancy is visualised on transvaginal scan in clinically stable women with a positive urine pregnancy test (Condous *et al.*, 2006). It is essential that the ultrasound examination is carried out in a systematic manner and all possible locations for an implanted pregnancy are examined. It is also important to emphasise that all women presenting with PUL should be offered follow-up to determine a final clinical outcome. The outcomes include a normally sited pregnancy (ongoing or failed), an ectopic pregnancy or spontaneously resolved PUL when hCG declines to pre-pregnancy levels without the pregnancy being identified on any of the follow-up scans. Management of PULs was outside the scope of this project.

When performing a scan in early pregnancy, particularly in women who conceived following fertility treatment, it is important to record the number of pregnancies and describe the location of each as discussed below. It should be noted that in case of more than one pregnancy, they can be: (i) both or all normally sited (twin, triplet, etc.), (ii) one/more normally sited and one/more ectopic (heterotopic) or (iii) both or all in abnormal locations (co-existent ectopic pregnancies).

### Normally sited pregnancy

Health professionals around the world use the term 'normal intrauterine pregnancy' when referring to healthy pregnancies. 'Normal' usually refers to the evidence of cardiac activity, whilst the term 'intrauterine' implies that the pregnancy is located in the correct place, i.e. within the uterus. The difficulty is that many ectopic pregnancies within the confines of the uterus, such as a cervical or intramural pregnancy, can also contain a live embryo/foetus. Therefore, the term 'normal intrauterine pregnancy' does not obviously discriminate between a pregnancy which is normally implanted within the uterine (endometrial) cavity from an ectopic pregnancy which is located within the uterus, but outside the uterine cavity. This lack of clear diagnostic criteria can result in both false-negative and false-positive diagnoses of these 'intrauterine' ectopic pregnancies. False-negative findings cause delay in initiating appropriate management and are associated with increased maternal morbidity and mortality. False-positive diagnosis could lead to termination of a healthy, wanted pregnancy. Such events are tragic for women and their families and have serious clinical governance and medico-legal implications.

The uterine cavity is the only anatomical structure within the human body, which is able to support normal development of pregnancy until term. The surrounding uterine muscle has enough elasticity to expand and accommodate a growing pregnancy. In addition, its contractile strength is sufficient to facilitate expulsion of the foetus and placenta and to achieve immediate haemostasis following delivery. The uterine cavity is a virtual space lined by the endometrium which extends from the orifices of the Fallopian tubes at the uterine fundus to the internal cervical os. The shape of the cavity is usually triangular, but it may appear very different in cases of congenital uterine anomalies. In women with unicornuate uteri, the cavity is narrow with a single tubal orifice which is typically located at the apex of the uterine cavity.

The junctional zone or inner myometrium surrounds basal layer of the endometrium. On ultrasound scan, it appears hypoechoic and it is

**Table 1** Results survey.

Question	Statement	Strongly agree (%)	Agree (%)	Neither agree nor disagree (%)	Disagree (%)	Strongly disagree (%)
1	Ectopic pregnancy can be intrauterine or extrauterine	43.6	34.8	3.9	12.3	5.4
6	Miscarriage could be used to describe a pregnancy outside of the uterine cavity	18.6	34.3	10.3	25.0	11.8
9	Ectopic pregnancy should be described as partial or complete	19.6	37.3	23.5	15.7	3.9
12	The term 'chronic ectopic pregnancy' should be used		26.0		74.0	
2A	Intrauterine pregnancies can be correctly sited in the uterine cavity		93.6		6.4	
2B	Intrauterine pregnancies can be abnormally sited in the uterus-cervical lower section caesarean section scar, corporeal intramural pregnancies		80.9		19.1	
2C	Intrauterine pregnancies can be sited in an abnormal uterus e.g. cornual pregnancy		82.4		17.6	
7A	Interstitial ectopic pregnancy should be termed 'tubal ectopic pregnancy'		67.6		32.4	
7B	Isthmic ectopic pregnancy should be termed 'tubal ectopic pregnancy'		94.6		5.4	
7C	Ampullary ectopic pregnancy should be termed 'tubal ectopic pregnancy'		97.5		2.5	
10A	Measuring a haematosalpinx is important when measuring and reporting on ectopic pregnancy		71.6		27.0	
10B	Measuring the gestational sac is important when measuring and reporting on ectopic pregnancy		79.4		19.1	
10C	Measuring the trophoblastic mass is important when measuring and reporting on ectopic pregnancy		79.9		19.6	

particularly easy to visualise on 3D ultrasound (Votino et al., 2015). It is a useful anatomical landmark as the placental invasion should not extend beyond the endometrial–myometrial junction into the outer myometrium. In view of that, only pregnancies which are located within the uterine cavity with placental invasion not extending beyond the endometrial–myometrial junction should be considered normally implanted (Brosens et al., 2002).

#### Location

Although ectopic pregnancy is a clear and widely accepted term to describe any pregnancy outside the uterine cavity, there is no agreed single term in the medical literature to refer to a pregnancy which is normally implanted within the uterine cavity. In view of that two possible options were proposed:

- Entopic—from Ancient Greek en-, ento- ('within') + topos ('place') (medicine) in the usual place, referring to medical or anatomical objects.
- Eutopic—from Ancient Greek eu- ('good', 'well') + topos ('place') (medicine) (of an organ or other body part) being in the correct place, having a normal position (Fig. 1).

In the survey (question 3), we asked how health professionals should refer to a normally sited intrauterine pregnancy; 48% of

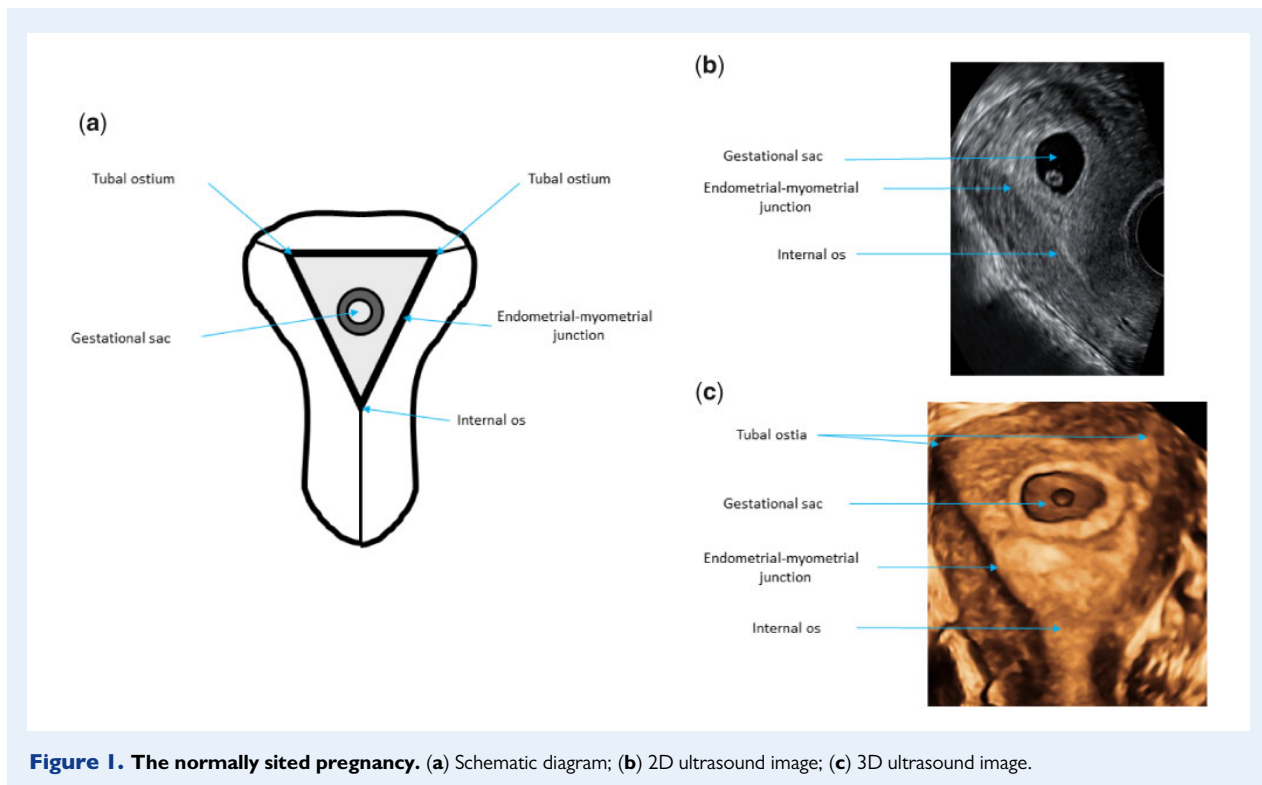
respondents indicated 'normally-sited intrauterine pregnancy'. Second and third best options were 'intrauterine pregnancy' (13%) and 'normally-sited pregnancy' (11%). Entopic (4%), eutopic (9%) and intracavity (9%) were not reported frequently.

The WG noted that only 13% of responders would like to keep the term 'intrauterine pregnancy' which suggests that we were correct in initiating this discussion. Normally sited intrauterine pregnancy was the most popular term. The term entopic pregnancy could be more appropriate as it is the antonym of ectopic. The other option would be eutopic pregnancy meaning 'being in the correct place; having a normal position'. As entopic/eutopic could lead to misinterpretation and errors, and these terms are not yet widely used, it was decided to recommend the use of 'normally-sited (eutopic) pregnancy'.

- Consensus: A pregnancy which is located within the uterine cavity should be described as a normally sited (eutopic) pregnancy.

#### Viability

**Live pregnancy.** In the survey (question 4), we asked how one should describe a normally sited intrauterine pregnancy containing an embryo or foetus with visible heart pulsations; 40% of respondents indicated 'viable', 36% indicated 'live', 15% indicated 'normal' and 9% proposed



**Figure 1.** The normally sited pregnancy. (a) Schematic diagram; (b) 2D ultrasound image; (c) 3D ultrasound image.

another term. The panel acknowledged that in obstetric practice the term viable refers to pregnancies which have advanced to the point when the foetus has a reasonable chance of surviving if born. In view of that the panel agreed that the term 'live' pregnancy would be more appropriate to describe a first-trimester pregnancy with evidence of embryonic/foetal cardiac activity. Some panel members pointed out that 'live' does not translate well in other languages and 'vital' pregnancy could be more appropriate.

There was a further discussion about terminology to describe a pregnancy when it is not yet possible to visualise an embryo with cardiac activity. Although the term 'pregnancy of uncertain viability' was used by some authors (Bottomley *et al.*, 2011), the consensus was reached to use the term 'early normally-sited (eutopic) pregnancy' instead, in order to emphasise the high probability of a good outcome in these cases.

- Consensus: A pregnancy which is located within the uterine cavity with embryonic/foetal heart pulsations should be described as a live normally sited (eutopic) pregnancy.
- Consensus: A pregnancy which is located within the uterine cavity without a visible embryo which has the potential to develop normally should be described as an early normally sited (eutopic) pregnancy.

**Miscarriage.** Miscarriage is a specific term which is widely used to describe loss of normally implanted pregnancy before completed 22 weeks' gestation confirmed by ultrasound or histology (Zegers-Hochschild *et al.*, 2017). The survey (question 6) asked whether the

term miscarriage could be used to denote both the health and location i.e. abnormal pregnancy located within the uterine cavity. Fifty-three per cent agreed or strongly agreed, 37% (strongly) disagreed and 10% neither agreed nor disagreed.

The WG decided unanimously that the term 'tubal miscarriage' should be abandoned to facilitate the use of the term miscarriage for a normally sited (eutopic) pregnancy with abnormal development resulting in embryonic/foetal loss. This abnormal development does not include foetal or genetic abnormalities. Management of miscarriage, either expectant or intervention, is not within the scope of this paper.

- Consensus: The term miscarriage should be used to describe a normally sited (eutopic) pregnancy <22 weeks' gestation with abnormal development resulting in embryonic/foetal loss.

## Ectopic pregnancy

The term ectopic pregnancy has often been considered synonymous with extrauterine pregnancy as most ectopic pregnancies are located in the Fallopian tubes. In recent years, there has been a significant increase in the number of ectopic pregnancies which are located outside the uterine cavity, but within the confines of the uterus such as caesarean scar, cervical, intramural and interstitial pregnancies. These types of ectopic pregnancies are usually caused by scarring or incomplete uterine healing following surgical trauma to the uterus during procedures such as caesarean section, myomectomy and operative hysteroscopy. The differential diagnosis between these 'non-tubal' or 'uterine' ectopic pregnancies and pregnancies implanted normally

within the uterine cavity is often difficult. Uterine ectopic pregnancies are often located partially within the myometrium and partially within the uterine cavity which makes it hard to differentiate them from normally implanted pregnancies. In addition, 'intrauterine' ectopic pregnancies tend to present initially with mild clinical symptoms and they often contain a live embryo or foetus (Timor-Tritsch et al., 2015).

#### *Live and failing ectopic pregnancy*

The WG agreed that ectopic pregnancies which contain an embryo or foetus with evidence of cardiac activity should be described as live ectopic pregnancies. They only represent a minority of ectopic pregnancies but their potential to cause harm is high and they should be described as a separate entity. In most cases embryonic or foetal cardiac activity is absent. This reflects the tendency of pregnancies to develop abnormally in ectopic locations. In some of these cases, ultrasound findings and results of blood test may indicate that ectopic pregnancy is in regression with a tendency to resolve spontaneously. The WG agreed such ectopic pregnancies should be referred to as 'failing ectopic pregnancies' if clinicians feel that the feature of abnormal development should to be emphasised to facilitate appropriate management. As discussed above the term 'tubal miscarriage' should not be used to describe these abnormally developing ectopic pregnancies.

- Consensus: An ectopic pregnancy which contains an embryo/foetus with evidence of heart pulsations should be described as a live ectopic pregnancy.
- Consensus: The term miscarriage should not be used for an ectopic pregnancy. Ectopic pregnancy with clinical, ultrasound and/or biochemical signs of regression should be described as a failing ectopic pregnancy.

#### *Location of ectopic pregnancy*

It is important that the exact location of an ectopic pregnancy is described as precisely as possible to facilitate optimal management planning. This is particularly relevant in uterine ectopic pregnancies where the exact location of the gestational sac within the uterine cavity and the degree of myometrial involvement are critical features to assist in offering women the choice between conservative and surgical management. In women diagnosed with an extrauterine ectopic pregnancy, accurate pre-operative information about the location of pregnancy helps planning of surgical intervention and minimises the risk of the ectopic pregnancy not being correctly identified at surgery.

**Uterine and extrauterine ectopics.** In the survey, we asked if the respondents agreed with the statement that ectopic pregnancies can be either inside the uterus (intrauterine) or outside of the uterus (extrauterine) (question 1). The majority of respondents agreed with this statement, with 44% strongly agreeing and 35% agreeing (Table 1). The responses showed that there was a general acceptance of the fact that ectopic pregnancies could be located within confinements of the uterus. The WG agreed that the pregnancies outside the uterus (tubal, ovarian and abdominal) should be classified as extrauterine. The pregnancies which are located within the uterus but breach the endometrial-myometrial junction and extend into the myometrium should be described as uterine ectopic pregnancies.

The WG agreed that the terms uterine and extrauterine ectopic pregnancies should replace previously used terms tubal and non-tubal ectopic pregnancies.

- Consensus: Ectopic pregnancies should be classified as uterine or extrauterine.
- Consensus: Previous classification of ectopic pregnancies as tubal and non-tubal should be abandoned.

**Angular pregnancy.** The term 'angular pregnancy' was initially defined surgically as 'implantation of the embryo just medial to the utero-tubal junction, in the lateral angle of the uterine cavity' (Jansen and Elliott, 1981). It is a poorly defined clinical entity and the term is also often used interchangeably with interstitial pregnancies. Published literature on angular pregnancies is sparse and at present, there are no agreed sonographic criteria for the condition. With advances in the use of ultrasound in early pregnancy, it has been possible to detect laterally implanted pregnancies earlier in both symptomatic and asymptomatic women. In a recent prospective study which included 42 cases, the authors found that 80% of these pregnancies resulted in a live birth and 20% in miscarriage. There were no cases of uterine rupture, maternal death, abnormal placentation or hysterectomy (Bollig and Schust, 2020). It was concluded that angular pregnancy is a variation of a normally implanted intrauterine pregnancy, rather than a form of ectopic pregnancy.

The WG agreed that angular pregnancy is not a clinical entity and it is synonymous with a pregnancy which is normally implanted in the upper lateral aspect of the uterine cavity. In view of that there was unanimous agreement that the term is not helpful and that it should be abandoned.

- Consensus: The term angular pregnancy should be abandoned.

**Partial versus complete ectopic pregnancy.** In the survey, we asked if the respondents agreed with the statement that all uterine ectopic pregnancies should be described as partial or complete to facilitate better selection for different management options (question 9). The majority of respondents agreed with the statement, with 20% strongly agreeing and 37% agreeing (see Table 1).

There was a high acceptance of the novel concept that all uterine ectopic pregnancies could be complete or partial. The WG agreed that uterine ectopic pregnancies which are completely confined to the myometrium with no visible connection with the uterine cavity should be described as complete. Those which are involving the myometrium to some extent but are also in part within the uterine cavity should be labelled as partial. Following on from this, it was agreed that interstitial ectopic pregnancies could also be classified as partial or complete. Partial interstitial pregnancies are those which are implanted within the interstitial part of the Fallopian tube, but also partially protruding through the uterine tubal ostium into the uterine cavity.

- Consensus: Cervical, caesarean scar, intramural and interstitial ectopic pregnancies should be described as partial or complete.

**Uterine ectopic pregnancies.** All uterine ectopic pregnancies are defined by evidence of trophoblast invasion beyond the endometrial-myometrial junction, but not outside the uterine visceral/broad ligament

peritoneum. Depending on the previous history and location, this can be further specified to either a scar pregnancy, cervical pregnancy or intramural pregnancy.

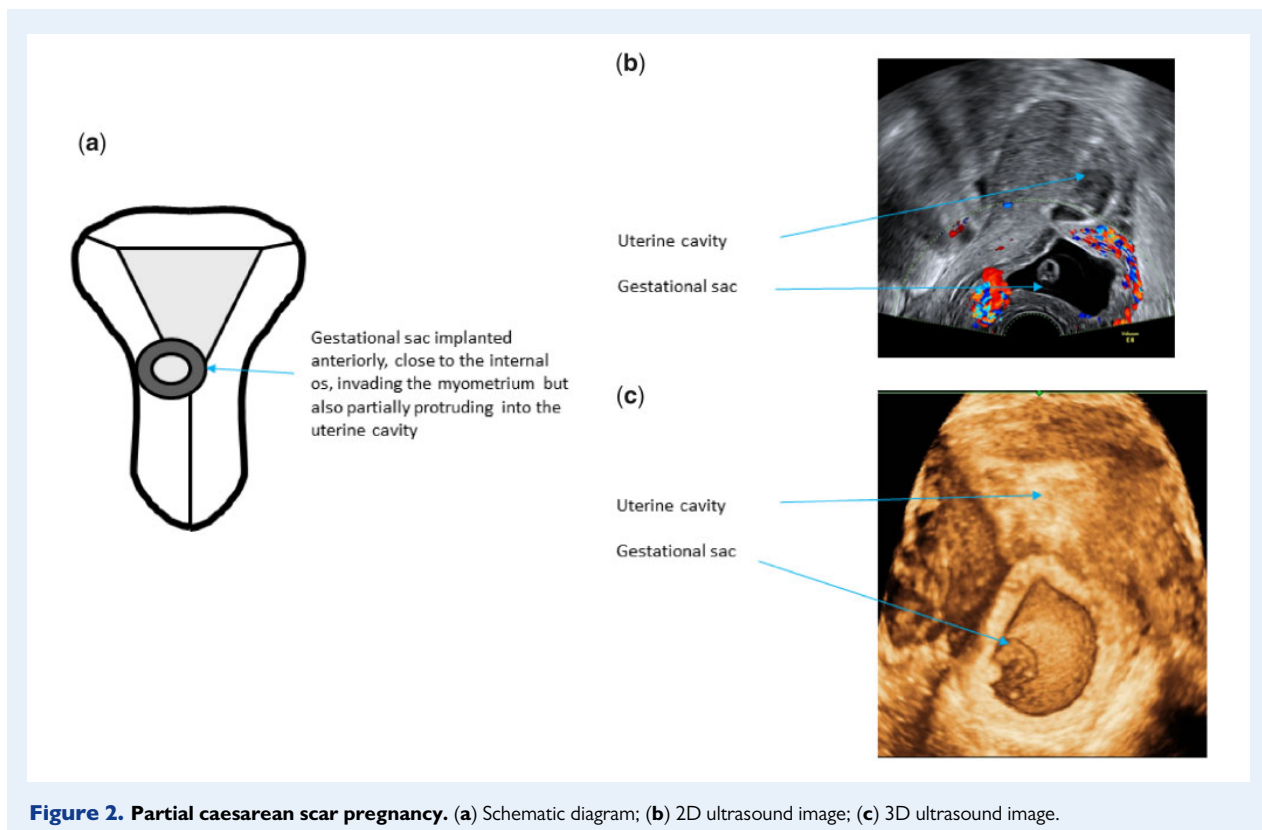
The visceral peritoneum may be breached during rupture, but this is a complication of any ectopic pregnancy and it should not be used for classification. In many uterine ectopic pregnancies, the gestational sac is only partially invading the myometrium and these cases should be described as partial scar, partial cervical or partial intramural pregnancy, regardless of the depth of invasion.

**Caesarean scar pregnancy.** A caesarean scar pregnancy is a pregnancy implanted in the transverse lower segment caesarean section scar. This generally accepted clinical entity is defined by the following features: gestational sac located low in the uterus close to the internal os and anterior implantation with trophoblast invading into the myometrium (Elson *et al.*, 2016). The internal os may be difficult to identify in women with more advanced scar pregnancies. The uterine artery reaches the uterus at the level of the internal os (Snell, 1973). The artery can be visualised on colour Doppler and it could be used as a landmark to define the level of the internal os. Colour Doppler examination is also essential to document evidence of functional placental circulation to avoid false-positive diagnoses of scar implantation (Harb *et al.*, 2018; Miller *et al.*, 2020). Most caesarean scar pregnancies are partial which facilitates their transcervical surgical evacuation (Fig. 2). Complete scar pregnancies are relatively rare, and they tend to bulge into the broad ligament or into the vesico-uterine space (Fig. 3).

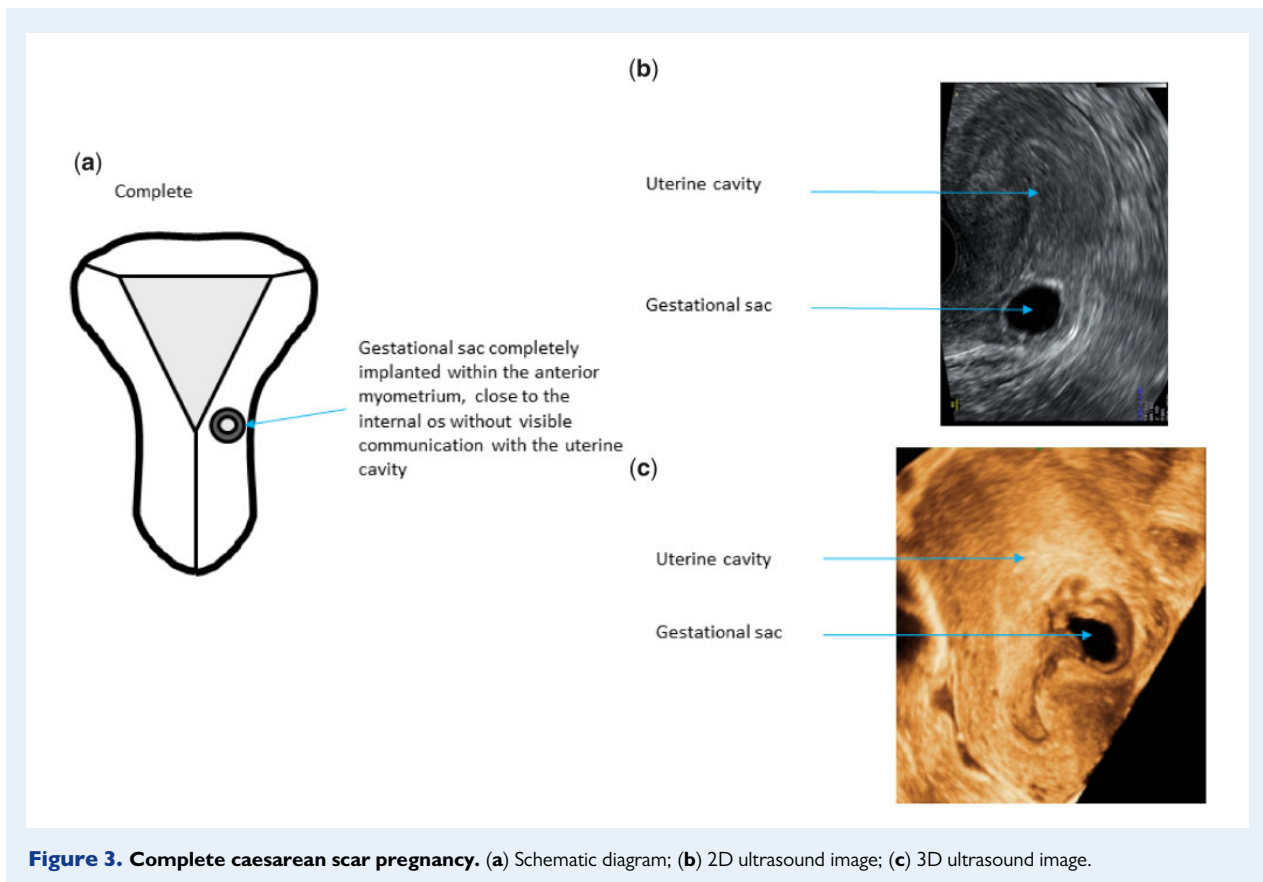
Whilst lower segment caesarean section scar pregnancies are the most common type of scar pregnancies, it is also possible for a pregnancy to implant into a uterine corporeal scar from a myomectomy or a classical caesarean section. However, the location of these pregnancies in the uterine corpus is variable and it is much harder to ascertain their link with the surgical scar site. In view of that these pregnancies should be classified as intramural pregnancies.

**Cervical pregnancy.** A cervical pregnancy is implanted into the myometrium below the level of the internal os. The following ultrasound criteria could be used for diagnosis of cervical ectopic pregnancy: a gestational sac present below the level of the internal cervical os, the absence of the 'sliding sign' and blood flow around the gestational sac using colour Doppler (Elson *et al.*, 2016). All pregnancies implanted into posterior cervix should be described as cervical ectopic pregnancies regardless of women's previous history of delivery by caesarean section. In cases of anterior implantation in women who have had a caesarean in the past, the differential diagnosis includes caesarean scar ectopic pregnancy. Cervical ectopic can also be classified as partial or complete depending on the presence or absence of their communication with the cervical canal. In terms of management, they differ very little from caesarean scar pregnancies (Figs 4 and 5).

**Intramural pregnancy.** Intramural pregnancies are relatively rare. They are located above the level of internal os which differentiates them



**Figure 2. Partial caesarean scar pregnancy.** (a) Schematic diagram; (b) 2D ultrasound image; (c) 3D ultrasound image.

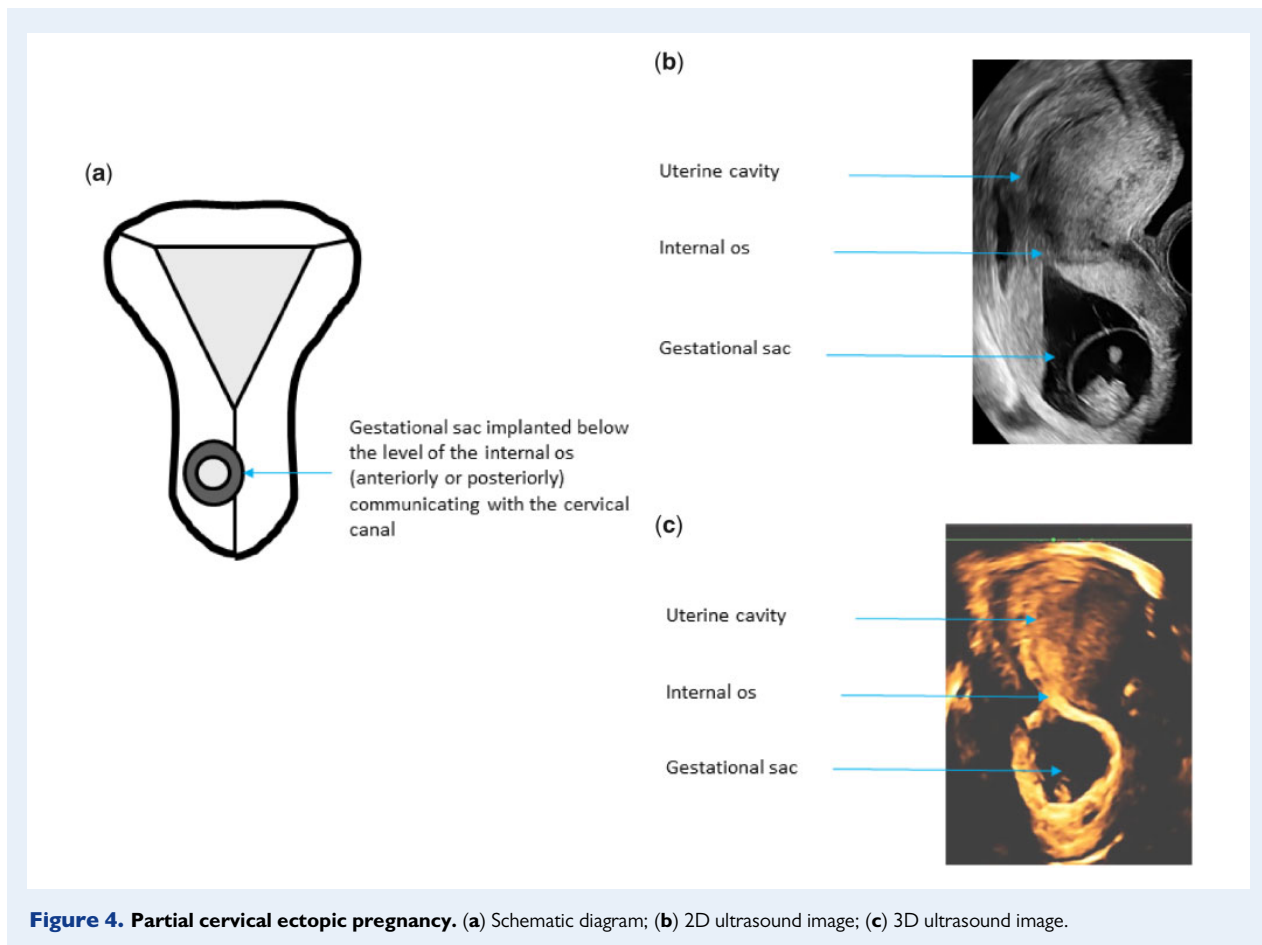


from cervical and caesarean section scar pregnancies. They typically occur after previous myomectomy, but they can also be caused by scarring following uterine perforation or after classical (upper segment vertical) caesarean section. In some cases, intramural pregnancy can develop in a focus of adenomyosis (Ginsburg et al., 1989). They do not involve the interstitial portion of the tubes which facilitate differential diagnosis from interstitial tubal pregnancies. They could be located anywhere within the uterine corpus which makes it harder to detect them compared to cervical and lower transverse caesarean section scar pregnancies. The defining feature is extension beyond the endometrial–myometrial junction above the level of the internal os. They can also be classified as complete or partial (Figs 6 and 7). Adenomyosis and cystic fibroids could sometimes resemble an empty gestational sac on B-mode ultrasound scan. In such cases, colour Doppler could be used to demonstrate increased vascularity surrounding gestational sac which is typically absent in adenomyosis and relatively sparse in fibroids (Zhang et al., 2019).

In the survey, we asked how you would describe a pregnancy which breaches endometrial–myometrial junction and invades the myometrium of the uterine corpus (question 8). The majority of respondents opted for ‘intramural pregnancy’ (57%) and 38% opted for ‘corporeal intramural pregnancy’.

The WG agreed in principle on the descriptions and sub-classifications of caesarean scar and cervical pregnancies. It was acknowledged during discussion that there is no clear international consensus on the criteria to diagnose caesarean scar ectopic pregnancies and the WG opted to follow the guidelines on the diagnosis and management of ectopic pregnancy issued by the Royal College of Obstetricians and Gynaecologists (Elson et al., 2016). Pregnancies invading the myometrium above the internal os are relatively rare and they are not covered by any major guidelines. The WG discussed the potential merits of using the term ‘corporeal intramural pregnancy’ versus ‘intramural pregnancy’. Although the term ‘corporeal intramural pregnancy’ is more specific, the majority of the WG members felt that it would be better to adopt the term ‘intramural pregnancy’ bearing in mind the results of the survey which strongly favoured the second option.

- Consensus: The term intramural pregnancy should be used to describe a pregnancy which is located within the uterus, but breaches the endometrial–myometrial junction and invades the myometrium of the uterine corpus above the internal os.
- Consensus: The terms caesarean scar and cervical pregnancies should be used to describe pregnancies which invade myometrium in the vicinity or below the level of the internal os. Caesarean scar



**Figure 4. Partial cervical ectopic pregnancy.** (a) Schematic diagram; (b) 2D ultrasound image; (c) 3D ultrasound image.

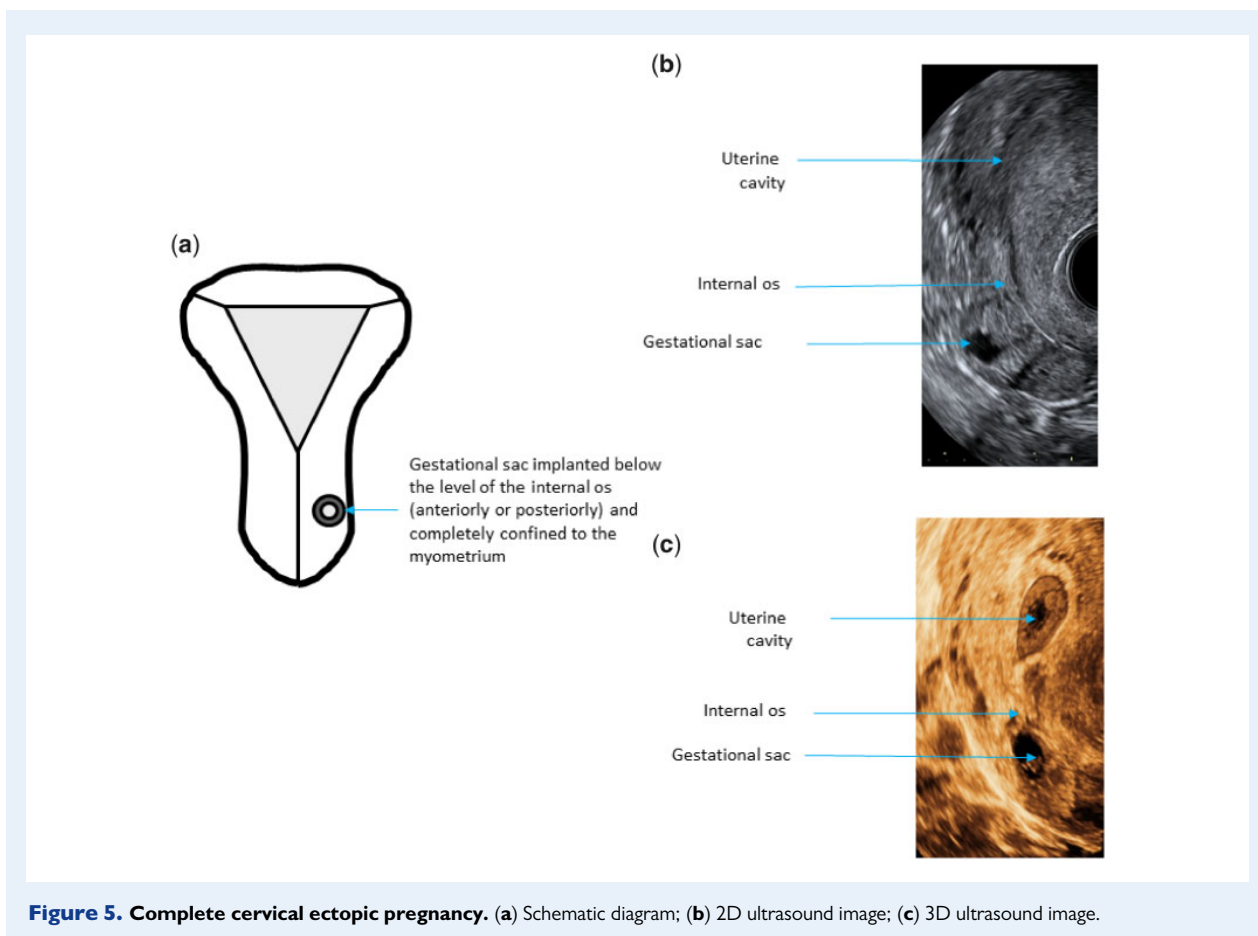
pregnancies are implanted anteriorly at the visible or presumed site of transverse lower segment uterine scar, whilst cervical pregnancies could be located either anteriorly or posteriorly.

**Extrauterine ectopic pregnancies.** Tubal ectopic pregnancy. Anatomically, the Fallopian tube is a hollow structure which extends from the uterine tubal orifice to the lateral opening at the fimbrial end. A gestational sac can implant in any part of the Fallopian tube. Depending on their location, tubal ectopic pregnancies can be divided into interstitial, isthmic, ampullary. Fimbrial ectopic has also been described, but they can only be diagnosed at surgery and on ultrasound scan they are indistinguishable from ampullary ectopic pregnancies (Kayatas *et al.*, 2014). The management of ampullary and fimbrial ectopic pregnancies is essentially the same and therefore the panel has decided to retain only ampullary tubal ectopic in the classification. Tubal pregnancies located closer to the uterus have a higher potential to grow larger and to contain a live embryo/foetus which increases the risk of serious complications. In view of this, interstitial ectopic pregnancies used to be seen as a separate entity to more distal isthmic and ampullary ectopic pregnancies. However, improvements in ultrasound diagnosis and surgical management make this approach obsolete and we propose that all pregnancies located within the Fallopian tube should be classified as tubal ectopic pregnancies. In addition, as they develop, most interstitial

pregnancies tend to grow laterally into the proximal segment of the tube and ectopic pregnancies which are confined to the interstitial segment of the tube only are relatively rare. A critical diagnostic feature of interstitial ectopic pregnancies is visualisation of a thin intramural/interstitial segment of Fallopian tube adjoining the medial aspect of the gestational sac and the lateral aspect of the uterine cavity, often referred to as the interstitial line sign (Ackerman *et al.*, 1993) (Fig. 8). In addition, the gestational sac has to be at least partially enveloped by the myometrium.

Interstitial pregnancies that are confined to the interstitial tube tend to be relatively small and they are difficult to detect at laparoscopy. Most interstitial pregnancies expand into the isthmic part of the Fallopian tube which makes it easier to identify them and treat at surgery. In rare cases, interstitial pregnancies spread out medially and eventually start to protrude into the upper lateral aspect of the uterine cavity. These partial interstitial pregnancies are often very hard to differentiate from laterally implanted normally sited (eutopic) pregnancies (Fig. 9).

A pregnancy close to the uterus but not surrounded by myometrium could be described as isthmic (Fig. 10) whilst the pregnancy located further away and close to the ovary could be labelled as ampullary tubal ectopic (Fig. 11).



**Figure 5. Complete cervical ectopic pregnancy.** (a) Schematic diagram; (b) 2D ultrasound image; (c) 3D ultrasound image.

In the survey, we asked if the respondents agreed with the statement that interstitial ectopic pregnancies, isthmic ectopic pregnancies and ampullary ectopic pregnancies should all be termed tubal ectopic pregnancy (question 7). The majority of respondents (>60%) agreed with all three statements (Table I).

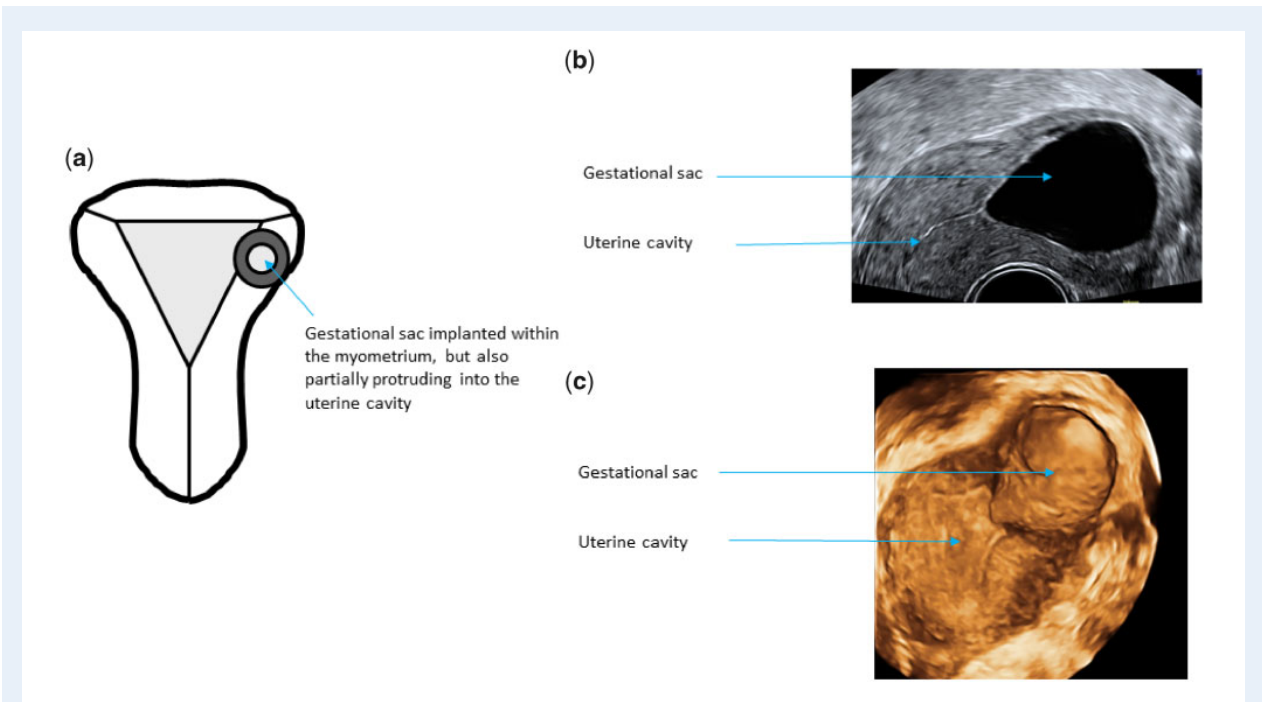
The WG noted that there may be some concern about re-classifying interstitial ectopic as tubal as this is a departure from current clinical practice. However, during discussion, it was very clear that all WG members favoured this change as it is more logical taking into account anatomical structure of the Fallopian tube. There was a consensus that re-classification of interstitial pregnancy would facilitate more conservative surgical approach to treat this type of ectopic pregnancy and discourage surgeons from performing uterine wedge resection which is associated with an increased risk of both intra- and post-operative complications (Liao et al., 2017).

- Consensus: Tubal ectopic pregnancies should be described as either interstitial, isthmic or ampullary.

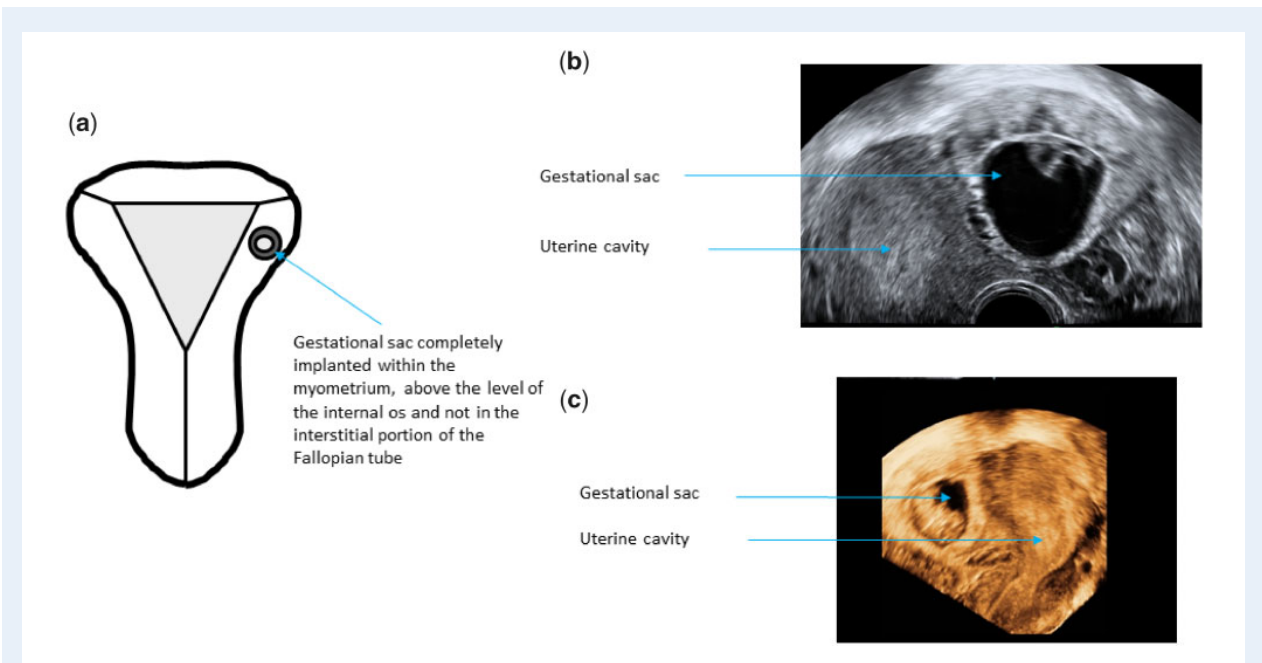
**Ovarian pregnancy.** An ovarian pregnancy is located completely or partially within the ovarian parenchyma. In the majority of cases, ovarian

pregnancy is ipsilateral to the corpus luteum (Dooley et al., 2019). The key diagnostic feature is the inability to separate the pregnancy from the ovary on palpation with the ultrasound probe during the examination. However, this finding is not entirely specific as it may also be present in tubal pregnancies which are firmly adhered to the uterus or ovary. Small ovarian pregnancies are easier to diagnose correctly than larger or ruptured pregnancies (Comstock et al., 2005). However, some very small ovarian pregnancies with no embryo or a yolk sac may resemble a corpus luteum. Although, trophoblastic tissue tends to be more echogenic than corpus luteum these differences are not always obvious. In view of that, it is important to utilise colour Doppler in suspected ovarian pregnancies which facilitates detection of corpus luteum and demonstration of another area of increased vascularity within the ovary representing peri-trophoblastic blood flow of an ovarian ectopic (Fig. 12).

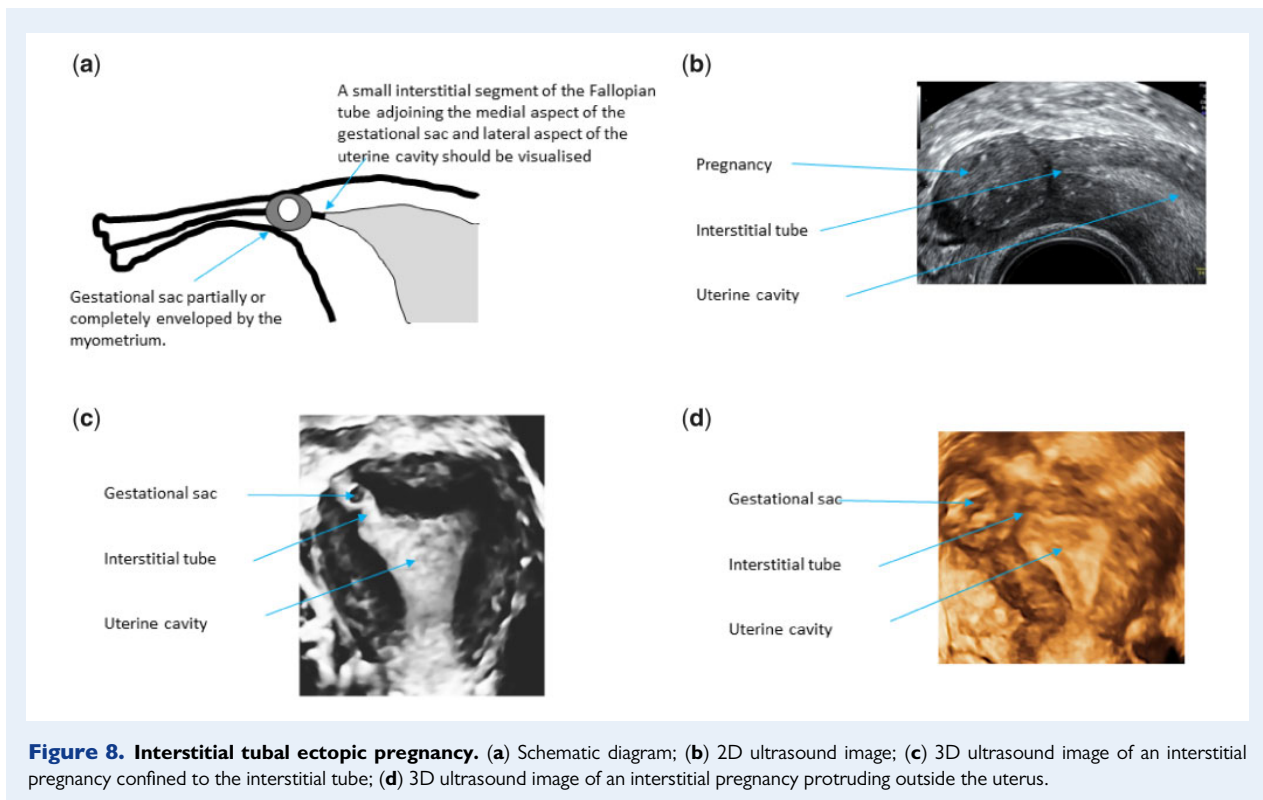
**Abdominal pregnancy.** An abdominal pregnancy results from implantation in the peritoneal cavity, outside of the uterus, ovaries and Fallopian tubes. In a primary abdominal pregnancy, the original site of implantation is the peritoneal cavity. Secondary abdominal pregnancies are the result of tubal rupture or expulsion of pregnancy through the



**Figure 6. Partial intramural ectopic pregnancy.** (a) Schematic diagram; (b) 2D ultrasound image; (c) 3D ultrasound image.



**Figure 7. Complete intramural ectopic pregnancy.** (a) Schematic diagram; (b) 2D ultrasound image; (c) 3D ultrasound image.



fimbrial end of the tube and its re-implantation into the abdominal cavity. The most common sites for implantation are the broad ligament, pouch of Douglas, uterovesical pouch and surfaces of the tubes and uterus (Poole et al., 2012). Early abdominal pregnancies are often difficult to diagnose. There will be usually an empty uterine cavity and no evidence of a dilated Fallopian tube or an adnexal mass (Elson et al., 2016). The diagnosis should be suspected if a gestational sac is seen in an unusual location such as the pouch of Douglas or vesico-uterine pouch or if surrounded by loops of bowel (Fig. 13). Doppler examination is helpful to confirm the presence of peri-trophoblastic blood flow.

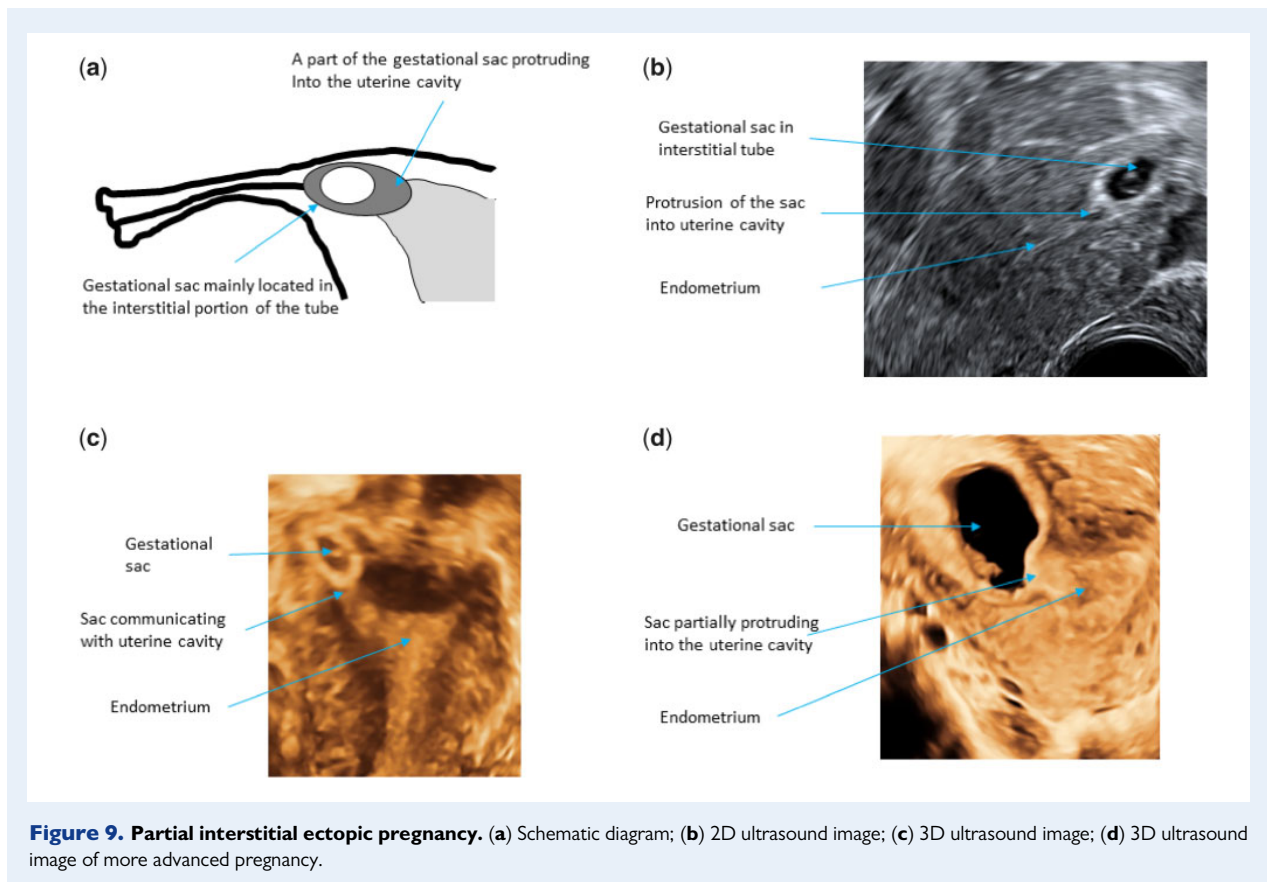
**Rudimentary horn pregnancy.** This term refers to a pregnancy in the rudimentary horn of a unicornuate uterus. The Royal College of Obstetricians and Gynaecologists classifies this pregnancy as 'cornual pregnancy'. However, as mentioned previously, the term cornual pregnancy has been used in clinical practice to describe pregnancies in various locations, both normally sited and ectopics, and we decided to abandon this term as suggested by Baltarowich (2017). Rudimentary horn pregnancy is rare, with a reported incidence of 1 in 75 000–150 000 pregnancies (Tesemma, 2019). If not diagnosed in early pregnancy, they can advance well into the second trimester, when they often present with severe pain and rupture (Jayasinghe et al., 2005; Li et al., 2019). The following ultrasound scan criteria should be used for the diagnosis of a rudimentary horn pregnancy: visualisation of a single interstitial portion of Fallopian tube in the main unicornuate uterine body, gestational sac/products of conception seen mobile and separate from the unicornuate cavity and completely surrounded by

myometrium, and a vascular pedicle adjoining the gestational sac to the unicornuate uterus (Elson et al., 2016) (Fig. 14).

However, the diagnosis may be more difficult when two uterine cornua are fused and the outer uterine contour is normal (Robert's uterus). In these cases, the only way to reach the correct diagnosis is by demonstrating the lack of communication between the blind rudimentary cornu containing the gestational sac and the cervical canal (Fig. 15). The diagnosis of a pregnancy in a communicating rudimentary cornu of unicornuate uterus is particularly difficult without a prior knowledge of the presence of congenital uterine anomaly. The rudimentary cornu containing pregnancy enlarges rapidly which makes it often impossible to differentiate this anomaly from bicornuate or septate uterus.

In the survey, we asked if the respondents agreed with the statement that intrauterine pregnancies can be either sited in an abnormal uterus, abnormally sited in the uterine cavity or correctly sited in the uterus. Most respondents (>80%) agreed with all three statements.

Several WG members expressed concerns about the wording of this question in particular to the second part which indicates that some pregnancies which are located within the uterine cavity could be classified as abnormally sited. Some WG members stated that pregnancies which are located low in the uterine cavity could be described as precursors of placenta praevia. However, it was concluded that all pregnancies within the confines of the uterine cavity should be classified as normally sited. After discussion, the panel unanimously agreed that pregnancies which are located within the confines of the uterine cavity should be described as normally sited with the exception of rudimentary horn pregnancy which is located in an abnormally formed



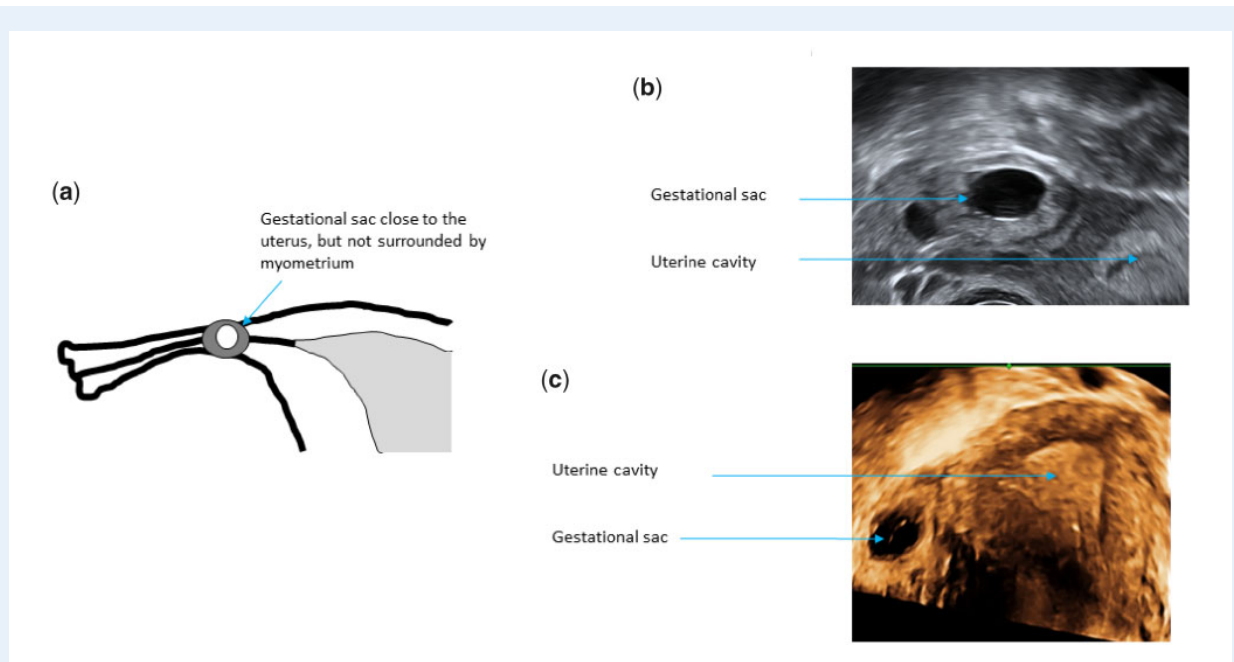
uterus. Pregnancies in other types of anomalous uteri such as septate, bicornuate, didelphys and other when the pregnancy is not located in the rudimentary horn should not be classified as ectopic pregnancies as long as they do not breach the endometrial–myometrial junction.

- Consensus: All pregnancies within the confines of the uterine cavity should be classified as normally sited regardless whether the uterus is normally formed or anomalous. The only exception is a pregnancy located in a rudimentary horn of a unicornuate uterus which should be classified as a rudimentary horn ectopic pregnancy.

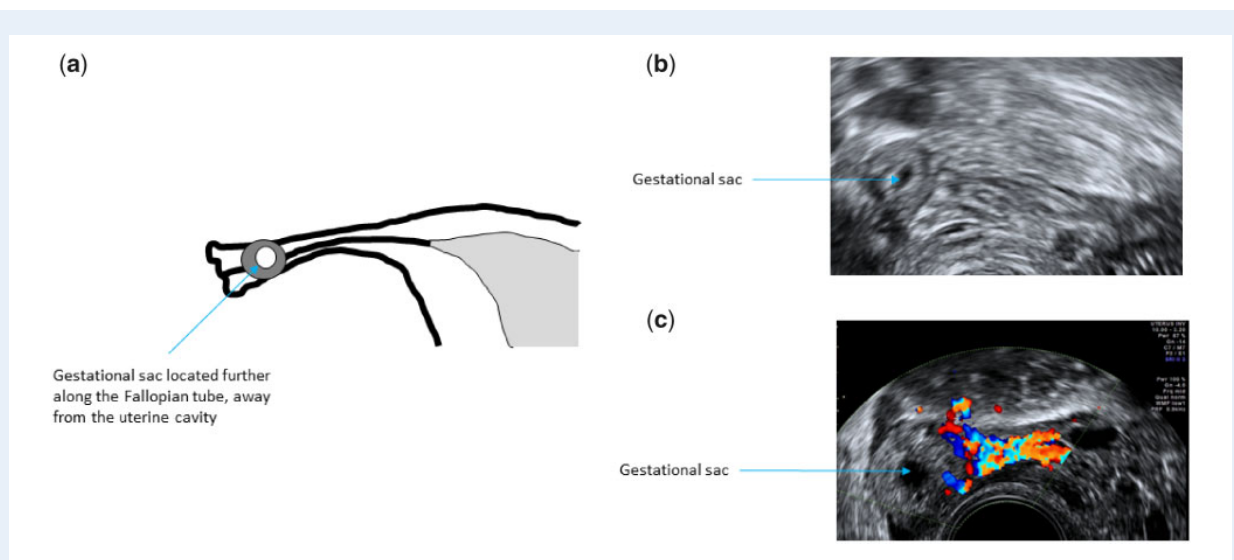
**Residual ectopic pregnancy.** An ectopic pregnancy can remain visible also after decline of serum hCG to pre-pregnancy levels. On ultrasound scan, they initially appear hyperechoic, but with time they tend to turn into more solid, hypoechoic lesions which are poorly vascularised on Doppler examination. In the survey, we asked if the term ‘chronic ectopic pregnancy’ should be used in clinical practice and in which situations this term could be used (questions 12 and 13). There was a strong rejection of the term ‘chronic ectopic’ although it is used regularly in clinical practice (Tempfer *et al.*, 2019), and also the survey showed it was used for different purposes. There were also articulate concerns about the use of term chronic, possibly relating to an ongoing, incurable condition.

The WG agreed to discard the term ‘chronic’ and discussed some alternatives, including non-active, partially resolved, non-functional, remnant and persistent. In the end, it was decided to choose residual ectopic pregnancy, taking into consideration clarity, acceptability to patients and clinicians and the possibility to use it in different languages. The term is to be used to describe an ectopic pregnancy which presents as a discrete mass on ultrasound in women with a negative pregnancy test (Fig. 16). This is usually an incidental finding in women attending for ultrasound scans for other indications. Women are often unaware of being pregnant prior to the examination. A recent study showed that 95% of conservatively managed tubal ectopic pregnancies became undetectable on ultrasound scan 3 months after return of serum hCG to pre-pregnancy levels (Dooley *et al.*, 2020). In view of that the term residual ectopic pregnancy could also be used when conservatively managed ectopic pregnancy remains visible on ultrasound scan longer than 3 months after urine pregnancy test turns negative or after serum hCG declines to <20 IU/l.

- Consensus: The term ‘residual ectopic pregnancy’ should be used for an ectopic pregnancy which presents as a discrete mass on ultrasound in a woman with a negative pregnancy test.
- Consensus: The term ‘chronic ectopic’ should not be used in clinical practice.



**Figure 10. Isthmic tubal ectopic pregnancy.** (a) Schematic diagram; (b) 2D ultrasound image; (c) 3D ultrasound image.



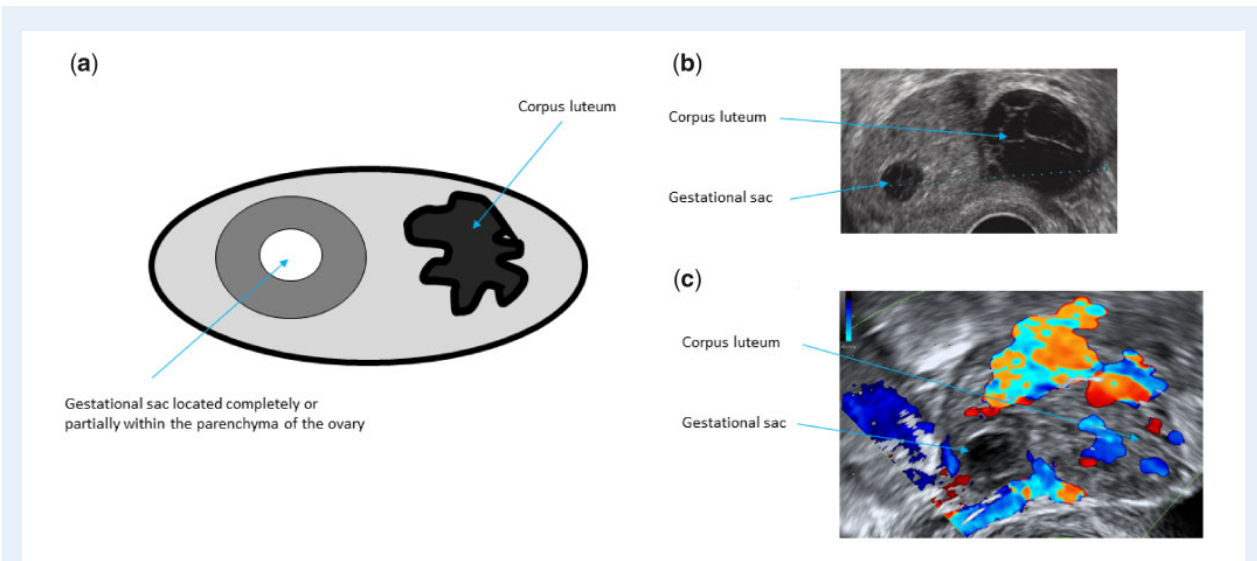
**Figure 11. Ampullary tubal ectopic pregnancy.** (a) Schematic diagram; (b) 2D ultrasound image; (c) colour Doppler ultrasound image.

#### Qualitative and quantitative descriptions of ectopic pregnancy

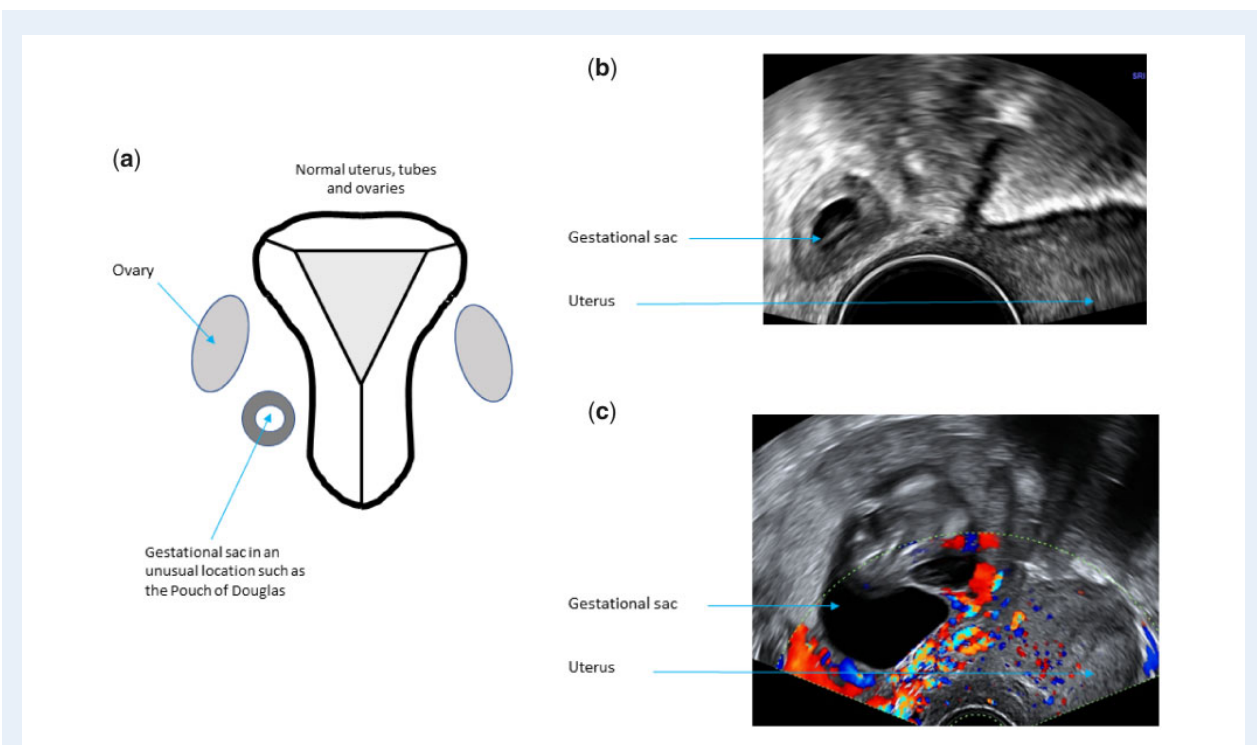
**Morphology of ectopic pregnancy.** After identifying the location of a pregnancy, wherever the site, it is essential to comment on the morphology. As is routine with intrauterine pregnancies, it is important to document whether there is a gestational sac present and if there is a yolk sac or

foetal pole with or without cardiac activity within the sac. In the case of an ectopic pregnancy, there may also be just a solid swelling. Figure 17 shows how the morphology of an ectopic pregnancy may be evaluated.

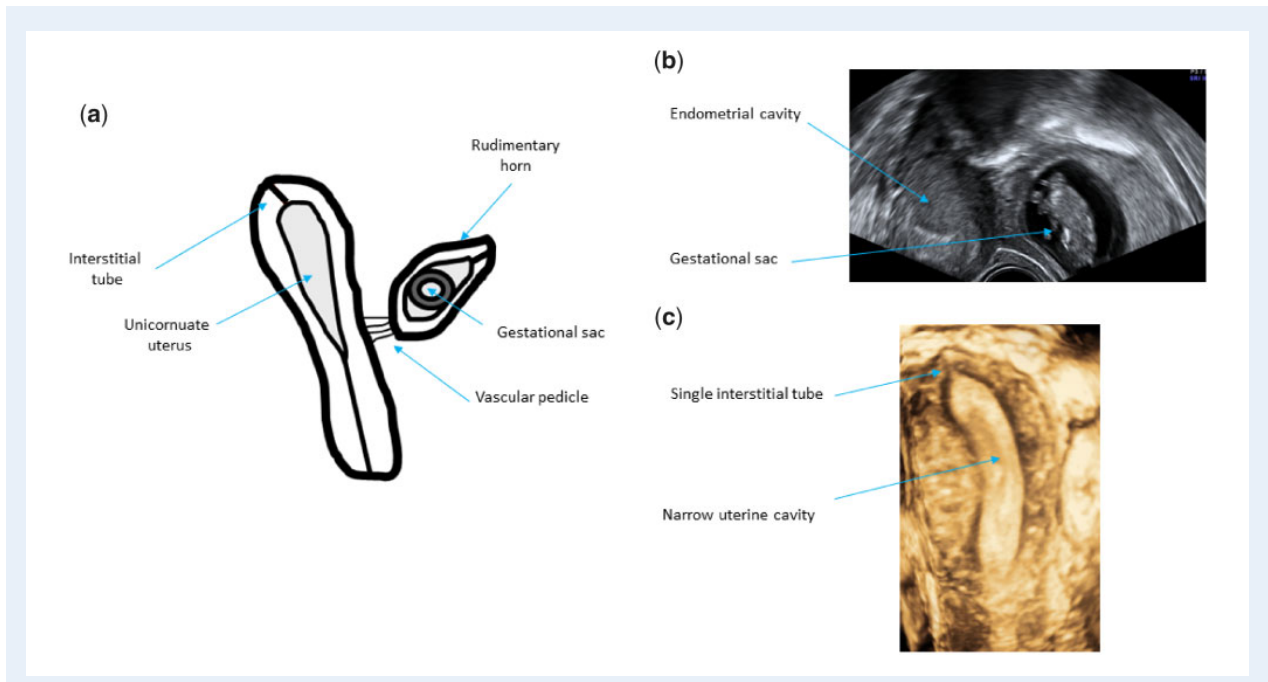
Further assessment on the clinical aspects is to be considered, but this is outside the scope of this terminology paper.



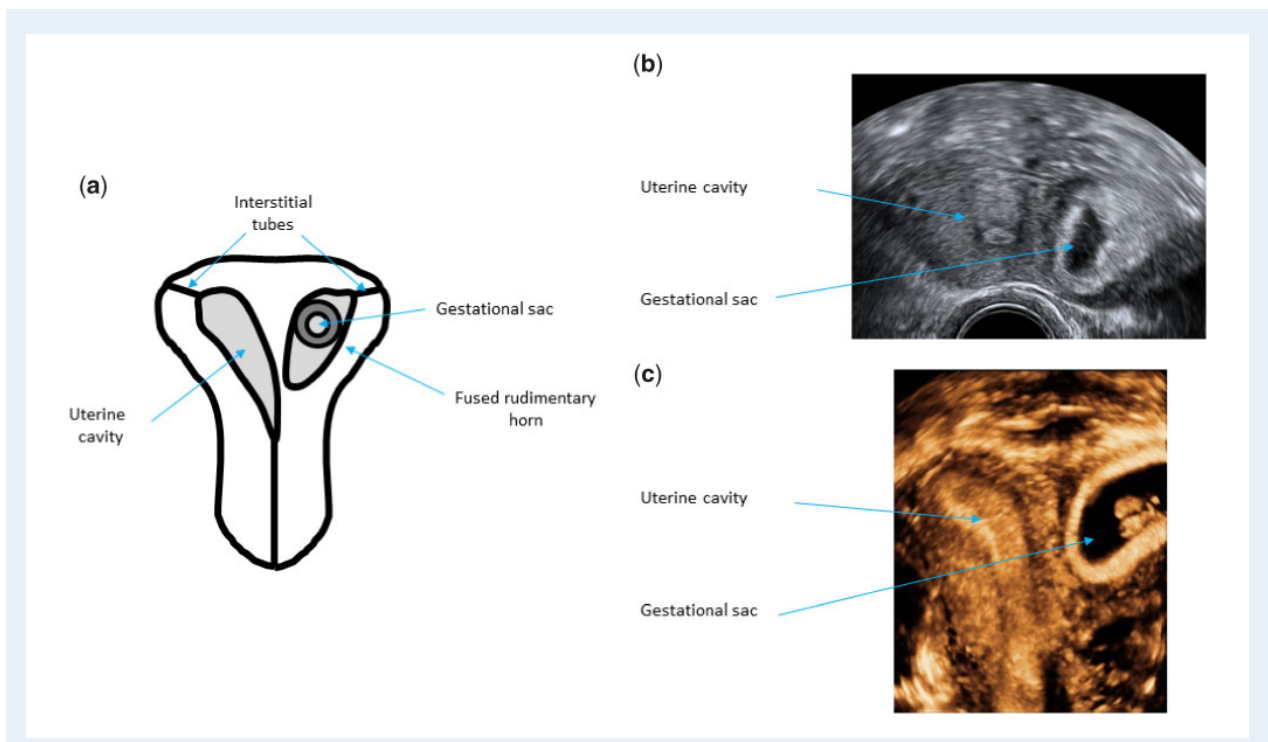
**Figure 12. Ovarian ectopic pregnancy.** (a) Schematic diagram; (b) 2D ultrasound image; (c) colour Doppler ultrasound image.



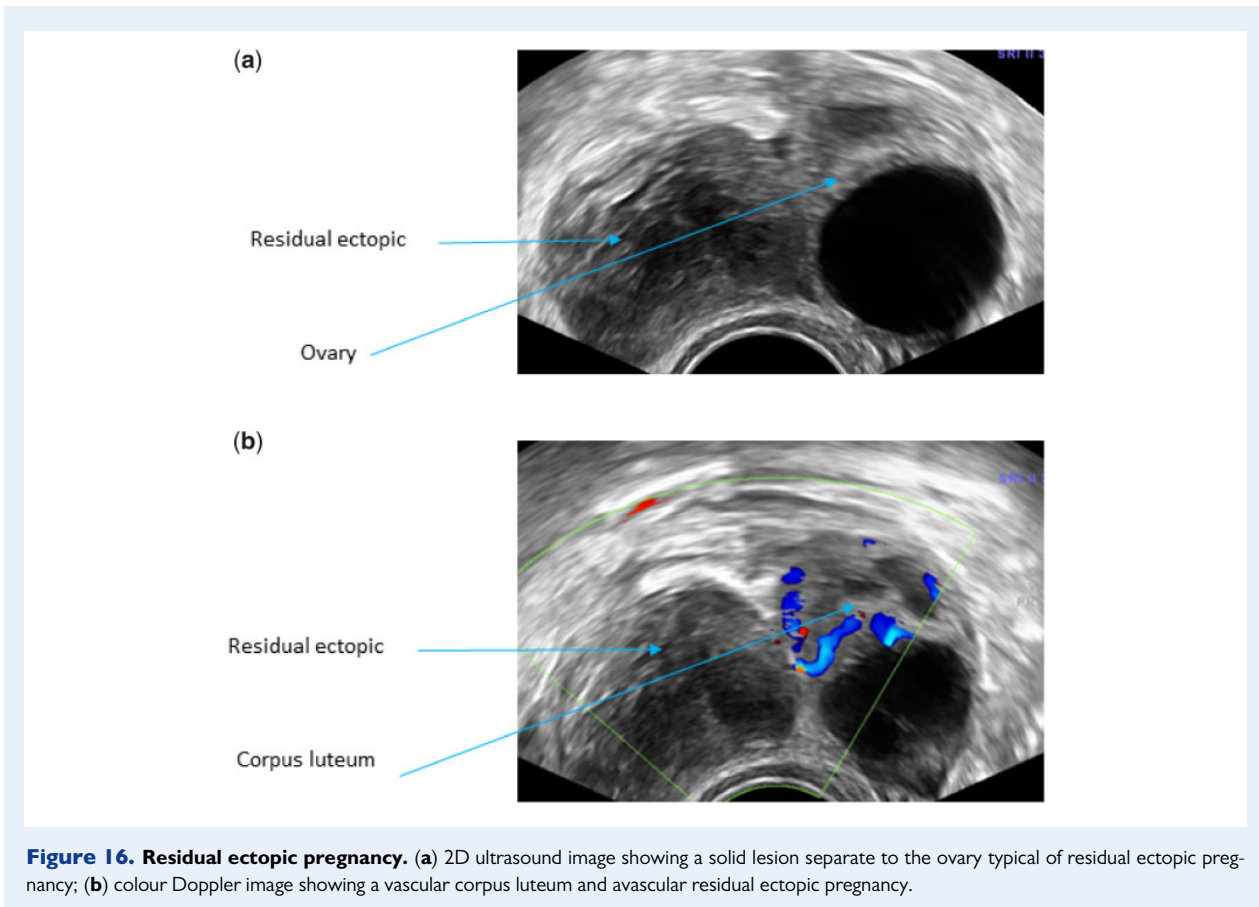
**Figure 13. Abdominal ectopic pregnancy.** (a) Schematic diagram; (b) 2D ultrasound image; (c) colour Doppler ultrasound image.



**Figure 14.** Rudimentary horn ectopic pregnancy in separate non-communicating rudimentary cornu. (a) Schematic diagram; (b) 2D ultrasound image; (c) 3D ultrasound image of unicornuate uterus.



**Figure 15.** Rudimentary horn ectopic pregnancy in fused non-communicating rudimentary horn. (a) Schematic diagram; (b) 2D ultrasound image; (c) 3D ultrasound image.



**Figure 16. Residual ectopic pregnancy.** (a) 2D ultrasound image showing a solid lesion separate to the ovary typical of residual ectopic pregnancy; (b) colour Doppler image showing a vascular corpus luteum and avascular residual ectopic pregnancy.

**Measuring an ectopic pregnancy.** Ectopic pregnancies should also be measured in three perpendicular planes using the following protocol (Fig. 18):

- (1) the outer to outer margins of the trophoblast should be measured in all cases to include the full size of trophoblastic tissue
- (2) in ectopic pregnancies presenting with a well-defined gestational sac, the inner to inner margins of the coelomic cavity should also be measured in a manner similar to the measurement of 'gestational sac' size in normally implanted pregnancies and
- (3) in women with evidence of haematosalpinx, the measurements should be taken between the inner margins of the Fallopian tube distended with blood. This technique ensures better correlation between the pre-operative ultrasound and surgical findings.

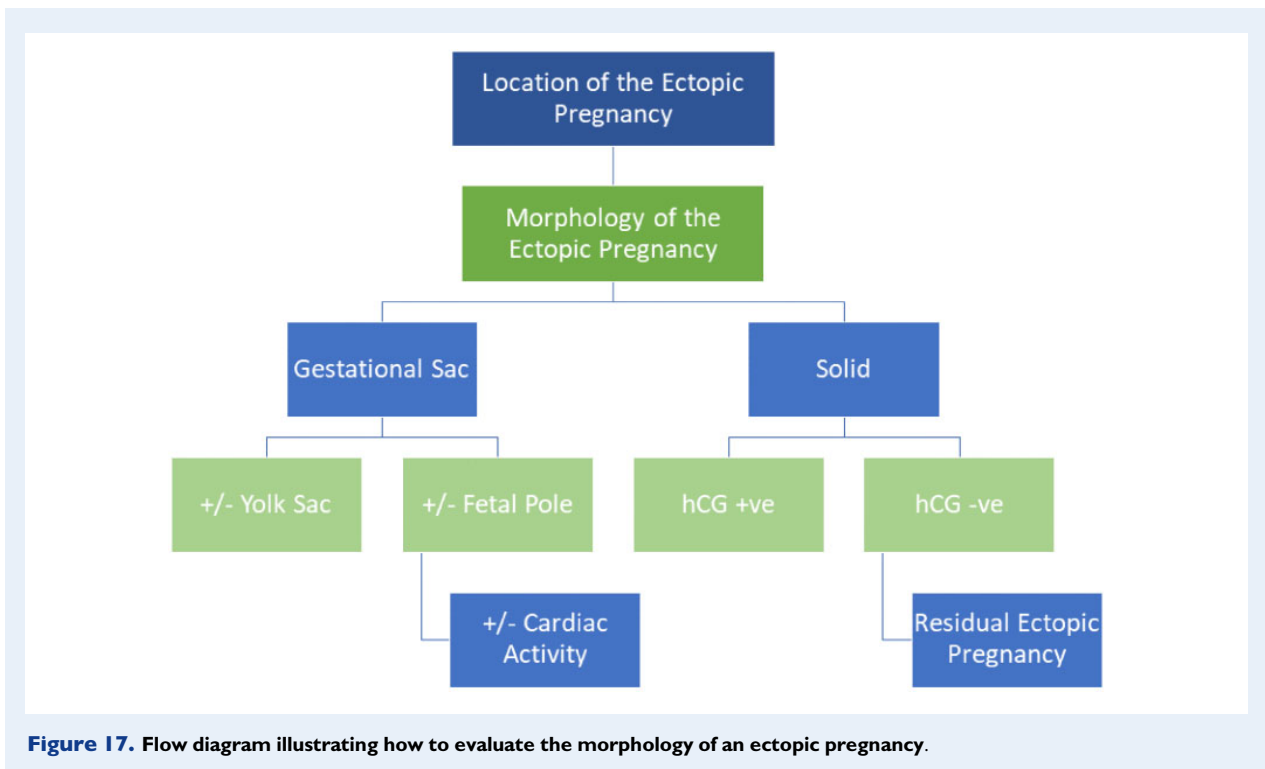
The measurements of all three planes should be reported and the mean diameter may be calculated. The size of the gestational sac in normally sited pregnancies is usually measured from the inner sac wall/chorionic fluid interface which corresponds to the size of coelomic cavity in early and the amniotic cavity in later pregnancies.

In many ectopic pregnancies, the size of the coelomic cavity is very small in comparison to the size of trophoblastic ring or haematosalpinx. This may encourage inappropriate use of conservative

management and in some cases create an impression of discordance between pre-operative ultrasound and surgical findings (Rajah *et al.*, 2018).

The exact amount blood in the pelvis is difficult to measure on ultrasound (Fauconnier *et al.*, 2007). Haemoperitoneum should be categorised semi-quantitatively as mild, when there is only echogenic fluid present in the pouch of Douglas, moderate when there are visible blood clots and severe when there were blood clots and echogenic fluid present both in the pouch of Douglas and in the utero-vesical space (Fig. 19). Presence of blood in the Morrison's pouch (hepato-renal space) is also an indication of severe intra-abdominal bleeding (Bignardi and Condous, 2009). The assessment of haemoperitoneum may be more difficult in women with ovarian hyperstimulation syndrome due the increased amount of free fluid in the peritoneal cavity. This may also have a dilutional effect preventing the formation of blood clots.

In the survey, we asked whether it is important to measure haematosalpinx, gestational sac and trophoblastic mass in three dimensions for the measuring and reporting of ectopic pregnancies (question 10). The majority of respondents (>70%) agreed with all three parameters (Table I). The responses show a clear acceptance of the need to carry out all possible measurements in cases of ectopic pregnancy including



the size of haematosalpinx in tubal ectopic pregnancies. The WG concurred.

- Consensus: In all ectopic pregnancies, measurements of the gestational sac size and trophoblastic mass should be routinely carried out. In tubal ectopic pregnancies, the size of haematosalpinx should be reported when present. All measurements should be performed in three perpendicular planes. The haemoperitoneum should be estimated semi-quantitatively.

## Discussion

Our recommendations for good practice provide a comprehensive classification system to describe location and morphological characteristics of both normally sited and all types of ectopic pregnancies (Fig. 20). One of the main challenges in modern clinical practice is detection and timely treatment of ectopic pregnancies developing outside the uterine cavity, but within the confines of the uterus. This is a relatively novel problem which has been caused by a rapid increase in the proportion of women having caesarean sections and other conservative surgical procedures on the uterus. Although discussions about the diagnostic criteria, clinical significance and optimal management strategies of uterine ectopic pregnancies, and in particular caesarean scar ectopic pregnancies are still ongoing (Vial et al., 2000; Harb et al., 2018; Miller et al., 2020), we believe that our classification will be of help to clinicians who are already facing daily challenges to determine whether pregnancies they are assessing are located normally within the uterine

cavity or not. The consequences of making the wrong diagnosis can be serious resulting in maternal and foetal adverse outcomes with significant medico-legal ramifications.

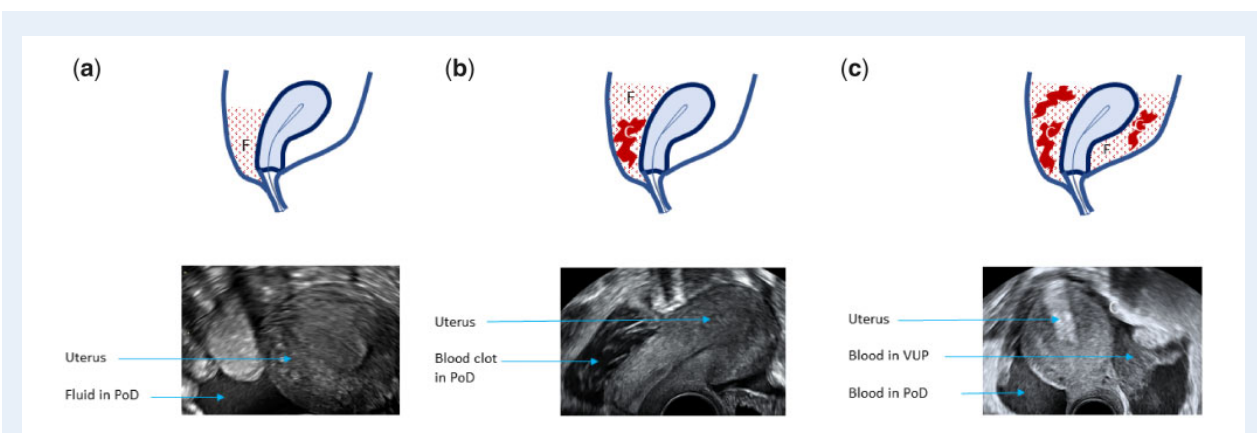
Our classification divides uterine ectopic pregnancies in partial or complete depending on their location within the myometrium. This is a novel approach which has been welcomed by those who contributed to the development of this document as it recognises for the first time that ectopic pregnancies often cross various anatomical landmarks. Accurate description of their location is of fundamental importance when offering women choice between different management options.

We have also for the first time proposed a standardised approach for assessing the size of ectopic pregnancies. This fills an important gap in current clinical practice and research. Many protocols for conservative management of ectopic pregnancy refer to the pregnancy size, but none of studies offers any information about the measurement technique to determine the size of ectopic pregnancy. If adopted in clinical practice, our approach would ensure that the results of future clinical trials are reported in a uniform way which would make it easier to compare the results of different studies and help to refine clinical protocols for the management of ectopic pregnancy.

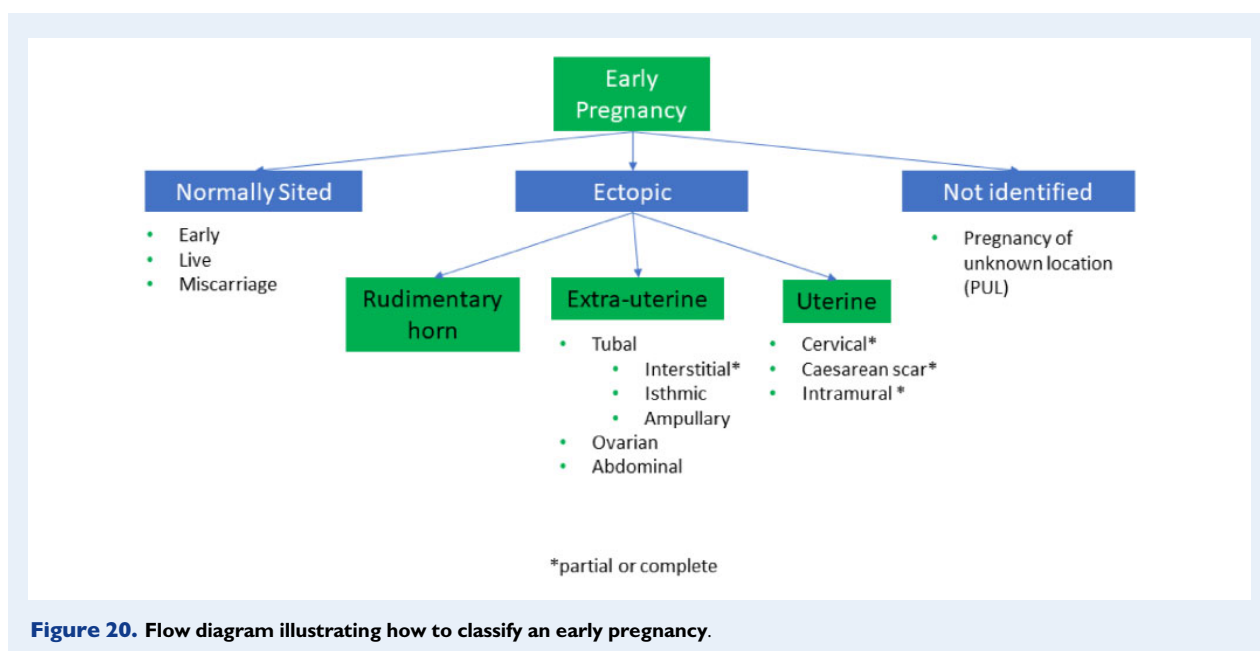
We are fully aware that adoption and implementation of our classification requires a level of expertise in early pregnancy ultrasound which may not be readily available in every diagnostic or early pregnancy unit. However, the adoption of this classification would be an important step towards increasing the awareness of uterine ectopic pregnancies and improving training of clinicians who provide early pregnancy care. The problem of uterine ectopic pregnancies is unlikely to go away and, if anything, will become more pressing in the future. Until

Morphology of the ectopic pregnancy	Transverse plane (measurements in mm)	Longitudinal plane (measurements in mm)
<p><b>Solid Swelling</b></p> <p>Shown in blue Measure outer diameter (from outside to outside)</p>		
<p><b>Gestational sac</b></p> <p>Shown in white Measure size of sac from inner diameter to inner diameter and size of overall swelling as above <math>\pm</math> yolk sac <math>\pm</math> fetal pole.</p>	 	 
<p><b>Haematosalpinx</b></p> <p>Shown in grey Measure haematosalpinx diameter from inside to inside, plus size of solid swelling within the tube <math>\pm</math> sac <math>\pm</math> yolk sac <math>\pm</math> fetal pole.</p>		

**Figure 18.** How to measure an ectopic pregnancy on ultrasound scan.



**Figure 19.** Semi-quantitative grading of haemoperitoneum. (a) Mild; (b) moderate; (c) severe. F, fluid; C, blood clot; PoD, pouch of Douglas; VUP, vesico-uterine pouch.



general standards of early pregnancy scanning are improved significantly, ESHRE and other professional bodies should encourage closer collaboration between clinicians working in different regions as well as internationally. This could be facilitated by identifying centres of expertise which would provide colleagues working in other distant units with advice regarding the diagnosis and management of complex and rare types of ectopic pregnancies. Using internet and other means of modern communication it is relatively easy for clinicians to exchange static and live images of sufficient quality to enable experts reaching a correct diagnosis without the need for women to travel long distances.

The best measure of quality of any classification is the level of uptake in clinical practice and we hope that the approach proposed in the document will be widely adopted. Feedback from women, sonographers and clinicians will help to ensure that future revisions of this document respond even better to their needs.

## Supplementary data

Supplementary data are available at *Human Reproduction Open* online.

## Acknowledgements

The authors would like to thank everyone who contributed to the stakeholder review for the constructive remarks that improved the quality of the paper. The list of stakeholder reviewers is available in Supplementary Table S11.

## Authors' roles

E.K. and D.J. chaired the working group and drafted the content. All authors contributed equally in discussing the recommendations until

consensus. N.L.C. provided methodological and organisational support. All authors approved the final version.

## Funding

The meetings of the working group were funded by the European Society of Human Reproduction and Embryology.

## Conflict of interest

T.T. declares speakers' fees from GE Healthcare. The other authors declare that they have no conflict of interest.

## References

- Ackerman TE, Levi CS, Dashefsky SM, Holt SC, Lindsay DJ. Interstitial line: sonographic finding in interstitial (cornual) ectopic pregnancy. *Radiology* 1993;**189**:83–87.
- Baltarowich OH. The term “cornual pregnancy” should be abandoned. *J Ultrasound Med* 2017;**36**:1081–1087.
- Bignardi T, Condous G. Does tubal ectopic pregnancy with hemoperitoneum always require surgery? *Ultrasound Obstet Gynecol* 2009;**33**:711–715.
- Bollig KJ, Schust DJ. Refining angular pregnancy diagnosis in the first trimester: a case series of expectant management. *Obstet Gynecol* 2020;**135**:175–184.
- Bottomley C, Van Belle V, Pexsters A, Papageorgiou AT, Mukri F, Kirk E, Van Huffel S, Timmerman D, Bourne T. A model and scoring system to predict outcome of intrauterine pregnancies of uncertain viability. *Ultrasound Obstet Gynecol* 2011;**37**:588–595.

- Brosens JJ, Pijnenborg R, Brosens IA. The myometrial junctional zone spiral arteries in normal and abnormal pregnancies: a review of the literature. *Am J Obstet Gynecol* 2002;**187**:1416–1423.
- Cacciatore B, Stenman UH, Ylostalo P. Comparison of abdominal and vaginal sonography in suspected ectopic pregnancy. *Obstet Gynecol* 1989;**73**:770–774.
- Comstock C, Huston K, Lee W. The ultrasonographic appearance of ovarian ectopic pregnancies. *Obstet Gynecol* 2005;**105**:42–45.
- Condous G, Timmerman D, Goldstein S, Valentin L, Jurkovic D, Bourne T. Pregnancies of unknown location: consensus statement. *Ultrasound Obstet Gynecol* 2006;**28**:121–122.
- Dooley W, De Braud L, Memtsa M, Thanatsis N, Jauniaux E, Jurkovic D. Physical resolution of tubal ectopic pregnancy on ultrasound imaging following successful expectant management. *Reprod Biomed Online* 2020;**40**:880–886.
- Dooley WM, Chaggar P, De Braud LV, Bottomley C, Jauniaux E, Jurkovic D. Effect of morphological type of extrauterine ectopic pregnancy on accuracy of preoperative ultrasound diagnosis. *Ultrasound Obstet Gynecol* 2019;**54**:538–544.
- Doubilet PM, Benson CB, Bourne T, Blaivas M, Barnhart KT, Benacerraf BR, Brown DL, Filly RA, Fox JC, Goldstein SR *et al*. Diagnostic criteria for nonviable pregnancy early in the first trimester. *N Engl J Med* 2013;**369**:1443–1451.
- Elson CJ, SalimRPotdar N, Chetty M, Ross JA, Kirk EJ; on behalf of the Royal College of Obstetricians and Gynaecologists. Diagnosis and Management of Ectopic Pregnancy: Green-top Guideline No. 21. *BJOG* 2016;**123**:e15–e55.
- Fauconnier A, Mabrouk A, Salomon LJ, Bernard JP, Ville Y. Ultrasound assessment of haemoperitoneum in ectopic pregnancy: derivation of a prediction model. *World J Emerg Surg* 2007;**2**:23.
- Ginsburg KA, Quereshi F, Thomas M, Snowman B. Intramural ectopic pregnancy implanting in adenomyosis. *Fertil Steril* 1989;**51**:354–356.
- Harb HM, Knight M, Bottomley C, Overton C, Tobias A, Gallos ID, Shehmar M, Farquharson R, Horne A, Latthe P *et al*. Caesarean scar pregnancy in the UK: a national cohort study. *BJOG* 2018;**125**:1663–1670.
- Jansen RP, Elliott PM. Angular intrauterine pregnancy. *Obstet Gynecol* 1981;**58**:167–175.
- Jayasinghe Y, Rane A, Stalewski H, Grover S. The presentation and early diagnosis of the rudimentary uterine horn. *Obstet Gynecol* 2005;**105**:1456–1467.
- Jurkovic D, Hillaby K, Woelfer B, Lawrence A, Salim R, Elson CJ. First-trimester diagnosis and management of pregnancies implanted into the lower uterine segment Cesarean section scar. *Ultrasound Obstet Gynecol* 2003;**21**:220–227.
- Kayatas S, Demirci O, Kumru P, Mahmutoglu D, Saribrahim B, Arinkan SA. Predictive factors for failure of salpingostomy in ectopic pregnancy. *J Obstet Gynaecol Res* 2014;**40**:453–458.
- Li X, Peng P, Liu X, Chen W, Liu J, Yang J, Bian X. The pregnancy outcomes of patients with rudimentary uterine horn: a 30-year experience. *PLoS One* 2019;**14**:e0210788.
- Liao CY, Tse J, Sung SY, Chen SH, Tsui WH. Cornual wedge resection for interstitial pregnancy and postoperative outcome. *Aust N Z J Obstet Gynaecol* 2017;**57**:342–345.
- Miller R, Timor-Tritsch IE, Gyamfi-Bannerman C; Society for Maternal-Fetal Medicine (SMFM). Electronic address: pubs@smfm.org. Society for Maternal-Fetal Medicine (SMFM) Consult Series #49: Cesarean scar pregnancy. *Am J Obstet Gynecol* 2020;**222**:B2–b14.
- Poole A, Haas D, Magann EF. Early abdominal ectopic pregnancies: a systematic review of the literature. *Gynecol Obstet Invest* 2012;**74**:249–260.
- Rajah K, Goodhart V, Zamora KP, Amin T, Jauniaux E, Jurkovic D. How to measure size of tubal ectopic pregnancy on ultrasound. *Ultrasound Obstet Gynecol* 2018;**52**:103–109.
- Snell RS. The pelvis: Part II. The pelvic cavity. In: BAC Little (ed). *Clinical Anatomy*. Boston: Little, Brown and Co, 1973. p 300
- Tempfer CB, Dogan A, Tischoff I, Hilal Z, Reznicek GA. Chronic ectopic pregnancy: case report and systematic review of the literature. *Arch Gynecol Obstet* 2019;**300**:651–660.
- Tesemma MG. Pregnancy in noncommunicating rudimentary horn of unicornuate uterus: a case report and review of the literature. *Case Rep Obstet Gynecol* 2019;**2019**:1–3.
- Timor-Tritsch IE, Khatib N, Monteagudo A, Ramos J, Berg R, Kovacs S. Cesarean scar pregnancies: experience of 60 cases. *J Ultrasound Med* 2015;**34**:601–610.
- Vial Y, Pétignat P, Hohlfield P. Pregnancy in a cesarean scar. *Ultrasound Obstet Gynecol* 2000;**16**:592–593.
- Votino A, Van den Bosch T, Installe AJ, Van Schoubroeck D, Kaijser J, Kacem Y, De Moor B, Van Pachterbeke C, Timmerman D. Optimizing the ultrasound visualization of the endometrial-myometrial junction (EMJ). *Facts Views Vis ObGyn* 2015;**7**:60–63.
- Zegers-Hochschild F, Adamson GD, Dyer S, Racowsky C, de Mouzon J, Sokol R, Rienzi L, Sunde A, Schmidt L, Cooke ID *et al*. The international glossary on infertility and fertility care, 2017. *Hum Reprod* 2017;**32**:1786–1801.
- Zhang Q, Xing X, Liu S, Xie X, Liu X, Qian F, Liu Y. Intramural ectopic pregnancy following pelvic adhesion: case report and literature review. *Arch Gynecol Obstet* 2019;**300**:1507–1520.