

# Early Corneal Cellular and Nerve Fiber Pathology in Young Patients With Type 1 Diabetes Mellitus Identified Using Corneal Confocal Microscopy

Eszter Szalai,<sup>1</sup> Eszter Deák,<sup>1,2</sup> László Módis Jr,<sup>1</sup> Gábor Németh,<sup>1</sup> András Berta,<sup>1</sup> Annamária Nagy,<sup>1</sup> Enikő Felszeghy,<sup>3</sup> Rita Káposzta,<sup>3</sup> Rayaz A. Malik,<sup>4,5</sup> and Adrienne Csutak<sup>1,6</sup>

<sup>1</sup>Department of Ophthalmology, University of Debrecen, Faculty of Medicine, Debrecen, Hungary

<sup>2</sup>Department of Biochemistry and Molecular Biology, University of Debrecen, Faculty of Medicine, Debrecen, Hungary

<sup>3</sup>Department of Pediatrics, University of Debrecen, Faculty of Medicine, Debrecen, Hungary

<sup>4</sup>Centre for Endocrinology and Diabetes, Institute of Human Development, University of Manchester, Manchester, United Kingdom

<sup>5</sup>Weill-Cornell Medicine-Qatar, Doha, Qatar

<sup>6</sup>3T Research Kft., Debrecen, Hungary

Correspondence: Adrienne Csutak, Department of Ophthalmology, University of Debrecen, Faculty of Medicine, Nagyerdei Boulevard 98, H-4012 Debrecen, Hungary; acsutak@med.unideb.hu.

RAM and AC contributed equally to the work presented here and should therefore be regarded as equivalent authors.

Submitted: November 25, 2015

Accepted: January 25, 2016

Citation: Szalai E, Deák E, Módis L Jr, et al. Early corneal cellular and nerve fiber pathology in young patients with type 1 diabetes mellitus identified using corneal confocal microscopy. *Invest Ophthalmol Vis Sci*. 2016;57:853–858. DOI:10.1167/iivs.15-18735

**PURPOSE.** The aim of this study was to quantify epithelial, stromal, and endothelial cell density, and subbasal nerve morphology in young patients with type 1 diabetes mellitus with and without diabetic retinopathy.

**METHODS.** A total of 28 young patients (mean age,  $22.86 \pm 9.05$  years) with type 1 diabetes, with ( $n = 18$ ) and without ( $n = 10$ ) retinopathy, and 17 age-matched healthy control subjects (mean age,  $26.53 \pm 2.43$  years) underwent corneal confocal microscopy (CCM).

**RESULTS.** We found significantly lower epithelial ( $P < 0.0001$ ) and endothelial ( $P = 0.001$ ) cell densities and higher keratocyte cell density ( $P = 0.024$ ) in patients with type 1 diabetes compared to controls. Significantly lower corneal nerve fiber density ( $P = 0.004$ ), nerve branch density ( $P = 0.004$ ), total nerve branch density ( $P = 0.04$ ), and nerve fiber length ( $P = 0.001$ ), and greater nerve fiber width ( $P = 0.04$ ) were observed in patients with type 1 diabetes compared to control subjects. Significantly lower epithelial ( $P < 0.001$ ) and endothelial ( $P = 0.02$ ) cell densities, nerve branch density ( $P = 0.02$ ), and nerve fiber length ( $P = 0.04$ ), and significantly higher keratocyte cell density ( $P = 0.02$ ) were found in patients with type 1 diabetes without retinopathy compared to control subjects.

**CONCLUSIONS.** Corneal confocal microscopy identifies corneal cellular and small nerve fiber pathology in young patients with type 1 diabetes without retinopathy, which increases in severity in those with retinopathy. Corneal confocal microscopy appears to have considerable use as an imaging biomarker for early subclinical pathology in young patients with type 1 diabetes mellitus.

**Keywords:** diabetic neuropathy, diabetic retinopathy, in vivo confocal microscopy, subbasal corneal nerves, type 1 diabetes mellitus

The triad of retinopathy, nephropathy, and neuropathy are well recognized microvascular complications, and are the leading causes of premature blindness, end-stage renal failure, foot ulceration, and amputation, respectively.<sup>1</sup> Once established, they have a major impact on the quality of life of patients with diabetes and are associated with adverse health-care outcomes.<sup>2</sup> A major challenge is the early identification of these complications to enable risk stratification and risk factor reduction to prevent the development of the end-stage complications.<sup>3</sup>

Diabetic retinopathy (DR) is strongly associated with nephropathy,<sup>4</sup> and is widely considered to be the most common and earliest microvascular complication of diabetes.<sup>5</sup> However, studies have shown that early neuronal abnormalities, such as altered multifocal electroretinogram (mfERG) responses,<sup>6</sup> retinal nerve fiber layer thinning,<sup>7</sup> and loss of central visual field sensitivity,<sup>8</sup> occur before the onset of overt vascular lesions in the retina, and may be of prognostic value.

Recently, corneal nerve morphology assessed by corneal confocal microscopy (CCM) has been proposed as an early surrogate marker for small nerve fiber damage in diabetic neuropathy.<sup>9,10</sup> Corneal nerve fiber length correlates with clinical and electrophysiological measures of diabetic peripheral neuropathy<sup>11,12</sup> and long-term glycemic control.<sup>13,14</sup> Furthermore, recent studies in adults with diabetes have shown a stepwise deterioration in corneal nerve morphology in healthy subjects and patients with preproliferative and proliferative DR.<sup>15,16</sup> Additionally, corneal lesions may develop in patients with diabetes mellitus ranging from nonhealing epithelial erosions to severe corneal ulceration and may be related to underlying structural abnormalities.<sup>17</sup>

The onset and exact temporal relationship between neuropathy and retinopathy remains unclear. We have shown previously that CCM can identify corneal nerve fiber loss in adults with type 1 diabetes without clinical neuropathy<sup>11,18</sup> and, indeed, retinopathy or microalbuminuria.<sup>19</sup> The purpose of this cross-sectional,



**TABLE 1.** Clinical Characteristics and Metabolic Data in Patients With Type 1 Diabetes Mellitus With and Without DR

	Type 1 Diabetes Mellitus Patients		P
	Without DR	With DR	
Duration of DM, y	5.79 ± 2.58	21.56 ± 6.38	<0.0001
HbA <sub>1c</sub> , %	7.91 ± 0.94 (7.39–8.43)	9.38 ± 3.2 (6.70–12.05)	0.11
HbA <sub>1c</sub> , mmol/mol	63.0 ± 10.43 (57.23–68.77)	79.13 ± 34.76 (50.06–108.19)	0.11
Cholesterol, mmol/L	4.02 ± 0.83 (3.55–4.47)	5.56 ± 1.11 (4.18–6.94)	0.004
Triglycerides, mmol/L	0.87 ± 0.23 (0.74–0.99)	4.10 ± 2.83 (0.59–7.61)	0.0002
HDL, mmol/L	1.75 ± 0.27 (1.61–1.90)	0.92 ± 0.51 (0.28–1.56)	0.0001
eGFR, mL/min/1.73 m <sup>2</sup>	> 90 in all patients	69.6 ± 28.27 (45.99–93.26)	0.024
Hypertension	0/18	3/10	0.505
Microalbuminuria	0/18	2/10	0.478

Mean ± SD (95% CI).

observational study was to establish whether corneal cellular and nerve alterations determined using CCM occur in young patients with type 1 diabetes and whether they are associated with the presence and severity of DR.

## MATERIALS AND METHODS

### Study Subjects

We studied 28 individuals (15 males and 13 females; mean age, 22.86 ± 9.05 years) with type 1 diabetes mellitus and 17 age-matched healthy subjects (9 males and 8 females; mean age, 26.53 ± 2.43 years). Control subjects had no past or current history of ocular disease and both groups had no history of contact lens wearing or intraocular surgery. Patients with type 1 diabetes were divided into those without (18 patients; mean age, 16.45 ± 2.59 years) and with (10 patients; mean age, 32.51 ± 5.99 years) retinopathy. Ophthalmologic examination in diabetic patients included slit-lamp examination, dilated fundus photography, IOP measurement, and CCM. The study was performed in accordance with the tenets of the Declaration of Helsinki and we obtained Local Ethical Committee approval at the University of Debrecen. Informed consent was obtained from all subjects. Children (under 18 years of age) were enrolled in the study after obtaining informed consent from their parents or legal guardians.

### Methods

After taking the medical history and visual acuity, CCM was performed in all participants in both eyes using Heidelberg Retina Tomograph III Rostock Cornea Module (HRT III RCM; Heidelberg Engineering GmbH, Heidelberg, Germany). Genteal Gel (0.3% hypromellose; Novartis Ophthalmics, East Hanover, NJ, USA) was applied in a disposable sterile polymethylmethacrylate cap (Tomo-Cap; Heidelberg Engineering GmbH), which was placed on the tip of the objective lens. A drop of local anesthetic (tetracaine hydrochloride 0.4%) was administered to both eyes and the subject was asked to fixate on a distant target before commencing scanning of the central cornea. The procedure took approximately 5 minutes to perform and none of the subjects complained of pain, inconvenience, or visual disturbance. All examinations were performed by a single experienced examiner (ES). Section and volume scans of the central cornea were recorded with the Heidelberg HRT-III microscope, with 384 × 384 pixels and a field of view of 400 × 400 μm<sup>2</sup>. The right eyes of normal controls and diabetic patients without retinopathy were used for analysis. In patients with DR only the eligible eye (no previous intraocular surgery) was used for analysis. Three good quality images (without

motion artifact) of the basal epithelium, posterior stroma, endothelium, and subbasal nerve plexus were selected and used for image analysis by the examiner (ES). The average of three measurements was used for further comparative analysis. Basal epithelium was defined as the first three clear scans anterior to Bowman's layer and the posterior stroma was defined as the first three clear images immediately anterior to Descemet's membrane.<sup>20,21</sup>

For cell counting, the instrument-based software was used which provided semiautomated cell density measurements. On the epithelial, keratocyte, and endothelial cell scan, a region of interest (ROI) was chosen that contained at least 50 cells, then the cells were marked manually and the software automatically calculated cell density (cells/mm<sup>2</sup>). A ROI area was 0.033 ± 0.001 mm<sup>2</sup> for the epithelium, 0.157 ± 0.0005 mm<sup>2</sup> for the stromal layer, and 0.032 ± 0.006 mm<sup>2</sup> for the endothelium. Subbasal nerve plexus morphology was quantified using automated analysis software (ACCMetrics; University of Manchester, Manchester, UK).<sup>22</sup> The following parameters were quantified: nerve fiber density (NFD), the number of nerve fibers/mm<sup>2</sup>; nerve branch density (NBD), the number of primary branch points on the main nerve fibers/mm<sup>2</sup>; nerve fiber length (NFL), the total length of nerves mm/mm<sup>2</sup>; nerve fiber total branch density (TBD), the total number of branch points/mm<sup>2</sup>; nerve fiber area (NFA), the total nerve fiber area mm<sup>2</sup>/mm<sup>2</sup>; and nerve fiber width (NFW), the average nerve fiber width mm/mm<sup>2</sup>.

Dilated fundus investigation was performed in all diabetic patients. The International Clinical Diabetic Retinopathy Disease Severity Scale<sup>23</sup> was applied to classify the stage of DR using fundus photographs: 0 = no retinopathy, 1 = mild nonproliferative DR, 2 = moderate nonproliferative DR, 3 = severe nonproliferative DR, and 4 = proliferative DR.

### Statistical Analysis

Descriptive statistical results were described as mean, standard deviation (SD), and 95% confidence interval (CI). Statistical analysis was performed using MedCalc Version 10.2.0 and SPSS 13.0 for Windows. An ANOVA with post hoc Tukey test was applied for comparison among three groups. For continuous variables, Student's *t*-test was used for comparing two groups; for univariate analysis, the  $\chi^2$  test was used. For bivariate correlation analysis, Pearson correlation test was used. A *P* value ≤0.05 was considered statistically significant.

## RESULTS

Patients' characteristics and clinical data are detailed in Table 1. There was no significant difference in mean age between

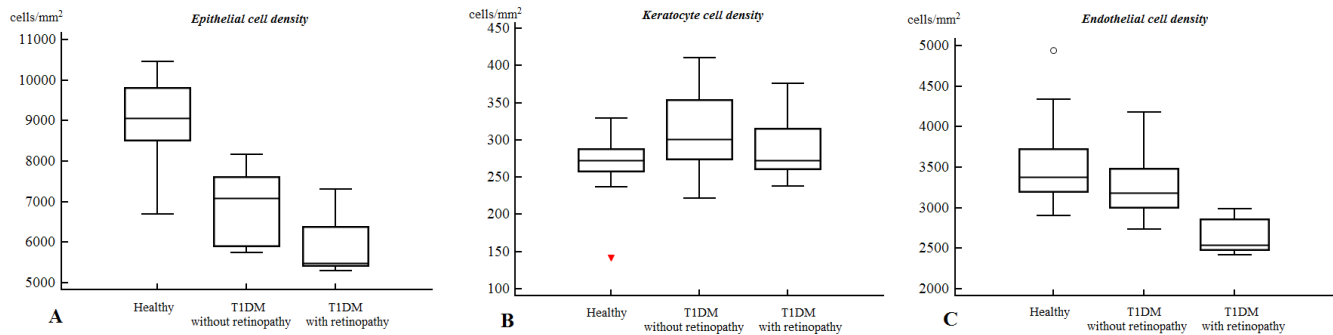


FIGURE 1. Basal epithelial cell count (A), keratocyte density (B), and endothelial cell density (C) measured with in vivo corneal confocal microscopy in control subjects and patients with type 1 diabetes mellitus (T1DM) with and without retinopathy.

patients with type 1 diabetes and controls ( $P = 0.08$ ). Of the patients with type 1 diabetes, 15 had no retinopathy, while 2 had stage 2, 1 stage 3 and 7 stage 4 DR. Among individuals with retinopathy, 9 patients (mean age,  $31.26 \pm 4.52$  years) had undergone panretinal laser photocoagulation (PRP).

**Corneal Cellular Alterations**

Basal epithelial ( $P < 0.0001$ ) and endothelial ( $P = 0.001$ ) cell densities were significantly lower in patients with type 1 diabetes without and with retinopathy compared to control subjects (Fig. 1, Table 2). Keratocyte cell density in the posterior stroma was higher in patients with type 1 diabetes compared to controls ( $P = 0.02$ ). Basal epithelial ( $P < 0.0001$ ) and endothelial ( $P = 0.02$ ) cell density was significantly lower, and keratocyte cell density was greater ( $P = 0.02$ ) in patients with type 1 diabetes without retinopathy compared to control subjects. Epithelial ( $P = 0.04$ ) and endothelial ( $P = 0.004$ ) cell densities were lower in patients with type 1 diabetes with retinopathy compared to patients without retinopathy.

**Corneal Nerve Alterations**

Significantly lower NFD ( $P = 0.004$ ), NBD ( $P = 0.004$ ), NFL ( $P = 0.001$ ), and TBD ( $P = 0.04$ ) values were observed in patients with type 1 diabetes compared to healthy control subjects (Figs. 2, 3; Table 3). There was no significant difference in NFA among the three groups ( $P = 0.144$ ). Nerve fiber width was significantly higher in patients with type 1 diabetes compared to control subjects ( $P = 0.04$ ). Post hoc analysis demonstrated no significant difference in NFD ( $P = 0.256$ ), but a lower NBD ( $P = 0.02$ ), and NFL ( $P = 0.04$ ) in patients with type 1 diabetes without retinopathy compared to control subjects. Nerve fiber density ( $P = 0.003$ ), NBD ( $P = 0.006$ ), NFL ( $P = 0.001$ ), NFW ( $P = 0.03$ ), and TBD ( $P = 0.05$ ) were all significantly lower in

patients with type 1 diabetes with retinopathy compared to control subjects. There was a further significant reduction in NFD ( $P = 0.03$ ) in diabetes patients with compared to patients without retinopathy.

There was a significant inverse correlation between NFD ( $r = -0.428$ ,  $P = 0.029$ ) and NFL ( $r = -0.387$ ,  $P = 0.046$ ) with the stage of retinopathy. The serum cholesterol level in patients with type 1 diabetes correlated inversely with NFL ( $r = -0.511$ ,  $P = 0.025$ ) and NFW ( $r = -0.450$ ,  $P = 0.047$ ). There was no significant correlation between the duration of diabetes, hemoglobin A<sub>1c</sub> (HbA<sub>1c</sub>), serum triglycerides, high density lipoprotein (HDL), and estimated glomerular filtration rate (eGFR) with any of the morphologic parameters ( $P > 0.05$ ).

**DISCUSSION**

The human cornea contains sensory nerve fibers originated from the trigeminal nerve and sympathetic axons from the superior cervical ganglion. Stromal nerve bundles enter the cornea at its periphery and before penetrating Bowman's membrane, they compose the subepithelial plexus.<sup>24</sup> After dividing into several smaller branches, subbasal plexus nerves innervate the corneal epithelium and form nerve terminals with a considerably higher density in the central cornea than in the periphery.<sup>24,25</sup> Corneal nerves have a pivotal role in maintaining the functional and morphologic integrity of the ocular surface<sup>26</sup> and serve protective and trophic functions. In vivo corneal confocal microscopy has been used as a rapid, noninvasive ophthalmic imaging technique to quantify the cornea at the cellular level in several different pathologies.<sup>27,28</sup> It has been applied widely in adults with diabetes and, indeed, it has been shown to detect subclinical neuropathy,<sup>11,18</sup> stratify the severity of neuropathy,<sup>29</sup> predict the development of clinical neuropathy,<sup>30,31</sup> and nerve repair after therapy.<sup>32</sup> We

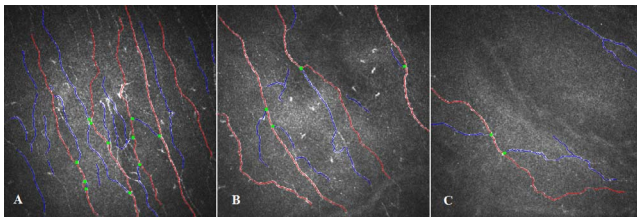
TABLE 2. Corneal Microstructural Alterations in Healthy Subjects Compared to Patients With Type 1 Diabetes Mellitus With and Without DR

	Healthy Subjects	Type 1 Diabetes Mellitus Patients				
		Without DR	P†	With DR	P†	P*
Epithelial cell density, cells/mm <sup>2</sup>	9024.76 ± 962.83 (8529.72-9519.8)	6942.73 ± 881.04 (6504.6-7380.86)	<0.0001	5923.14 ± 739.88 (5238.87-6607.42)	0.04	<0.0001
Keratocyte cell density, cells/mm <sup>2</sup>	268.84 ± 40.09 (248.23-289.45)	314.11 ± 52.98 (287.76-340.46)	0.02	289.13 ± 44.85 (251.63-326.62)	0.258	0.024
Endothelial cell density, cells/mm <sup>2</sup>	3497.62 ± 519.84 (3230.34-3764.9)	3250.36 ± 421.49 (3007.0-3493.72)	0.02	2639.17 ± 227.49 (2400.44-2877.9)	0.004	0.001

Mean ± SD (95% CI).

\* ANOVA among the three groups.

† Post hoc analysis comparing healthy subjects to type 1 diabetes patients without DR and type 1 diabetes patients without DR to patients with DR.



**FIGURE 2.** Annotated image of the subbasal nerve plexus using ACCMetrics software (*red*, fiber; *blue*, branch; *green*, branch point). (A) normal nerve fiber morphology of a healthy individual. (B) Decreased nerve fiber density and altered morphology of a patient with type 1 diabetes mellitus for 10 years without retinopathy (HbA<sub>1c</sub>, 9.8%, 84 mmol/mol). (C) Subbasal nerve damage in a patient with type 1 diabetes mellitus for 27 years and Grade 4 retinopathy (HbA<sub>1c</sub>, 8.7%, 72 mmol/mol).

also have previously shown that corneal nerve abnormalities occur in patients with type 1<sup>19</sup> and type 2<sup>17</sup> diabetes without retinopathy and, therefore, may be the earliest of the microvascular complications.

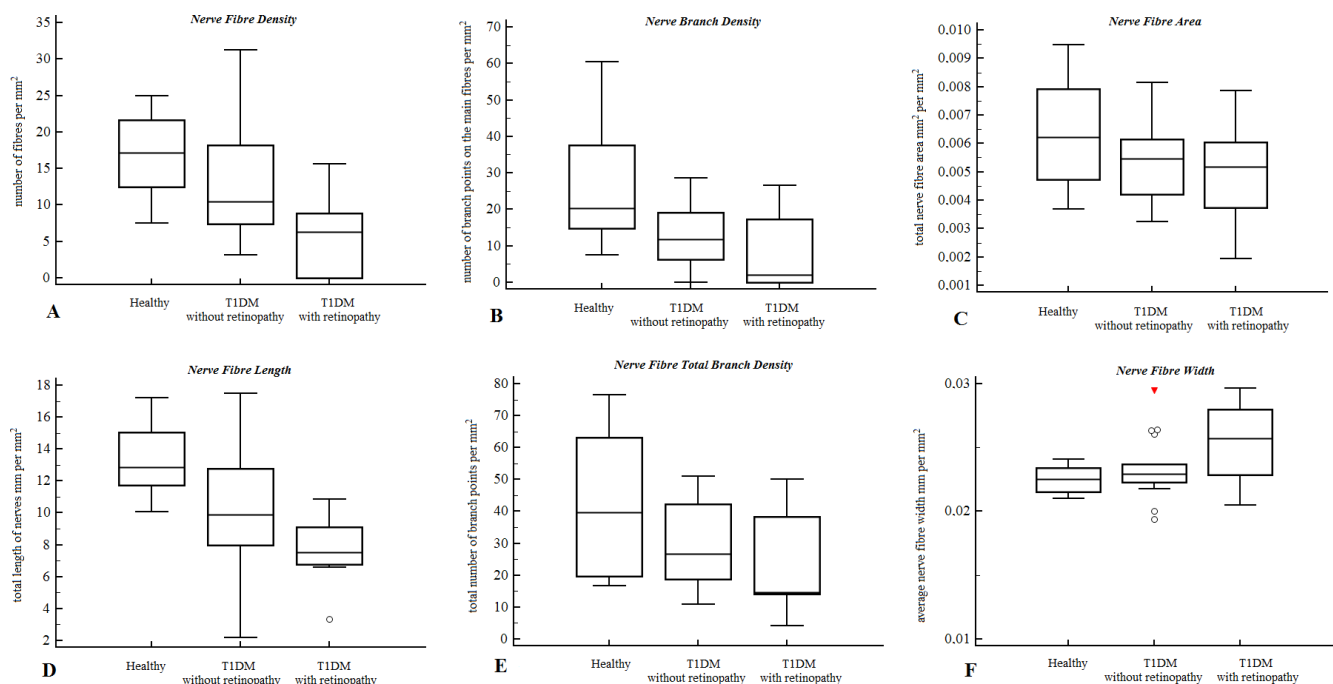
Studies in children and adolescents are limited, but we recently have shown good reproducibility and usability of CCM in young children with type 1 diabetes mellitus.<sup>33</sup> Also in a small pilot study of children with types 1 and 2 diabetes, we previously showed no change in corneal nerve morphology using corneal confocal microscopy.<sup>34</sup> A recent study using OCT in children with type 1 diabetes also has shown no differences in the nerve fiber layer and ganglion cell layer.<sup>35</sup> Quantitative sensory tests, such as vibration perception thresholds and tactile perception thresholds, are inadequate for screening early diabetic neuropathy in pediatric populations.<sup>36,37</sup>

Given that we and others have shown previously abnormal corneal nerve morphology in adult diabetic patients without or with minimal neuropathy,<sup>11,29,30</sup> we have undertaken CCM in young patients with type 1 diabetes. We demonstrate

widespread corneal microstructural alterations in these patients with type 1 diabetes without DR, which are worse in those with retinopathy. Decreased basal epithelial and endothelial cell density was observed and is similar to findings in adults<sup>17,38</sup> and children<sup>39</sup> with diabetes. In our study, keratocyte cell density in the posterior stroma was higher in young patients with type 1 diabetes compared to controls. This is in contrast with our previous study showing no significant difference in posterior keratocyte cell density between healthy subjects and adults with type 2 diabetes.<sup>40</sup> The mechanism for increased keratocyte density in these young patients with type 1 diabetes is unclear but a number of growth factors, including fibroblast growth factor-2, insulin, and platelet-derived growth factor-BB, have been shown to induce keratocyte proliferation.<sup>41</sup> Additionally, a number of signal transduction pathways are activated when diabetic keratocytes are cultured in IL-1 $\alpha$  or TNF- $\alpha$ , which may impact on cell proliferation and, hence, density.<sup>42</sup>

We also demonstrated in particular lower corneal nerve branch density and length, in young diabetic patients without retinopathy or microalbuminuria, confirming previous studies in adults with type 1 and type 2 diabetes.<sup>17,19</sup> Furthermore, automated analysis has enabled us to identify lower total branch density, confirming early more distal loss of nerve branches with greater NFW, consistent with this loss of thinner more distal branches. Interestingly, total nerve fiber area was comparable between control subjects and diabetic patients, presumably due to the early relative preservation of main nerve fibers with a primary reduction in nerve branches. In the present study, there was a significant association between the corneal nerve alterations and the presence and severity of retinopathy, confirming previous studies.<sup>17,19,43</sup>

A limitation of this study is that we did not screen participants for other causes of neuropathy. Therefore, it is possible, although unlikely in this young population, that some participants may have had a neuropathy from a cause other than diabetes, potentially confounding our data.



**FIGURE 3.** Nerve fiber density (A), NBD (B), NFA (C), NFL (D), TBD (E), NFW (F) in control subjects and patients with type 1 diabetes mellitus (T1DM) with and without retinopathy.



TABLE 3. Subbasal Nerve Plexus Morphology in Healthy Subjects Compared to Patients With Type 1 Diabetes Mellitus With and Without DR

	Healthy Subjects (n = 17)	Type 1 Diabetes Mellitus Patients				
		Without DR (n = 18)	P†	With DR (n = 10)	P†	P*
Nerve fiber density, No./mm <sup>2</sup>	16.92 ± 5.61 (13.15-20.69)	12.79 ± 7.72 (8.82-16.76)	0.256	6.13 ± 5.37 (2.00-10.26)	0.003	0.004
Nerve branch density, No./mm <sup>2</sup>	27.24 ± 17.82 (15.27-39.22)	13.04 ± 7.59 (8.99-17.09)	0.02	8.74 ± 11.00 (0.28-17.19)	0.682	0.004
Nerve fiber length, mm/mm <sup>2</sup>	13.30 ± 2.27 (11.78-14.83)	10.28 ± 3.85 (8.36-12.19)	0.04	7.65 ± 2.13 (6.01-9.28)	0.112	0.001
Nerve fiber total branch density, No./mm <sup>2</sup>	43.04 ± 22.11 (28.19-57.89)	28.80 ± 13.74 (21.96-35.63)	0.086	24.42 ± 15.72 (12.34-36.50)	0.804	0.04
Nerve fiber area, mm <sup>2</sup> /mm <sup>2</sup>	0.0064 ± 0.0021 (0.0045-0.0082)	0.0054 ± 0.0013 (0.0045-0.0061)	0.272	0.0049 ± 0.0017 (0.0036-0.0063)	0.801	0.144
Nerve fiber width, mm/mm <sup>2</sup>	0.0224 ± 0.0011 (0.0215-0.0236)	0.0234 ± 0.0024 (0.0223-0.0247)	0.564	0.0252 ± 0.0033 (0.0210-0.0282)	0.147	0.04

Mean ± SD (95% CI).

\* ANOVA among the three groups.

† Post hoc analysis comparing healthy subjects to type 1 diabetes patients without DR and type 1 diabetes patients without DR to patients with DR.

In conclusion, in vivo CCM appears to be a valuable, noninvasive ophthalmic imaging tool for identifying early corneal cellular and nerve fiber pathology in young patients with type 1 diabetes mellitus, before the development of DR. This adds to the weight of evidence suggesting that CCM has considerable potential in identifying early subclinical pathology in patients with type 1 diabetes.

### Acknowledgments

Supported in part by the project TAMOP-4.2.2.A-11/1 KONYV-2012-0045 by the European Union, co-financed by the European Social Fund, and by a Bolyai Grant (AC).

Disclosure: E. Szalai, None; E. Deák, None; L. Módis Jr, None; G. Németh, None; A. Berta, None; A. Nagy, None; E. Felszeghy, None; R. Káposzta, None; R.A. Malik, None; A. Csutak, None

### References

- Gubitosi-Klug RA. The diabetes control and complications trial/epidemiology of diabetes interventions and complications study at 30 years: summary and future directions. *Diabetes Care*. 2014;37:44-49.
- Candrilli SD, Davis KL, Kan HJ, et al. Prevalence and the associated burden of illness of symptoms of diabetic peripheral neuropathy and diabetic retinopathy. *J Diabetes Complications*. 2007;21:306-314.
- Broe R. Early risk stratification in pediatric type 1 diabetes. *Acta Ophthalmol*. 2015;93(thesis):1-19.
- Grunwald J, Alexander J, Ying G, et al. Retinopathy and chronic kidney disease in the Chronic Renal Insufficiency Cohort (CRIC) Study. *Arch Ophthalmol*. 2012;130:1136-1144.
- Lövestam-Adrian M, Agardh E, Agardh C. The temporal development of retinopathy and nephropathy in type 1 diabetes mellitus during 15 years diabetes duration. *Diabetes Res Clin Pract*. 1999;45:15-23.
- Adams AJ, Bearse MA Jr. Retinal neuropathy precedes vasculopathy in diabetes: a function-based opportunity for early treatment intervention? *Clin Exp Optom*. 2012;95:256-265.
- Shahidi AM, Sampson GP, Pritchard N, et al. Retinal nerve fibre layer thinning associated with diabetic peripheral neuropathy. *Diabetic Med*. 2012;29:e106-e111.
- Sampson G, Shahidi A, Vagenas D, et al. Visual sensitivity loss in the central 30° of visual field is associated with diabetic peripheral neuropathy. *Diabetologia*. 2012;55:1179-1185.
- Tavakoli M, Quattrini C, Abbott C, et al. Corneal confocal microscopy: a novel noninvasive test to diagnose and stratify the severity of human diabetic neuropathy. *Diabetes Care*. 2010;33:1792-1797.
- Malik RA, Kallinikos P, Abbott C, et al. Corneal confocal microscopy: a non-invasive surrogate of nerve fibre damage and repair in diabetic patients. *Diabetologia*. 2003;46:683-688.
- Quattrini C, Tavakoli M, Jeziorska M, et al. Surrogate markers of small fiber damage in human diabetic neuropathy. *Diabetes*. 2007;56:2148-2154.
- Ahmed A, Bril V, Orszag A, et al. Detection of diabetic sensorimotor polyneuropathy by corneal confocal microscopy in type 1 diabetes: a concurrent validity study. *Diabetes Care*. 2012;35:821-828.
- Ishibashi F, Okino M, Ishibashi M, et al. Corneal nerve fiber pathology in Japanese type 1 diabetic patients and its correlation with antecedent glycemic control and blood pressure. *J Diabetes Investig*. 2011;3:191-198.
- Wu T, Ahmed A, Bril V, et al. Variables associated with corneal confocal microscopy parameters in healthy volunteers: implications for diabetic neuropathy screening. *Diabet Med*. 2012;29:e297-e303.
- Nitoda E, Kallinikos P, Pallikaris A, et al. Correlation of diabetic retinopathy and corneal neuropathy using confocal microscopy. *Curr Eye Res*. 2012;37:898-906.
- Zhivov A, Winter K, Hovakimyan M, et al. Imaging and quantification of subbasal nerve plexus in healthy volunteers and diabetic patients with or without retinopathy. *PLoS One*. 2013;8:e52157.
- Bitirgen G, Ozkagnici A, Malik RA, Kerimoglu H. Corneal nerve fibre damage precedes diabetic retinopathy in patients with type 2 diabetes mellitus. *Diabet Med*. 2014;31:431-438.
- Malik RA, Kallinikos P, Abbott CA, et al. Corneal confocal microscopy: a non-invasive surrogate of nerve fibre damage and repair in diabetic patients. *Diabetologia*. 2003;46:683-688.
- Petropoulos IN, Green P, Chan AW, et al. Corneal confocal microscopy detects neuropathy in patients with type 1 diabetes without retinopathy or microalbuminuria. *PLoS One*. 2015;10:e0123517.

20. Niederer RL, Perumal D, Sherwin T, McGhee CN. Laser scanning in vivo confocal microscopy reveals reduced innervation and reduction in cell density in all layers of the keratoconic cornea. *Invest Ophthalmol Vis Sci.* 2008;49:2964-2970.
21. Erie JC, Patel SV, McLaren JW, Nau CB, Hodge DO, Bourne WM. Keratocyte density in keratoconus. A confocal microscopy study(a). *Am J Ophthalmol.* 2002;134:689-695.
22. Dabbah MA, Graham J, Petropoulos IN, Tavakoli M, Malik RA. Automatic analysis of diabetic peripheral neuropathy using multi-scale quantitative morphology of nerve fibres in corneal confocal microscopy imaging. *Med Image Anal.* 2011;15:738-747.
23. Wilkinson CP, Ferris FL III, Klein RE, et al. Proposed international clinical diabetic retinopathy and diabetic macular edema disease severity scales. *Ophthalmology.* 2003;110:1677-1682.
24. Marfurt CF, Cox J, Deek S, Dvorscak L. Anatomy of the human corneal innervation. *Exp Eye Res.* 2010;90:478-492.
25. He J, Bazan NG, Bazan HE. Mapping the entire human corneal nerve architecture. *Exp Eye Res.* 2010;91:513-523.
26. Muller IJ, Marfurt CF, Kruse F, Tervo TM. Corneal nerves: structure, contents and function. *Exp Eye Res.* 2003;76:521-542.
27. Bitirgen G, Ozkagnici A, Malik RA, Oltulu R. Evaluation of contact lens-induced changes in keratoconic corneas using in vivo confocal microscopy. *Invest Ophthalmol Vis Sci.* 2013;54:5385-5391.
28. Bitirgen G, Ozkagnici A, Bozkurt B, Malik RA. In vivo corneal confocal microscopic analysis in patients with keratoconus. *Int J Ophthalmol.* 2015;8:534-539.
29. Petropoulos IN, Alam U, Fadavi H, et al. Corneal nerve loss detected with corneal confocal microscopy is symmetrical and related to the severity of diabetic polyneuropathy. *Diabetes Care.* 2013;36:3646-3651.
30. Pritchard N, Edwards K, Russell AW, Perkins BA, Malik RA, Efron N. Corneal confocal microscopy predicts 4-year incident peripheral neuropathy in type 1 diabetes. *Diabetes Care.* 2015;38:671-675.
31. Lovblom LE, Halpern EM, Wu T, et al. In vivo corneal confocal microscopy and prediction of future incident neuropathy in type 1 diabetes: a preliminary longitudinal analysis. *Can J Diabetes.* 2015;39:390-397.
32. Tavakoli M, Mitu-Pretorian M, Petropoulos IN, et al. Corneal confocal microscopy detects early nerve regeneration in diabetic neuropathy after simultaneous pancreas and kidney transplantation. *Diabetes.* 2013;62:254-260.
33. Pacaud D, Romanchuk KG, Tavakoli M, et al. The reliability and reproducibility of corneal confocal microscopy in children. *Invest Ophthalmol Vis Sci.* 2015;56:5636-5640.
34. Sellers EA, Clark I, Tavakoli M, Dean HJ, McGavock J, Malik RA. The acceptability and feasibility of corneal confocal microscopy to detect early diabetic neuropathy in children: a pilot study. *Diabet Med.* 2013;30:630-631.
35. Elhabashy SA, Elbarbary NS, Nageb KM, Mohammed MM. Can optical coherence tomography predict early retinal microvascular pathology in type 1 diabetic adolescents without minimal diabetic retinopathy? A single-centre study. *J Pediatr Endocrinol Metab.* 2015;28:139-146.
36. Hirschfeld G, von Glischinski M, Knop C, et al. Difficulties in screening for peripheral neuropathies in children with diabetes. *Diabet Med.* 2015;32:786-789.
37. Nelson D, Mah JK, Adams C, et al. Comparison of conventional and non-invasive techniques for the early identification of diabetic neuropathy in children and adolescents with type 1 diabetes. *Pediatr Diabetes.* 2006;7:305-310.
38. Quadrado MJ, Popper M, Morgado AM, Murta JN, Van Best JA. Diabetes and corneal cell densities in humans by in vivo confocal microscopy. *Cornea.* 2006;25:761-768.
39. Urban B, Raczynska D, Bakunowicz-Lazarczyk A, Raczynska K, Kretowska M. Evaluation of corneal endothelium in children and adolescents with type 1 diabetes mellitus. *Mediators Inflamm.* 2013;2013:913754.
40. Bitirgen G, Ozkagnici A, Malik RA, Kerimoglu H. Corneal nerve fibre damage precedes diabetic retinopathy in patients with type 2 diabetes mellitus. *Diabet Med.* 2014;31:431-438.
41. Musselmann K, Alexandrou B, Kane B, Hassell JR. Maintenance of the keratocyte phenotype during cell proliferation stimulated by insulin. *J Biol Chem.* 2005;280:32634-32639.
42. Lee JE, Lee JS, Hwang SH. Microarray for genes associated with signal transduction in diabetic OLET keratocytes. *Korean J Ophthalmol.* 2007;21:111-119.
43. Nitoda E, Kallinikos P, Pallikaris A, et al. Correlation of diabetic retinopathy and corneal neuropathy using confocal microscopy. *Curr Eye Res.* 2012;37:898-906.