



Non-lupus full-house nephropathy—immune dysregulation as a rare cause of pediatric nephrotic syndrome: Answers

Orsolya Horváth^{1,2} · György S. Reusz¹ · Veronika Goda² · Kata Kelen¹ · István Balogh³ · Magdolna Kardos⁴ · Krisztián Kállay² · Áron Cseh¹ · Attila J. Szabó¹ · Gergely Kriván²

Received: 6 November 2021 / Accepted: 8 November 2021
© The Author(s) 2021

Keywords “Full-house” nephropathy (FHN) · Autoimmunity · Primary immunodeficiency (PID) · IPEX syndrome · *FOXP3* mutation

The proof contains only the Answers part of the Clinical Quiz. Will the Questions part arrive in an another form? Answers

1. What is the most likely diagnosis?

Based on the synchronicity of severe infections, multiple autoimmune disorders, atopic dermatitis, chronic diarrhoea and insufficient weight gain, the “immunodysregulation, polyendocrinopathy, enteropathy, X-linked” (IPEX) or IPEX-like syndrome was first suspected at the age of 8 in 2015, and calcineurin inhibitor tacrolimus was introduced [1].

IPEX syndrome is a rare primary immunodeficiency syndrome characterized by the development of multiple autoimmune disorders. IPEX is caused by mutations in the forkhead box protein 3 gene (*FOXP3*), which encodes a key transcription factor required for regulatory T cell (Treg) development, maintenance and function [2]. In addition to the traditional clinical presentation (severe enteropathy,

type 1 diabetes and skin lesions), IPEX may include other variable and distinct clinical manifestations [3]. The coding region of *FOXP3* was analysed by Sanger sequencing and a silent mutation was detected (c.816G > A). To assess the potential effect of the mutation on RNA splicing, RNA of peripheral white blood cells was tested and the skipping of exon 7 was observed; thus, the effect of the mutation was p.Leu246fs*160 [4].

Treg cell dysfunction is the main pathogenic event leading to multiorgan autoimmunity in IPEX [3]. Functional data demonstrate that Treg cells isolated from IPEX patients are dysfunctional, as they cannot inhibit proliferation and cytokine production of autologous or allogenic T effector cells [3].

Our patient had typical (enteropathy, skin lesions, severe infections) and atypical (non-lupus full-house nephropathy) symptoms without type 1 diabetes leading to the diagnosis of IPEX. Treg cell count was at the lower limit of normal range (CD3+/CD4+ T cell count 503 cell/μL (lower limit of normal 300 cell/μL), 4.6% Treg cells of the CD3+/CD4+ cells (normal range 4–9%). Treg cell subpopulations and intracellular cytokine production were not evaluated and functional T cell tests were not available at the time of diagnosis.

2. What is the possible underlying mechanism of kidney involvement?

Non-lupus full-house nephropathy (FHN) was the most remarkable and rare symptom of the multiple autoimmune disorder. FHN is a rare kidney disease characterized by a variety of glomerular lesions typically accompanied by extensive deposition of all classes of immunoglobulins and complement components along different sites of the

This refers to the article that can be found at <http://dx.doi.org/10.1007/s00467-021-05359-3>

✉ György S. Reusz
reusz.gyorgy@med.semmelweis-univ.hu

¹ 1St Department of Pediatrics, Semmelweis University, 53-54 Bóky János Street, Budapest 1083, Hungary

² Pediatric Hematology and Stem Cell Transplantation Unit, Central Hospital of Southern Pest, National Institute of Hematology and Infectious Diseases, Budapest, Hungary

³ Department of Laboratory Medicine, Division of Clinical Genetics, Department of Human Genetics, Faculty of Medicine, University of Debrecen, Debrecen, Hungary

⁴ 2Nd Department of Pathology, Semmelweis University, Budapest, Hungary

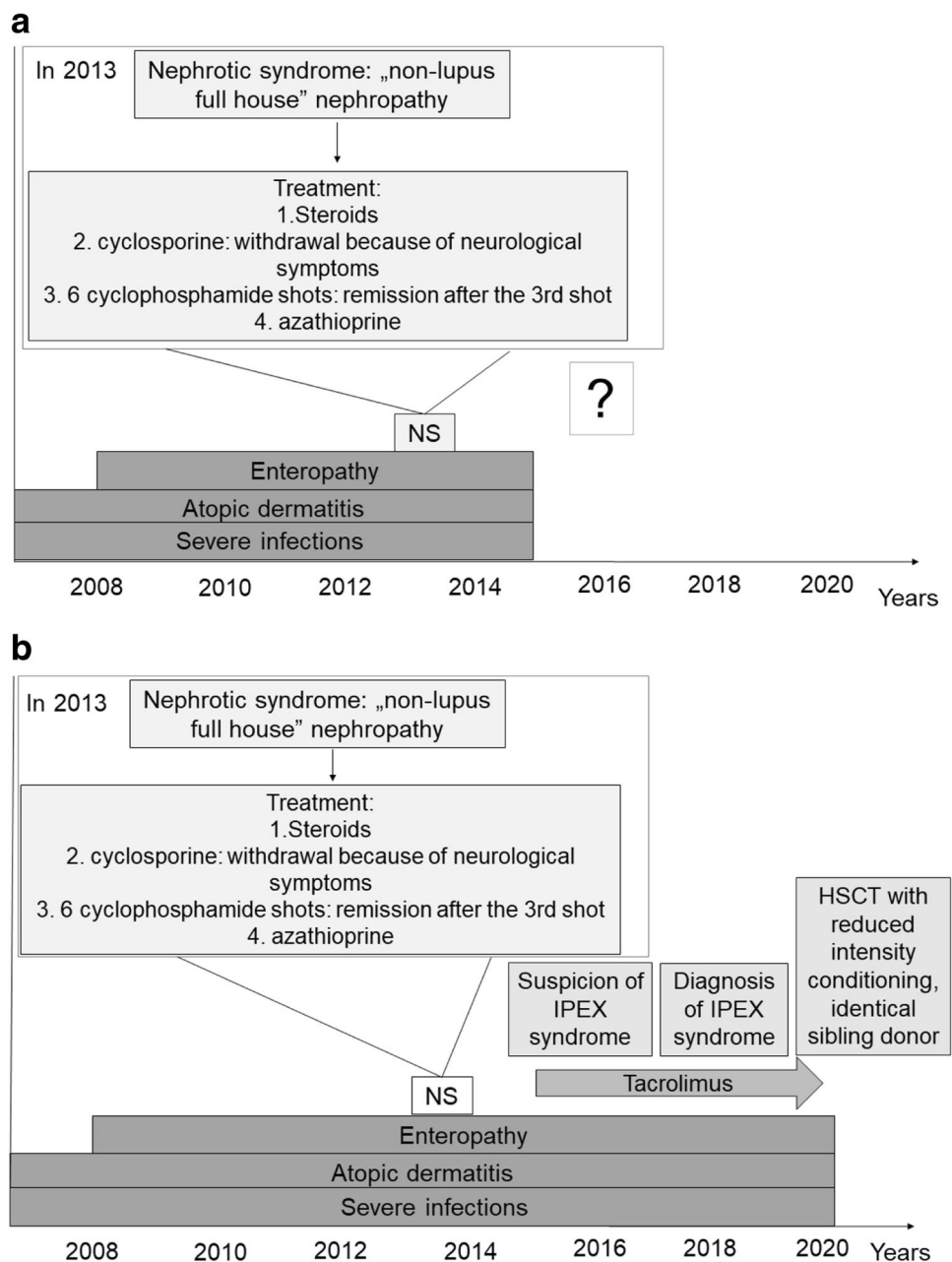
glomerulus [5]. Different forms of kidney injury have been reported in IPEX syndrome, such as membranous nephropathy and minimal change nephrotic syndrome [6–8]. B cells in IPEX show altered antibody production, and tissue-specific autoantibodies can be detected early [9]. Anti-villin and harmonin autoantibodies are highly expressed in proximal tubules, which can also explain the wide range of kidney involvement in IPEX syndrome [9]. Furthermore, in our patient’s case, it is not clear whether non-lupus FHN was part of the clinical spectrum as a result of immune dysregulation, or was secondary to medications, infections or other concomitant insults. In this case, non-lupus FHN was treated as lupus nephritis and went into remission after the third

cyclophosphamide pulse and remained in remission during azathioprine and later tacrolimus treatment. Similar to our results, high complete response rate was found in pediatric patients with non-lupus FHN [10].

3. What is the treatment and the prognosis of the disease?

Currently, the therapeutic approach to IPEX syndrome is not standardized; patient management is based on single-centre experiences. Immunosuppressive treatment (IST) is the treatment of choice; however, its role in controlling dysfunctional Treg cells is not clear [1]. Disease manifestations improve in

Fig. 1 **a** Patient flow chart for the Questions part. NS indicates nephrotic syndrome. **b** Patient flow chart for the Answers part. HSCT indicates hematopoietic stem cell transplantation; IPEX, immunodysregulation, poly-endocrinopathy, enteropathy, X-linked (IPEX) syndrome; NS, nephrotic syndrome. Tacrolimus was started as immunosuppressive therapy after the suspicion for IPEX syndrome and continued as graft-versus-host disease prophylaxis for 110 days after HSCT



half of the cases treated with IST alone [11]. Based on clinical signs and the results of flow cytometry, our patient was treated for IPEX-like syndrome after 2015 (Fig. 1). IST with steroids, cyclophosphamide, azathioprine and finally tacrolimus resulted in only partial control of the disease. The main reason for hematopoietic stem cell transplantation (HSCT) was uncontrolled autoimmune enteropathy, failure to thrive (body mass index (BMI) z-score -1.5), persisting skin symptoms and poor quality of life. HSCT is currently the only curative therapy for IPEX syndrome and can result in favourable outcome with improved quality of life [1, 11, 12]. In the present case, considering the non-malignant indication, reduced intensity HSCT conditioning regimen was used. Treatment-related toxicity was well tolerated and oral nutrition could be started. HSCT was performed with an identical female sibling donor and tacrolimus as graft-versus-host disease prophylaxis could be discontinued early, 4 months after HSCT.

Patient outcome

One year after HSCT, at the age of 14, the patient lives without IST, has normal kidney function and blood pressure, no haematuria and proteinuria below $15 \text{ mg/m}^2/\text{h}$. The patient tolerates normal enteral nutrition well, and moreover gained weight and height (BMI z-score 0.03) as well.

Conclusion

In conclusion, severe immune dysregulation in IPEX syndrome can be an underlying cause in the pathomechanism of non-lupus full-house nephropathy, a rare cause of nephrotic syndrome in childhood. With combined IST, long-term remission of NS was achieved, HSCT was necessary to control the severe extrarenal clinical symptoms. In such cases of FHN, patients should be screened for primary immunodeficiency.

Funding Open access funding provided by Semmelweis University. The study was supported by the Hungarian National Research, Development, and Innovation Office grant NKFI-124549 (RGS). At the online publishing platform NKFI was marked incorrectly as National Kidney Foundation of Iowa, by mistake. This manuscript contains funding information correctly.

Availability of data and material Not applicable.

Code availability Not applicable.

Declarations

Conflict of interest The authors declare no competing interests.

Open Access This article is licensed under a Creative Commons Attribution 4.0 International License, which permits use, sharing, adaptation, distribution and reproduction in any medium or format, as long as you give appropriate credit to the original author(s) and the source, provide a link to the Creative Commons licence, and indicate if changes were made. The images or other third party material in this article are included in the article's Creative Commons licence, unless indicated otherwise in a credit line to the material. If material is not included in the article's Creative Commons licence and your intended use is not permitted by statutory regulation or exceeds the permitted use, you will need to obtain permission directly from the copyright holder. To view a copy of this licence, visit <http://creativecommons.org/licenses/by/4.0/>.

References

1. Ben-Skowronek I (2021) IPEX syndrome: genetics and treatment options. *Genes* 12:323. <https://doi.org/10.3390/genes12030323>
2. Katoh H, Zheng P, Liu Y (2013) FOXP3: genetic and epigenetic implications for autoimmunity. *J Autoimmun* 41:72–78. <https://doi.org/10.1016/j.jaut.2012.12.004>
3. Bacchetta R, Barzaghi F, Roncarolo MG (2016) From IPEX syndrome to FOXP3 mutation: a lesson on immune dysregulation. *Ann N Y Acad Sci* 1417:5–22. <https://doi.org/10.1111/nyas.13011>
4. Magg T, Mannert J, Ellwart JW, Schmid I, Albert MH (2012) Subcellular localization of FOXP3 in human regulatory and non-regulatory T cells. *Eur J Immunol* 42:1627–1638. <https://doi.org/10.1002/eji.201141838>
5. Gianviti A, Barsotti P, Barbera V, Faraggiana T, Rizzoni G (1999) Delayed onset of systemic lupus erythematosus in patients with “full-house” nephropathy. *Pediatr Nephrol* 13:683–687. <https://doi.org/10.1007/s004670050681>
6. Chuva T, Pfister F, Beringer O, Felgentreff K, Büttner-Herold M, Amann K (2017) PLA2R-positive (primary) membranous nephropathy in a child with IPEX syndrome. *Pediatr Nephrol* 32:1621–1624. <https://doi.org/10.1007/s00467-017-3682-8>
7. Hashimura Y, Nozu K, Kanegane H, Miyawaki T, Hayakawa A, Yoshikawa N, Nakanishi K, Takemoto M, Iijima K, Matsuo M (2009) Minimal change nephrotic syndrome associated with immune dysregulation, polyendocrinopathy, enteropathy, X-linked syndrome. *Pediatr Nephrol* 24:1181–1186. <https://doi.org/10.1007/s00467-009-1119-8>
8. Moudgil A, Perriello P, Loechelt B, Przygodzki R, Fitzgerald W, Kamani N (2007) Immunodysregulation, polyendocrinopathy, enteropathy, X-linked (IPEX) syndrome: an unusual cause of proteinuria in infancy. *Pediatr Nephrol* 22:1799–1802. <https://doi.org/10.1007/s00467-007-0532-0>
9. Tsuji S, Kimata T, Yamanouchi S, Kitao T, Kino J, Suruda C, Kaneko K (2017) Regulatory T cells and CTLA-4 in idiopathic nephrotic syndrome. *Pediatr Int* 59:643–646. <https://doi.org/10.1111/ped.13255>
10. Ruggiero B, Vivarelli M, Gianviti A, Pecoraro C, Peruzzi L, Benetti E, Ventura G, Pennesi M, Murer L, Coppo R, Emma F (2017) Outcome of childhood-onset full-house nephropathy. *Nephrol Dial Transplant* 32:1194–1204. <https://doi.org/10.1093/ndt/gfw230>
11. Barzaghi F, Amaya Hernandez LC, Neven B, Ricci S, Kucuk ZY, Bleesing JJ, Nademi Z, Slatte MA, Ulloa ER, Shcherbina A, Ropelt A, Worth A, Silva J, Aiuti A, Murguía-Favela L, Speckmann C, Carneiro-Sampaio M, Fernandes JF, Baris S, Ozen A, Karakoc-Aydiner E, Kiykim A, Schulz A, Steinmann S, Notarangelo LD, Gambineri E, Lionetti P, Shearer WT, Forbes LR, Martinez C, Moshous D, Blanche S, Fisher A, Ruemmele FM, Tissandier C, Ouachee-Charadin M, Rieux-Laucat F, Cavazzana M, Qasim W, Lucarelli B, Albert MH, Kobayashi I, Alonso L, Diaz De Heredia C, Kanegane H, Lawitschka A, Seo JJ, Gonzalez-Vicent M,

Diaz MA, Goyal RK, Sauer MG, Yesilipek A, Kim M, Yilmaz-Demirdag Y, Bhatia M, Khlevner J, Richmond Padilla EJ, Martino S, Montin D, Neth O, Molinos-Quintana A, Valverde-Fernandez J, Broides A, Pinsk V, Ballauf A, Haerynck F, Bordon V, Dhooge C, Garcia-Lloret ML, Bredius RG, Kafwak K, Haddad E, Seidel MG, Duckers G, Pai SY, Dvorak CC, Ehl S, Locatelli F, Goldman F, Gennery AR, Cowan MJ, Roncarolo MG, Bacchetta R, Primary Immune Deficiency Treatment Consortium (PIDTC) and the Inborn Errors Working Party (IEWP) of the European Society for Blood and Marrow Transplantation (EBMT) (2018) Long-term follow-up of IPEX syndrome patients after different therapeutic strategies: an international multicenter retrospective study. *J Allergy Clin Immunol* 141:1036-1049.e5. <https://doi.org/10.1016/j.jaci.2017.10.041>

12. Jamee M, Zaki-Dizaji M, Lo B, Abolhassani H, Aghamahdi F, Mosavian M, Nademi Z, Mohammadi H, Jadidi-Niaragh F, Rojas M, Anaya JM, Azizi G (2020) Clinical, immunological, and genetic features in patients with immune dysregulation, polyendocrinopathy, enteropathy, X-linked (IPEX) and IPEX-like syndrome. *J Allergy Clin Immunol Pract* 8:2747-2760.e7. <https://doi.org/10.1016/j.jaip.2020.04.070>

Publisher's note Springer Nature remains neutral with regard to jurisdictional claims in published maps and institutional affiliations.